

Topical review

Cortical control of facial expression.

René M. Müri^{1,2,3}

¹Division of Cognitive and Restorative Neurology, Departments of Neurology and Clinical Research, University Hospital Inselspital, Bern, Switzerland

²Gerontechnology and Rehabilitation Group, University of Bern, Bern, Switzerland

³Center for Cognition, Learning, and Memory, University of Bern, Bern, Switzerland

Abbreviated title: Cortical control of facial expression

Key words: human, facial expression, emotion, facial innervation

This article has been accepted for publication and undergone full peer review but has not been through the copyediting, typesetting, pagination and proofreading process which may lead to differences between this version and the Version of Record. Please cite this article as an 'Accepted Article', doi: 10.1002/cne.23908

© 2015 Wiley Periodicals, Inc.

Received: Jan 31, 2015; Revised: Sep 19, 2015; Accepted: Sep 25, 2015

Abstract

The present topical review deals with the motor control of facial expressions in humans. Facial expressions are a central part of human communication. Emotional face expressions have a crucial role in human non-verbal behavior, allowing a rapid transfer of information between individuals. Facial expressions can be both voluntarily or emotionally controlled.

Recent studies in non-human primates and humans revealed that the motor control of facial expressions has a distributed neural representation. At least 5 cortical regions on the medial and lateral aspects of each hemisphere are involved: the primary motor cortex, the ventral lateral premotor cortex, the supplementary motor area on the medial wall, and, finally, the rostral and caudal cingulate cortex. The results of studies in humans and non-human primates suggest that the innervation of the face is bilaterally controlled for the upper part, and mainly contralaterally controlled for the lower part. Furthermore, the primary motor cortex, the ventral lateral premotor cortex, and the supplementary motor area are essential for the voluntary control of facial expressions. In contrast, the cingulate cortical areas are important for emotional expression, since they receive input from different structures of the limbic system.

Introduction

The importance of the human face expression is reflected in art and philosophy since antiquity. Cicero considered facial expressions as “Imago animi vultus” (Cicero, de oratore), the image of the soul. Facial expression was also considered to have prognostic value. For instance, the “facies hippocratica”, or Hippocratic facies, had an empiric, negative prognostic significance, since it indicated that the patient “had moved into the atrium of death.” (Illich, 1995).

In humans, the motor nucleus of the facial nerve is the largest of all motor nuclei of the brainstem (Cattaneo and Pavesi, 2014). The comparative anatomy of the facial musculature and of the central nervous apparatus that controls facial movements suggest that, in some primates, group size, facial motor control, and primary visual cortex evolved with the same pattern (Dobson & Sherwood, 2011).

Species living in relatively large social groups tend to have relatively large facial motor nuclei, and species with enlarged facial nuclei and facial mobility have rather large primary visual cortices (Dobson, 2009; Barton, 1998). Great apes and humans have facial motor cortices that are thicker and richer in local circuitry, and their facial movements have the highest degree of dependency from the primary motor cortex. Finally, great apes and humans have more pronounced direct cortico-facial projections (Sherwood et al. 2004, Dobson and Sherwood, 2011).

The facial muscular system consists of a flat web of muscular fascicles, embedded in a variable matrix of connective tissue, and packed into a small two-dimensional matrix under the facial skin. In humans, the 17 paired mimetic (from the Greek “mimesis”, imitation) facial muscles are innervated by the facial nerve, and have their distinct embryological origin from the second branchial arch (for a review, see Cattaneo and Pavesi, 2014). Mimetic facial muscles are believed to lack muscle spindles (Stal, 1994), which may reflect the absence of external loads, and imply an absence of stretch reflexes. Thus, the central nervous system has to process sensory information from the skin receptors in order to infer information on facial movements.

Converging evidence suggest that the functional units of the facial muscular system are not represented – as conventionally defined – by the single facial muscle, but rather correspond to smaller bundles of myofibers, each with its own anatomical signature and function (Cattaneo and Pavesi, 2014).

Facial movements can be categorized in voluntary movements, which are coordinated by cortical pathways, in reflexive movements, and in movements driven by central pattern generators, which are mainly located in the brainstem (Gothard, 2014).

Historical aspects

Duchenne de Boulogne (1806-1875) was a French neurologist and physiologist, who was fascinated by the mechanisms controlling human facial expressions. Believing that “l’âme est donc la source de l’expression” (the soul is the source of the facial expression), he studied facial muscular action using galvanic stimulation (Duchenne de Boulogne, 1862, see Figure 1). He identified 33 different expressions, including the “Duchenne smile” (Ekman et al., 1990), and proposed a new nomenclature of the facial muscles, suggesting that there is a specific facial muscle for the expression of each emotion. Duchenne's ideas also influenced Charles Darwin's book “The expression of the emotions in man and animals” (Darwin, 1872).

Figure 1 about here

The different patterns of facial palsy resulting from central or peripheral lesions of the facial innervation were already described in the textbooks of neurology of the 19th century (e.g., von Strümpell, 1884; Mills, 1898). The clinical observation that a hemispheric stroke involving the territory of the middle cerebral artery results in a paralysis of the contralateral lower face, but spares the upper face, was explained by a bilateral innervation of the upper face, and a unilateral, contralateral innervation of the lower face from the primary motor cortex. Jackson (1884) speculated that unilateral movements, such as limb movements and lower face movements, were rather voluntary movements (and thus more vulnerable to damage), whereas bilateral movements, such as movements of the upper face, were less vulnerable to damage because they belonged to a class of rather automatic movements (as cited in Morecraft et al., 2004). Furthermore, Bechterew (1887) and Nothnagel (1889) speculated in their work about the anatomical basis of the striking clinical observation of the dissociation between voluntary and emotional facial innervation after brain lesions.

Human and animal studies

The anatomical organization of the facial nucleus has been elucidated in both primates and humans (Kuypers, 1958a, 1958b; Jenny and Saper, 1987; Sadota et al. 1987; Welt and Abbs 1990; Van der Werf et al. 1998; Morecraft et al., 2001). Histologically, at least four distinct subnuclei are defined (medial, lateral, dorsolateral, and intermediate subnucleus; Kuypers, 1958a; Jenny and Saper, 1987). The facial subnuclei structure presents similarities between primates and humans (Kuypers, 1958a; Jenny and Saper, 1987). The musculotopic pattern is well preserved across mammals and primates, including humans (Sherwood, 2005). Neurons innervating the same facial muscle are arranged together in longitudinal columns, which are oriented cranio-caudally (see Figure 2B; after Morecraft et al., 2001).

Figure 2A and B about here

According to Holstege (2002), the dorsal subgroup of the facial nucleus contains motor neurons innervating the muscles around the eye, and the medial subgroup innervates the muscles of the ear. In humans, this latter group is small, since there is a lack of ear musculature. The opposite is found for the lateral subgroup, which is the largest in humans. This subgroup innervates the muscles of the mouth, which are very well developed in humans. It appears that the dorsal portion of the lateral subgroup innervates the muscles of the upper mouth, whereas its ventral portion innervates the muscles of the lower mouth. Thus, for smiling, the motor neurons responsible for the innervation of the upper mouth, in the dorsal portion, would be activated. Conversely, for negative facial expressions, the ventral portion of the lateral facial subgroup might be more important (Holstege, 2002). Sherwood et al. (2005) studied the evolution of the brainstem orofacial motor system in 47 species of primates. They found that hominids present significantly larger volumes of the facial nucleus than predicted. The authors suggest that the phylogenetic specialization of the facial nucleus may be related to the variation in facial muscle differentiation, and to increased descending inputs from neocortical areas.

The facial nucleus receives very strong afferents from the bed nucleus of the stria terminalis, from the lateral hypothalamus, and, in all likelihood very strongly in humans, from the medial orbitofrontal cortex. Kuipers et al. (2006) have shown that, in the cat, the infralimbic cortex, corresponding to Brodmann area 25 in humans, projects to all parts of the pontine and medullary lateral tegmental field. Although these projections do

not have any direct access to the facial motor neurons, they certainly have indirect access to the mouth part of the facial nucleus. In cats (Hopkins and Holstege, 1978) and in rats (Post and Mai, 1980), direct projections from the amygdala to the facial nucleus have been evidenced. In Macaca monkey, no direct projections have been described, whereas projections from the central amygdaloid nucleus to the parvocellular reticular formation, a premotor structure of the orofacial motor nuclei, have been demonstrated (for a review, see Holstege, 1992).

Five cortical regions project to the facial nucleus (see Figure 2A). It is generally accepted that, in the human and the monkey, the facial representation in the primary motor cortex (M1) lies anterior to the most lateral segment of the central sulcus. Cortico-facial projections from M1 project to all subdivisions of the facial nucleus (Kuypers, 1958b; Jenny and Saper, 1987; Morecraft et al., 2001), with an important portion of the projections innervating the contralateral, lower facial musculature (Morecraft et al., 2001). Such an innervation pattern subtends the clinical observation of a contralesional, lower facial paralysis after damage to M1. However, M1 also sends cortico-facial fibers bilaterally to all musculotopical subdivisions of the facial nucleus, as shown by Jenny and Saper (1987) and Morecraft et al. (2001). Thus, the existence of cortico-facial fibers projecting ipsilaterally to the lateral part of the facial nucleus cannot be excluded. The facial area of the ventral lateral premotor cortex (LPMCv) and the dorsal lateral premotor cortex (LPMCd) are localized anterior to the facial representation of M1 (Luppino and Rizzolatti, 2000). Projections from these areas, especially from the LPMCv, terminate mainly in the contralateral lateral subnucleus, innervating the lower facial muscles (Morecraft et al., 2001). Finally, a third cortical region, the caudal area of the anterior midcingulate, which is named M4 by Morecraft et al. (2001), presents strong projections to the contralateral lateral subnucleus, innervating the muscles of the lower face. This region is localized in the caudal cingulate motor cortex, which resides in area 23c (Picard and Strick, 1996). M4 projections end specifically within the dorsolateral part of the lateral subnucleus, which contains motor neurons innervating the upper, but not the lower, lip (Morecraft et al., 2001). On the medial surface of the cerebral cortex, two facial areas are currently described as projecting bilaterally to the facial nuclei. First, a facial representation within the supplementary motor cortex (a region denominated as M2 in Morecraft's nomenclature) is located in the superior frontal lobule of the medial surface, anterior to the arm representation of M2 and caudal to a region known as the presupplementary motor area (Luppino and Rizzolatti, 2000).

Second, a facial representation region is located in the rostral midcingulate motor cortex (corresponding to M3 in Morecraft's nomenclature; Morecraft et al., 1996, 2001). Both regions project bilaterally to the medial part of the facial nucleus, innervating the upper face. In humans, direct electric stimulation of the rostral portion of the SMA elicits complex patterns of facial movements (Fried et al., 1991), with both contralateral and bilateral movements. Fontaine et al. (2002) found, in 11 patients, that facial palsy occurred after neurosurgical resection of the left SMA, but never after resection of the right SMA. The authors explained this phenomenon by postulating a bilateral representation of the face in the left SMA, which was not present in the right SMA. LeRoux et al. (1991) found that the resection of the non-dominant facial motor cortex does not lead to facial palsy. Other authors (Fried et al., 1991; Bleasel et al., 1996; Bleasel and Luders, 2002) described bilateral movements during intraoperative stimulation, irrespective of the stimulated hemisphere. However, tumors or other slowly evolving pathological processes may induce neuroplastic changes in cortical functions (Duffau, 2014), and thus result in contradictory effects.

Furthermore, the cingulate facial motor areas (i.e., both M3 and M4) may represent critical anatomic entry points for limbic input into the cortical motor system (Morecraft et al., 1998; Morecraft and van Hoesen, 1998). The rostral cingulate motor cortex (M3) receives widespread limbic and prefrontal inputs (Morecraft and Van Hoesen, 1993, 1998; Morecraft et al., 1998, Morecraft et al., 2007). The primate amygdala is central for the recognition of, and the response to, social stimuli such as faces (Rutishauser et al., 2015). The projections from the amygdala to M3, and from M3 to the facial nucleus (Morecraft et al., 2007) allow to consider M3 as one of the higher-order motor areas of the cortex (Shima et al., 1991; Shima and Tanji, 1998). This area is thought to be involved in the mediation of the expression of upper facial higher-order emotions, such as fear, anger, happiness, and sadness (Morecraft et al., 2007).

Dissociation between voluntary and emotional facial innervation in humans

The observation of double dissociations between different facial movements resulted, already in the 19th century, in the suggestion that separate neural structures are involved in voluntary and emotional facial movements. Facial emotional expressions are a mainstay of non-verbal communication. Ekman (1993) suggested that these highly stereotyped facial postures are, at least in part, archetypal, since there is a high agreement in the classification of facial emotional expressions in almost all cultures. A

limited number of elementary emotional states – fear, disgust, joy, sadness, anger, and surprise – are associated with stereotyped facial expressions. These seem to be hard-wired in the human motor system, resulting in an evolutionary advantage (Darwin, 1872). Facial expressions are also part of stereotyped physiological responses to particular affective states, involving both the autonomic and the somatic systems, which are controlled by the so-called “emotional motor system” (Holstege, 1992; Holstege 2002).

In humans, most information concerning the emotional innervation of the face comes from studies of the results of focal lesions due to stroke, neurosurgical interventions, or electrical stimulation during interventions. The methodological problem with lesion studies is that the extension of the lesions often encompasses more than one key anatomical structure, sometimes resulting in inconsistent findings. Isolated emotional facial palsy (Figure 3B), which is far less frequent than voluntary facial palsy, has been described following lesions of the contralateral anterolateral and posterior thalamus, of the anterior striatocapsular region, or of the medial frontal lobes (Bogousslavsky et al., 1988; Hopf et al., 1992, 2000; Michel et al., 2008; Ross and Mathiesen, 1998; Trosch et al., 1990).

Figure 3 about here

Furthermore, an isolated emotional palsy can occur at very distal location with respect to the lesion, such as in the ipsilateral pons and medulla (Cerrato et al., 2003; Hopf et al., 2000; Khurana et al., 2002). The much more frequent condition of a voluntary facial palsy with sparing of emotional face movements (Figure 3A) may occur after a wide variety of different lesion locations ranging from the motor cortex and descending the pyramidal tract to the brainstem (Bouras et al., 2007; Hopf et al., 1992; Kappos and Mehling, 2010; Topper et al., 1995; Trepel et al., 1996; Urban et al., 1998, 2001). The fact that dissociations between emotional and voluntary facial movements are also found at the level of the brainstem suggests that these two systems are independent up to the facial nucleus. Furthermore, this fact suggests the existence of an alternative, fronto-thalamo-pontine pathway projecting to the facial nucleus, which is distinct from the facial contingent of the cortico-nuclear tract. The behavioral consequences of such an organization are that the voluntary motor system cannot gain access to a genuine emotional motor pattern. In other words, such an organization is the

reason why it is not possible to voluntarily produce a genuine emotional facial expression. As discussed by Cattaneo and Pavesi (2014), a striking feature of emotional facial palsy is that it is unilateral, indicating that emotional movements of each half of the face are represented separately in the contralateral hemisphere.

The empirical observation that a small degree of asymmetry in facial expressions exists at the population level led to different controversial models, dealing with hemispheric specialization of production of facial emotions. At present, two main hypotheses have been proposed: 1) the right hemisphere hypothesis; and, 2) the upper-lower facial axis hypothesis of emotional expression (for a recent review, see Murray et al., 2015). The results of many studies support the right hemisphere hypothesis, postulating that the left side of the face is more emotionally expressive than the right side (e.g., Borod et al. 1988, 1997; Campbell 1978; Sackeim and Gur 1978; Sackeim et al. 1978). Borod et al. (1997) reviewed the results of 49 published experiments, and concluded that the left hemiface is more involved in the expression of facial emotions than the right hemiface.

From a neuropsychological perspective, these findings suggest that the right cerebral hemisphere is dominant for the facial expression of emotions. An alternative model proposes that positive emotional expressions are lateralized to the left hemisphere, and negative emotions are lateralized to the right hemisphere- (Davidson et al., 1990). Finally, the production of facial patterns for “social” emotions, which are development-dependent and acquired later during infancy, would be lateralized to the left hemisphere.

The second hypothesis – the upper-lower facial axis hypothesis of emotional expression – is related to the theory that the left hemisphere preferentially processes voluntary, social emotional displays, which are enacted by the lower hemiface. Ross et al., in a series of publications (e.g. Ross et al., 1994, 2007a, 2007, 2013, Ross and Pulusu, 2013), have argued that emotional displays in the upper hemiface are preferentially processed by the right hemisphere, whereas emotional display in the lower hemiface are processed by the left hemisphere. This hypothesis is also supported by the different neuroanatomic connections for the upper versus the lower face discussed above.

Conclusions

The identification of multiple cortical facial motor areas emphasizes the idea that the higher-order regulation processes of facial expression are not likely to occupy a specific site of the brain, nor to manifest through a single neural projection system (Morecraft et

al., 2004). Facial expressions are controlled through a distributed network, through multiple areas involving the cortical facial areas reviewed in this article. Cortical projections from the lateral facial representations, from the primary motor cortex and LPMCv, and from the caudal cingulate motor cortex may mainly influence the contralateral, lower facial muscles. Medial motor areas, including the supplementary motor area and the rostral cingulate motor cortex, control the upper facial muscles, possibly bilaterally. Furthermore, the cingulate cortico-facial projections, which receive input from the amygdala, play a special role in emotional expression. The cortico-facial projections from the lateral part of the frontal lobe may, in contrast, play a significant role in the control of voluntary facial movements. Thus, current results represent strong arguments against the classical clinical interpretation of the facial nucleus as being cortically innervated.

The reviewed studies also suggest that sparing of the upper facial musculature following a middle cerebral artery stroke is due to sparing of the projections from supplementary motor areas and from the rostral cingulate cortex, which are located in the territory of the anterior cerebral artery. In terms of the dissociation between voluntary and emotional facial palsy, the projections from the caudal cingulate motor cortex, which receives strong inputs from the limbic lobe, may play a role in overcoming the voluntary palsy of the contralesional lower face.

Literature

Barton RA. 1998. Visual specialization and brain evolution in primates. *Proc Biol Sci* 1265:1933-1937.

Bechterew, W. 1887. Die Bedeutung der Sehhügel auf Grund von experimentellen und pathologischen Daten. *Arch Pathol Anat Physiol Klin Med* 110:102-154.

Bleasel A, Comair Y, Luders HO. 1996. Surgical ablations of the mesial frontal lobe in humans. In: Luders HO, ed. *Advances in Neurology*. Vol. 70: Supplementary Sensorimotor Area. Philadelphia: Lippincott-Raven; pp. 217-235.

Bleasel A, Luders H. 2002. Comments on "Somatotopy of the supplementary motor area: evidence from correlation of the extent of surgical resection with the clinical patterns of deficit" by Fontaine et al. *Neurosurgery* 50:304.

Bogousslavsky J, Regli F, Uske A. 1988. Thalamic infarcts: clinical syndromes, etiology, and prognosis. *Neurology* 38:837–848.

Borod JC, Kent J, Koff E, Martin C, Alpert, M. 1988. Facial asymmetry while posing positive and negative emotions: Support for the right hemisphere hypothesis. *Neuropsychologia* 26:759–764.

Borod JC, Haywood CS, Koff E. 1997. Neuropsychological aspects of facial asymmetry during emotional expression: a review of the normal adult literature. *Neuropsychol Rev* 7:41–60.

Bouras T, Stranjalis G, Sakas DE. 2007. Traumatic midbrain hematoma in a patient presenting with an isolated palsy of voluntary facial movements. Case report. *J Neurosurg* 107:158–160.

Campbell, R. 1978. Asymmetries in interpreting and expressing a posed facial expression. *Cortex* 14:327–342.

Cattaneo L, Pavesi G. 2014. The facial motor system. *Neurosci Biobehav Rev* 38:135–159.

Cerrato P, Imperiale D, Bergui M, Giraud M, Baima C, Grasso M, Lentini A, Bergamasco B. 2003. Emotional facial paresis in a patient with a lateral medullary infarction. *Neurology* 60:723–724.

Darwin C. 1872. *The expression of the emotions in man and animals*. John Murray, London.

Davidson RJ, Ekman P, Saron CD, Senulis JA, Friesen WV. 1990. Approach-withdrawal and cerebral asymmetry: emotional expression and brain physiology. I. *J Pers Soc Psychol* 58:330–341.

Dobson SD, Sherwood CC. 2011. Correlated evolution of brain regions involved in producing and processing facial expressions in anthropoid primates. *Biol Lett* 7: 86–88.

Dobson SD. 2009. Socioecological correlates of facial mobility in nonhuman anthropoids. *Am J Phys Anthropol* 139:413–420.

Drouin E, Péréon Y. 2013. Unique drawings by Duchenne de Boulogne. *Lancet Neurol* 12:330–331.

Duchenne G-B. (1862). *Mécanisme de la physionomie humaine, ou analyse électro-physiologique de ses différents modes de l'expression*. Paris: Archives générales de médecine, P. Asselin.

Duffau H. 2014. Diffuse low-grade gliomas and neuroplasticity. *Diagn Interv Imaging* 95:945-55.

Ekman P, Davidson RJ, Friesen WV. 1990. The Duchenne smile: emotional expression and brain physiology. II. *J Pers Soc Psychol* 58:342-353.

Ekman P. 1993. Facial expression and emotion. *Am Psychol* 48:384-392.

Fontaine D, Capelle L, Duffau H. 2002. Somatotopy of the supplementary motor area: evidence from correlation of the extent of surgical resection with the clinical pattern of deficit. *Neurosurgery* 50:297-303.

Fried I, Katz A, McCarthy G, Sass KJ, Williamson P, Spencer SS, Spencer DD. 1991. Functional organization of human supplementary motor cortex studied by electrical stimulation. *J Neurosci* 11:3656-3666.

Gothard KM. 2014. The amygdalo-motor pathways and the control of facial expressions. *Front Neurosci*. Mar 19;8:43. doi: 10.3389/fnins.2014.00043. eCollection 2014.

Holstege G. 1992. The emotional motor system. *Eur J Morphol* 30: 67-81.

Holstege G. 2002. Emotional innervation of facial musculature. *Mov Dis* 17, Suppl. 2:12-16.

Hopf HC, Fitzek C, Marx J, Urban PP, Thomke F. 2000. Emotional facial paresis of pontine origin. *Neurology* 54:1217.

Hopf HC, Muller-Forell W, Hopf NJ. 1992. Localization of emotional and volitional facial paresis. *Neurology* 42:1918-1923.

Hopkins DA, Holstege G. 1978. Amygdaloid projections to the mesencephalon, pons and medulla oblongata in the cat. *Exp Brain Res* 32:529-547.

Illich I. 1995. Death undefeated. *BMJ*. 311:1652-1653.

Jenny AB, Saper CB. 1987. Organization of the facial nucleus and corticofacial projection in the monkey: a reconsideration of the upper motor neuron facial palsy. *Neurology* 37:930-939.

Kappos L, Mehling M. 2010 Dissociation of voluntary and emotional innervation after stroke. *N Engl J Med* 363:e25.

Khurana D, Sreekanth VR, Prabhakar S. 2002. A case of emotional facial palsy with ipsilateral anterior inferior cerebellar artery territory infarction. *Neurol India* 50:102–104.

Kuipers R, Mensinga GM, Boers J, Klop EM, Holstege G. 2006. Infralimbic cortex projects to all parts of the pontine and medullary lateral tegmental field in cat. *Eur J Neurosci* 23:3014–3024.

Kuypers, HGJM. 1958a. Corticobulbar connections to the pons and lower brainstem in man. An anatomical study. *Brain* 81:364–388.

Kuypers, HGJM. 1958b. Some projections from the peri-central cortex to the pons and lower brain stem in monkey and chimpanzee. *J Comp Neurol* 110:221-255.

LeRoux PD, Berger MS, Haglund MM, Pilcher WH, Ojemann GA. 1991. Resection of intrinsic tumors of nondominant face motor cortex using stimulation mapping: Report of two cases. *Surg Neurol* 36:44–48.

Luppino G, Rizzolatti G. 2000. The organization of the frontal motor cortex. *News Physiol Sci* 15:219–224.

Michel L, Derkinderen P, Laplaud D, Daumas-Duport B, Auffray-Calvier E, Lebouvier T. 2008. Emotional facial palsy following striato-capsular infarction. *J Neurol Neurosurg Psychiatry* 79:193–194.

Mills CK. 1898. *The Nervous System and its Diseases: A Practical Treatise on Neurology for the use of Physicians and Students*. Philadelphia: J.B. Lippincott Co.

Morecraft RJ, Avramov K, Schroeder CM, Stilwell-Morecraft KS. 1998. Amygdala connections with the cingulate motor cortex: preferential innervation of the face and arm representations of M3 (area 24c) in the rhesus monkey. *Soc Neurosci Abstr* 24:653.

Morecraft RJ, Louie JL, Herrick JL, Stilwell-Morecraft KS. 2001. Cortical innervation of the facial nucleus in the non-human primate: a new interpretation of the effects of stroke and related subtotal brain trauma on the muscles of facial expression. *Brain* 124:176–208.

Morecraft RJ, Schroeder CM, Keifer J. 1996. Organization of face representation in the cingulate cortex of the rhesus monkey. *Neuroreport* 7:1343–1348.

Morecraft RJ, Stilwell-Morecraft KS, Rossing WR. 2004. The motor cortex and facial expression: new insights from neuroscience. *Neurologist* 10:235-249.

Morecraft RJ, Van Hoesen GW. 1993. Frontal granular cortex input to the cingulate (M3), supplementary (M2) and primary (M1) motor cortices in the rhesus monkey. *J Comp Neurol* 337: 669-689.

Morecraft RJ, Van Hoesen GW. 1998. Convergence of limbic input to the cingulate motor cortex in the rhesus monkey. *Brain Res Bull* 45: 209-232.

Murray EM, Krause WH, Stafford RJ, Bono AD, Meltzer EP, Borod JC. 2015 Asymmetry of facial expressions of emotion. In: Mandal MK, Awasthi A. (eds.) *Understanding facial expressions in communication. Cross-cultural and multidisciplinary perspectives.* Springer New Delhi Heidelberg New York Dordrecht London. pp. 73-99.

Nothnagel H. 1889. Zur Diagnose der Sehhügelkrankungen. *Z Klin Med* 24:424-430.

Picard N, Strick PL. 1996. Motor areas of the medial wall: a review of their location and functional activation. *Cereb Cortex* 6:342-353.

Post S, Mai JK. 1980. Contribution to the amygdaloid projection field in the rat. A quantitative autoradiographic study. *J Hirnforsch* 21:199-225.

Ross ED, Homan RW, Buck R. 1994. Differential hemispheric lateralization of primary and social emotions implications for developing a comprehensive neurology for emotions, repression, and the subconscious. *Cogn Behav Neurol* 7:1-19.

Ross ED, Prodan CI, Monnot M. 2007a. Human facial expressions are organized functionally across the upper-lower facial axis. *Neuroscientist* 13:433-446.

Ross ED, Pulusu VK. 2013. Posed versus spontaneous facial expressions are modulated by opposite cerebral hemispheres. *Cortex* 49:1280-1291.

Ross ED, Reddy AL, Nair A, Mikawa K, Prodan CI. 2007b. Facial expressions are more easily produced on the upper-lower compared to the right-left hemiface. *Perceptual and Motor Skills* 104_155-165.

Ross ED, Shayya L, Champlain A, Monnot M, Prodan CI. 2013b. Decoding facial blends of emotion: Visual field, attentional and hemispheric biases. *Brain and Cognition* 83:252-261.

Ross RT, Mathiesen R. 1998. Images in clinical medicine. Volitional and emotional supranuclear facial weakness. *N Engl J Med* 338:1515.

Rutishauser U, Mamelak AN, Adolphs R. 2015. The primate amygdala in social perception - insights from electrophysiological recordings and stimulation. *Trends Neurosci* 38:295-306.

Sackeim HA, Gur RC. 1978. Lateral asymmetry in intensity of emotional expression. *Neuropsychologia* 16:473-481.

Sackeim HA, Gur RC, Saucy MC. 1978. Emotions are expressed more intensely on the left side of the face. *Science* 202:434-436.

Satoda T, Takahashi O, Tashiro T, Matsushima R, Uemura-Sumi M, Mizuno N. 1987. Representation of the main branches of the facial nerve within the facial nucleus of the Japanese monkey (*Macaca fuscata*). *Neurosci Lett* 78:283-287.

Sherwood CC. 2005. Comparative anatomy of the facial motor nucleus in mammals, with an analysis of neuron numbers in primates. *Anat Rec Part A* 287A:1067-1079.

Sherwood CC, Hof PR, Holloway RL, Semendeferi K, Gannon PJ, Frahm HD, Zilles K. 2005. Evolution of the brainstem orofacial motor system in primates: a comparative study of trigeminal, facial, and hypoglossal nuclei. *J Hum Evol* 48:45-84.

Sherwood CC, Holloway RL, Erwind JM, Schleicher A, Zilles K, Hof PR. 2004. Cortical orofacial motor representation in Old World monkeys, great apes, and humans I. Quantitative analysis of cytoarchitecture. *Brain Behav Evol* 63:61-81.

Shima K, Aya K, Mushiake H, Inase M, Aizawa H, Tanji J. 1991. Two movement-related foci in the primate cingulate cortex observed in signal-triggered and self-paced forelimb movements. *J Neurophysiol* 65: 188-202.

Shima K, Tanji J. 1998. Role for cingulate motor area cells in voluntary movement selection based on reward. *Science* 282: 1335-1338.

Stål P. 1994. Characterization of human oro-facial and masticatory muscles with respect to fibre types, myosins and capillaries. Morphological, enzyme-histochemical, immunohistochemical and biochemical investigations. *Swed Dent J Suppl* 98:1-55.

Topper R, Kosinski C, Mull M. 1995. Volitional type of facial palsy associated with pontine ischaemia. *J Neurol Neurosurg Psychiatry* 58 :732-734.

Trepel M, Weller M, Dichgans J, Petersen D. 1996. Voluntary facial palsy with a pontine lesion. *J Neurol Neurosurg Psychiatry* 61:531–533.

Trosch RM, Sze G, Brass LM, Waxman SG. 1990. Emotional facial paresis with striatocapsular infarction. *J Neurol Sci* 98 :195–201.

Urban PP, Wicht S, Marx J, Mitrovic S, Fitzek C, Hopf HC. 1998. Isolated voluntary facial paresis due to pontine ischemia. *Neurology* 50:1859–1862.

Urban PP, Wicht S, Vucorevic G, Fitzek S, Marx J, Thomke F, Mika-Gruttner A, Fitzek C, Stoeter P, Hopf HC. 2001. The course of corticofacial projections in the human brainstem. *Brain* 124 :1866–1876.

VanderWerf F, Aramideh M, Otto JA, Ongerboer de Visser BW. 1998. Retrograde tracing studies of subdivisions of the orbicularis oculi muscle in the rhesus monkey. *Exp Brain Res* 121:433–441.

Welt C, Abbs JH. 1990. Musculotopic organization of the facial motor nucleus in *Macaca fascicularis*: a morphometric and retrograde tracing study with cholera toxin B-HRP. *J Comp Neurol* 291:621–636.

Legends

Figure 1

Original drawing by Duchenne, showing the famous toothless cobbler undergoing electrical stimulation of the face (from Drouin and Péréon, 2013; with permission)

Figure 2


A. Schematic representation of the topographical localization of the motor areas on the medial and lateral surface of the cerebral cortex. Abbreviations: M1, primary motor cortex; M2, supplementary motor area; M3, posterior cingulate motor cortex; M4, rostral cingulate motor cortex; LPMCd, dorsal lateral premotor cortex; LPMCv, ventral lateral premotor cortex; A, arm; as, arcuate sulcus; cf, calcarine fissure; cgs, cingulate sulcus; cs, central sulcus; F, face; FEF, frontal eye field; ios, inferior occipital sulcus; ips, intraparietal sulcus; L, leg; lf, lateral fissure; LL, lower lip; ls, lunate sulcus; pre-SMA, pre-supplementary motor cortex; rs, rhinal sulcus; SEF, supplementary eye field; sts,

superior temporal sulcus; poms, medial parieto-occipital sulcus; (from Morecraft et al., 2001; with permission)

B. Schematic representation of the major cortico-facial projections in the non-human primate. Upper part, left panel: Unilateral lower face innervation by M1, LPMCv, and M4. These cortical regions project to the lateral subnucleus of the facial nucleus (FN). Upper part, right panel: Bilateral upper face innervation by M2 and M3. These cortical regions project to the medial, intermediate, and dorsal subnuclei of the facial nucleus. Lower part: Schematic representation of the location of the facial nucleus in the lower pons. On the magnified images of the facial nucleus, the main nuclear subdivisions are shown on the right side, and the musculotopic organization on the left side. Abbreviations: Ea, ear; Fr, frontalis; LL, lower lip; OO, orbicularis oculi; P, platysma; UL, upper lip (from Morecraft et al., 2001; with permission)

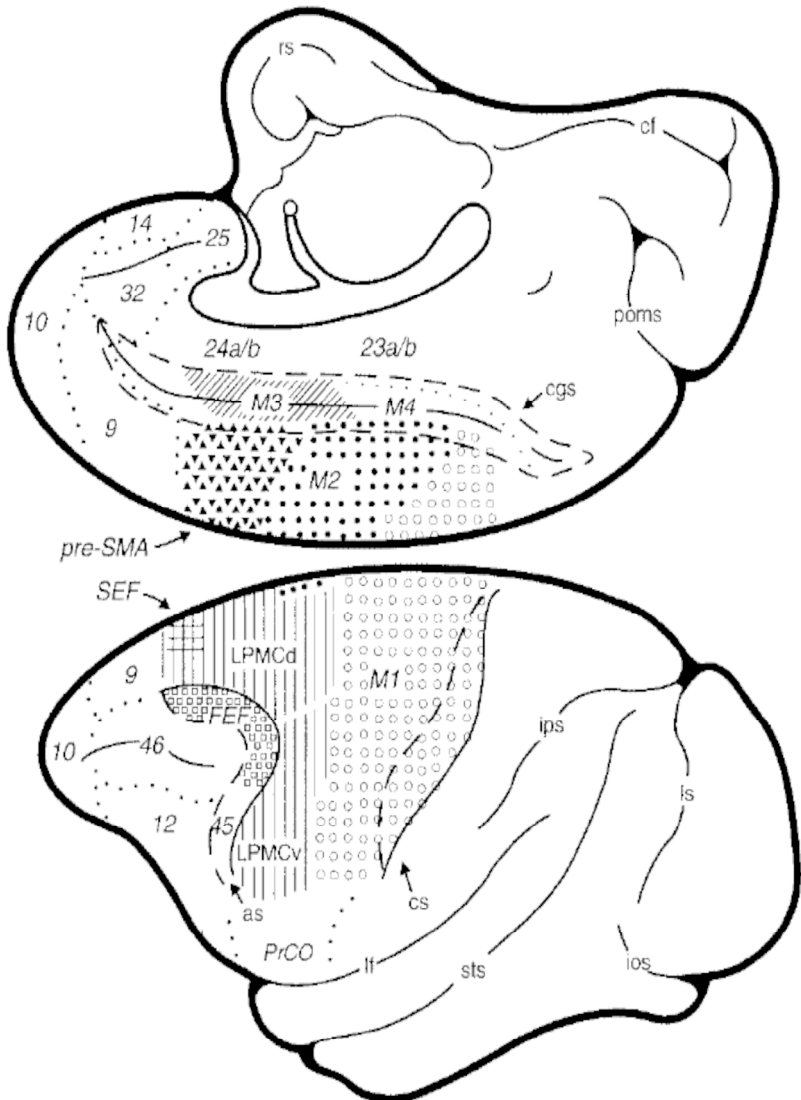
Figure 3

Dissociation between voluntary and emotional facial innervation. Patient A suffered from a focal stroke of the right motor cortex. During emotional smiling, the patient was able to overcome the left facial paralysis. However, during voluntary innervation, facial paralysis was apparent. Diffusion-weighted magnetic resonance imaging showed a hyperintensity in the right precentral gyrus (from Kappos and Mehling, 2010; with permission). Patient B suffered from a stroke in the left upper medulla oblongata. Central facial paresis was evident when the patient smiled, but disappeared almost completely during voluntary contraction. T2-weighted magnetic resonance imaging showed a hyperintensity located immediately ventral to the profile of the inferior cerebellar pedicle (from Cerrato et al., 2003; with permission).



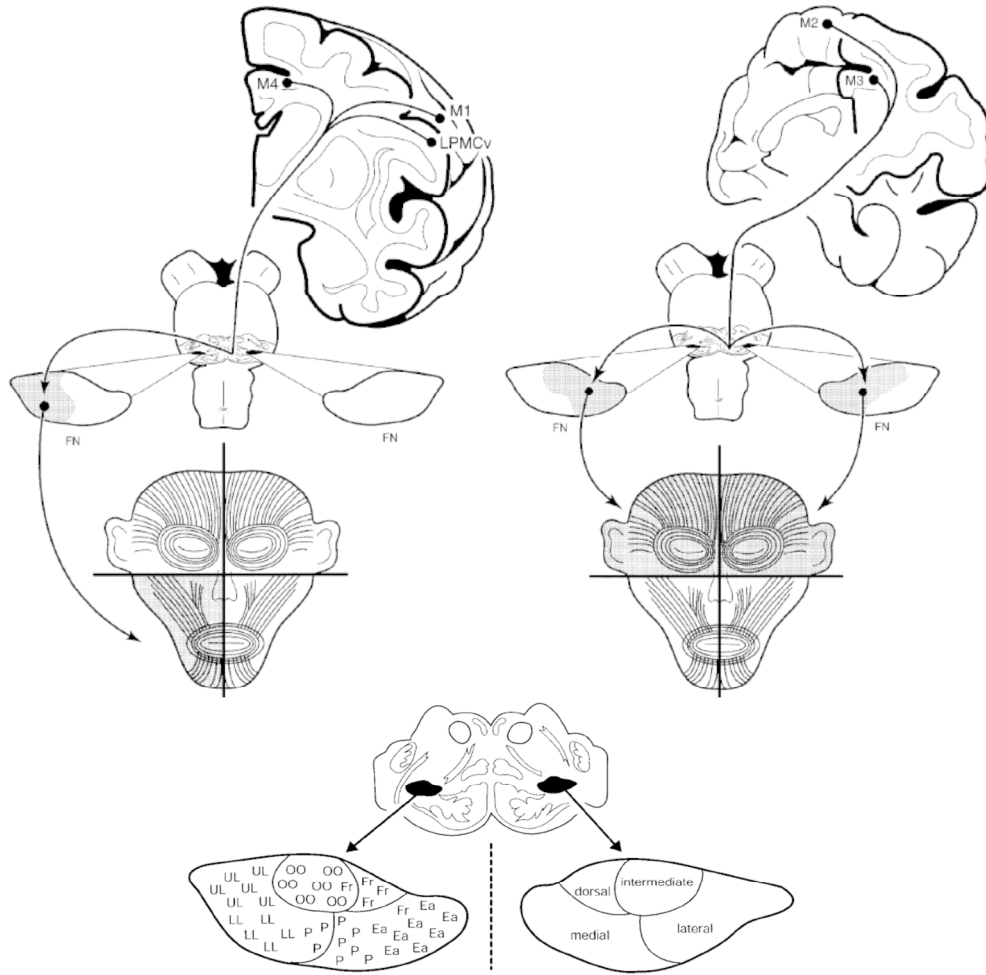
150x112mm (300 x 300 DPI)

Accept



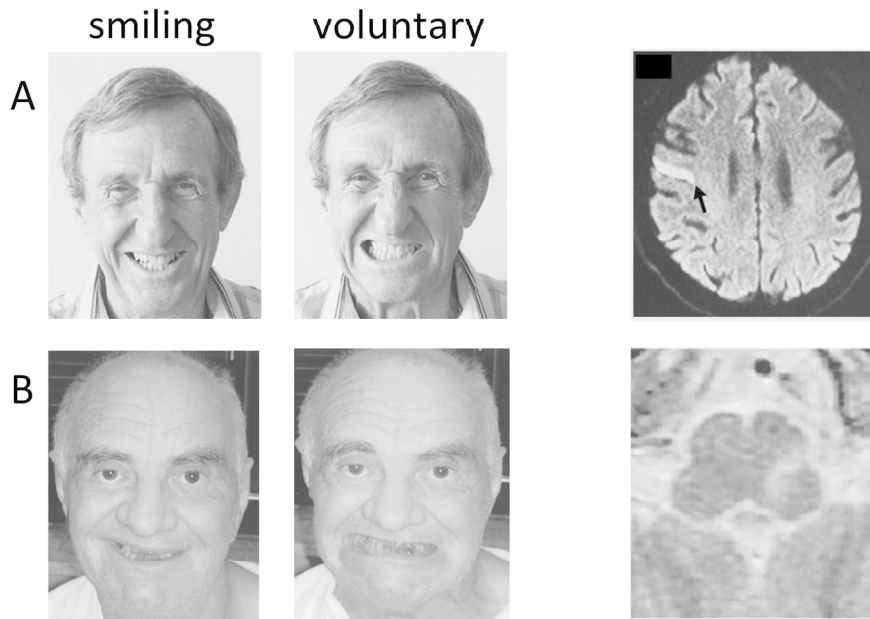
137x160mm (600 x 600 DPI)

AC



190x186mm (600 x 600 DPI)

Acce

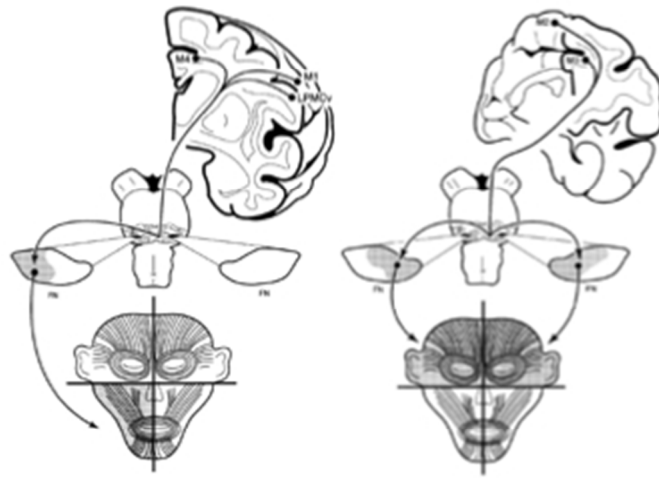


160x119mm (300 x 300 DPI)

Accept

Accepted Article

Facial expressions are central part of human non-verbal behavior and communication. Facial expression is both voluntarily and emotionally controlled. Recent studies in non-human primates and humans revealed that motor control of facial expression is distributed. At least 5 cortical regions on the medial and lateral hemisphere are involved. The primary motor cortex, the ventral lateral premotor cortex and the supplementary motor area are important for the voluntary control of facial expression, the cingulate areas are important for emotional innervation, since they receive input from many regions of the limbic system.



141x105mm (72 x 72 DPI)

Accepted