

**EVERY LIKE IS NOT THE SAME**



**To the Editor:**

We read with great interest the report about the late outcome of decellularized aortic homografts (DAH) used for aortic valve replacement (AVR) in middle-aged adults, one-quarter of patients having acute endocarditis.<sup>1</sup>

Helder et al<sup>1</sup> described a trend for higher reoperation rates in DAH versus standard cryopreserved homografts and comparable histological modes of degeneration. We,

as the investigators of a European-wide prospective trial on DAH for AVR, however, felt that the title may be somewhat misleading, as every like is not the same.

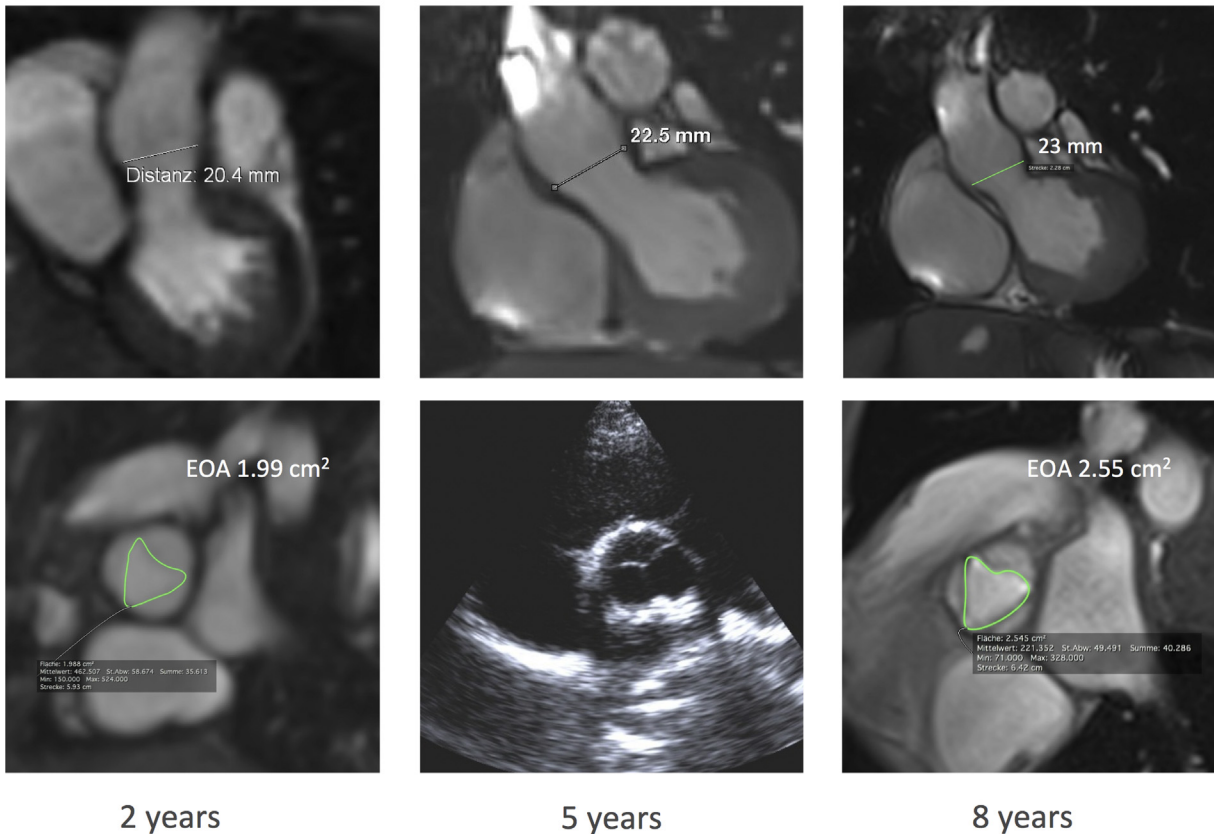
Decellularization of biological matrices can be performed by different protocols and results may not necessarily be comparable, as mechanical properties of the matrix structure are crucial for durability. Preservation of the matrix structure is also essential for recellularization. Homografts in the report by Helder et al<sup>1</sup> have been cryopreserved and radiated before implantation. Both of these procedures have been demonstrated to affect the ultrastructure.<sup>2</sup> In contrast, the ARISE trial is evaluating fresh, non-cryopreserved DAH for AVR.

Previous work has shown auspicious early results in a limited cohort of children and young adults (n = 69, mean age 19.7 ± 14.6 years, mean follow-up 2.0 ± 1.8 years) prone to rapid degeneration and regeneration.<sup>3,4</sup>

Anecdotal experience from some of our grafts has been favorable. Figure 1 (and the Videos 1-3) show the excellent function of such a homograft 8 years after implantation in an 8-year-old girl without any evidence of degeneration or

The Editor welcomes submissions for possible publication in the Letters to the Editor section that consist of commentary on an article published in the Journal or other relevant issues. Authors should: • Include no more than 500 words of text, three authors, and five references. • Type with double-spacing. • See <http://jtcvs.ctsnetjournals.org/misc/fora.shtml> for detailed submission instructions. • Submit the letter electronically via [jtcvs.editorialmanager.com](http://jtcvs.editorialmanager.com). Letters commenting on an article published in the JTCVS will be considered if they are received within 6 weeks of the time the article was published. Authors of the article being commented on will be given an opportunity of offer a timely response (2 weeks) to the letter. Authors of letters will be notified that the letter has been received. Unpublished letters cannot be returned.

**Follow up of a 18 mm homograft in a 8-year old girl**



**FIGURE 1.** Follow-up after implantation of an 18-mm fresh, noncryopreserved decellularized aortic homograft in an 8-year-old girl. Within 8 years, no degeneration of cusps was observed, aortic valve ring and effective orifice area increased.



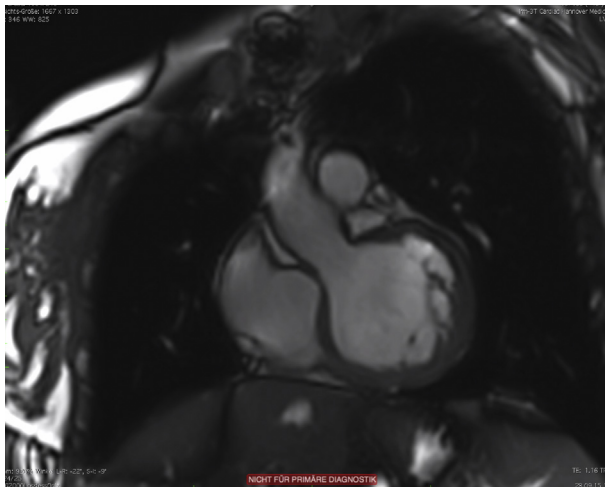
Video clip is available online.

Axel Haverich holds shares in corlife oHG, a company for the processing of decellularized allografts used in this study. All other authors have nothing to disclose with regard to commercial support.

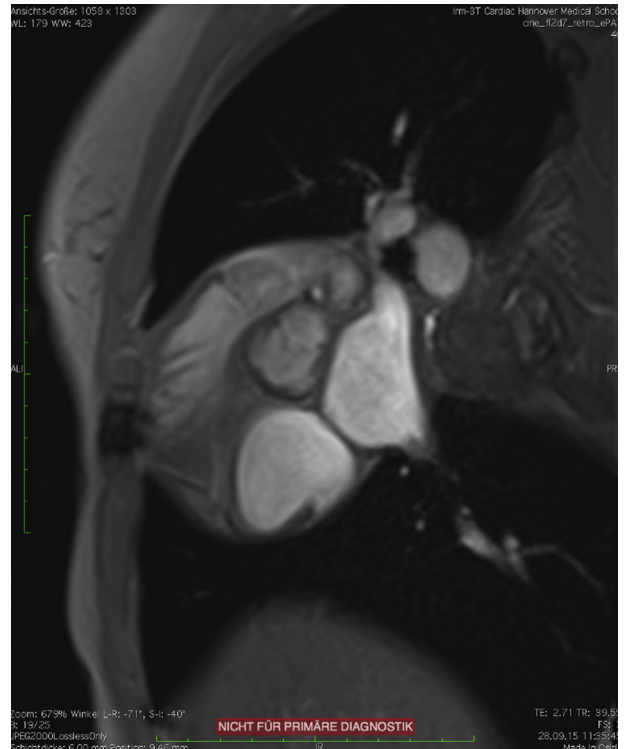
calcification. We also did not see calcification in a histological examination of an explanted aortic valve 4.5 years after implantation in an 8-week-old infant. Recellularization by noninflammatory recipient cells was seen in this patient, where the aortic valve developed regurgitation potentially related to a recurrent subvalvular stenosis.<sup>3</sup>

In another infant, 4 months after implantation of non-valved DAH in a staged Norwood procedure, adequate recellularization was found in the outer two-thirds of the circumference, underlining the importance of the adventitial space.<sup>5</sup>

Good long-term performance of DAH necessitates integration of the graft and regeneration by recellularization, which, however, is much more likely to occur when there is a near-normal anatomic position and blood flow. Even a normal heart valve will degenerate in pathological flow conditions due to limited regenerative capacity in such situation. One, to our understanding, cannot expect a decellularized homograft to perform even better and we

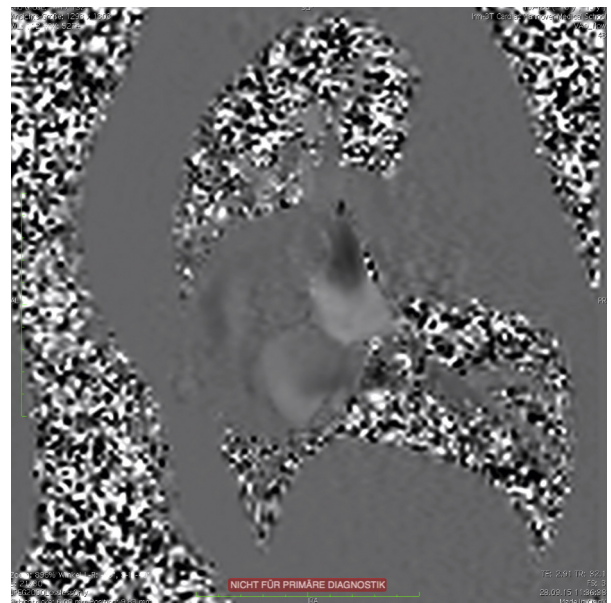


**VIDEO 1.** Coronal cine view of the LVOT showing good integration of the decellularized homograft and normal left ventricular function 8 years after implantation in an 8-year-old girl. Video available at: [http://www.jtcvsonline.org/article/S0022-S0022-5223\(17\)30180-0/addons](http://www.jtcvsonline.org/article/S0022-S0022-5223(17)30180-0/addons).



**VIDEO 2.** Orthogonal cine view of the aortic valve showing normal opening and closure. Video available at: [http://www.jtcvsonline.org/article/S0022-S0022-5223\(17\)30180-0/addons](http://www.jtcvsonline.org/article/S0022-S0022-5223(17)30180-0/addons).

therefore aim for almost laminar flow conditions and we also aim to avoid obstruction for recellularization, such as tissue-glue, foreign material, or wrapping procedures.



**VIDEO 3.** Phase-contrast flow imaging of the aortic valve demonstrating complete competence and unobstructed flow. Video available at: [http://www.jtcvsonline.org/article/S0022-S0022-5223\(17\)30180-0/addons](http://www.jtcvsonline.org/article/S0022-S0022-5223(17)30180-0/addons).

Acute endocarditis cannot be viewed as an ideal setting for recellularization by regular recipient cells. The open matrix may even allow for bacterial invasion, thereby prompting infiltration of immune competent cells and inflammatory cascades leading to early calcification. We, therefore, do not recommend the use of decellularized matrices in the setting of acute endocarditis, even though the endocarditis susceptibility of DAH at this point appears low.

The ARISE investigators strongly agree with the editorial comments made by Dr Bando proposing late outcome studies on DAH.<sup>6</sup> In fact, prospective long-term follow-up is part of both investigator-initiated European-wide trials on fresh decellularized allografts for pulmonary and aortic valve replacement<sup>7,8</sup> to answer the question of whether such homografts are really superior, or just fashion.<sup>9</sup>

Samir Sarikouch, MD, PhD<sup>a</sup>  
 Axel Haverich, MD, PhD<sup>a</sup>  
 John Pepper, MA.M.Chir. FRCS<sup>b</sup>  
 Jose L. Pomar, MD, PhD<sup>c</sup>  
 Mark Hazekamp, MD, PhD<sup>d</sup>  
 Massimo Padalino, MD, PhD<sup>e</sup>  
 Giovanni Stellin, MD, PhD<sup>e</sup>  
 Bart Meyns, MD, PhD<sup>f</sup>  
 Günther Laufer, MD, PhD<sup>g</sup>  
 Martin Andreas, MD, PhD<sup>g</sup>  
 Michael Hübler, MD, PhD<sup>h</sup>  
 Martin Schmiady, MD<sup>h</sup>  
 Anatol Ciubotaru, MD, PhD<sup>i</sup>  
 Alexander Horke, MD<sup>a</sup>  
 Serghei Cebotari, MD, PhD<sup>a</sup>  
 Igor Tudorache, MD<sup>a</sup>

for the ARISE-Trial-Investigators

<sup>a</sup>Department for Cardiothoracic, Transplant,  
 and Vascular Surgery  
 Hannover Medical School  
 Hannover, Germany

<sup>b</sup>Department of Cardiovascular Surgery  
 Royal Brompton and Harefield  
 NHS Foundation Trust  
 London, United Kingdom

<sup>c</sup>Department of Cardiovascular Surgery  
 Hospital Clinico de Barcelona  
 Barcelona, Spain

<sup>d</sup>Department of Congenital Cardiac Surgery  
 Leiden University Medical Center  
 Leiden, The Netherlands

<sup>e</sup>Pediatric and Congenital Cardiac Surgery Unit  
 Azienda Ospedaliera di Padova  
 University of Padua Medical School,  
 Padua, Italy

<sup>f</sup>Department of Cardiac Surgery

Katholieke Universiteit  
 Leuven, Belgium

<sup>g</sup>Department of Cardiac Surgery  
 Medical University of Vienna  
 Vienna, Austria

<sup>h</sup>Division of Congenital Cardiovascular Surgery  
 University Children's Hospital  
 Zurich, Switzerland

<sup>i</sup>Cardiac Surgery Center  
 State Medical and Pharmaceutical University  
 Chisinau, Moldova

The ARISE trial receives funding from the European Union's Horizon 2020 research and innovation programme under grant agreement No. 643597.

## References

1. Helder RK, Kouchoukos NT, Zehr K, Dearani JA, Maleszewski JJ, Leduc C, et al. Late durability of decellularized allografts for aortic valve replacement: a word of caution. *J Thorac Cardiovasc Surg.* 2016;152:1197-9.
2. Sarathchandra P, Smolenski RT, Yuen AH, Chester AH, Goldstein S, Heacox AE, et al. Impact of  $\gamma$ -irradiation on extracellular matrix of porcine pulmonary valves. *J Surg Res.* 2012;176:376-85.
3. Tudorache I, Horke A, Cebotari S, Sarikouch S, Boethig D, Breymann T, et al. Decellularized aortic homografts for aortic valve and aorta ascendens replacement. *Eur J Cardiothorac Surg.* 2016;50:89-97.
4. Sarikouch S, Horke A, Tudorache I, Beerbaum P, Westhoff-Bleck M, Boethig D, et al. Decellularized fresh homografts for pulmonary valve replacement: a decade of clinical experience. *Eur J Cardiothorac Surg.* 2016;50:281-9.
5. Horke A. Decellularization of aortic valves: only time will tell. *Eur J Cardiothorac Surg.* 2016;49:707-8.
6. Bando K. A proposal for prospective late outcome analysis of decellularized aortic valves. *J Thorac Cardiovasc Surg.* 2016;152:1202-3.
7. Aortic Replacement Using Individualised Regenerative Allografts. ARISE home page. Available at: <http://www.arise-clinicaltrial.eu>. Accessed February 27, 2017.
8. European Clinical Study for the Application of Regenerative Heart Valves. ES-POIR home page. Available at: <http://www.espoir-clinicaltrial.eu>. Accessed February 27, 2017.
9. d'Udekem Y. Decellularized homografts: in fashion or really superior? *Eur J Cardiothorac Surg.* 2016;50:291-2.

<http://dx.doi.org/10.1016/j.jtcvs.2017.01.046>



## FINDING THE NEXT GOOD THING



### Reply to the Editor:

Cardiovascular surgeons continue to innovate materials. Artificial vascular grafts such as polytetrafluoroethylene and Dacron have a long history of “adequacy” with acknowledged limits. Bioprosthetic grafts have offered a dense forest of options. Current efforts include cryopreserved homografts, bovine jugular grafts (some with bioprosthetic valves), harvested umbilical vein, and various types of decellularized vascular grafts. Each has potential advantages. Tissue-engineered approaches are starting to show promise. With that many options, it is obvious there is not a perfect choice. In this