



King's Research Portal

DOI:

[10.1007/s11548-023-02905-2](https://doi.org/10.1007/s11548-023-02905-2)

Document Version

Peer reviewed version

[Link to publication record in King's Research Portal](#)

Citation for published version (APA):

Ahmad, M. A., Ourak, M., Wenmakers, D., Valenzuela, I., Basurto, D., Ourselin, S., Vercauteren, T., Deprest, J., & Vander Poorten, E. (2023). Development and validation of a flexible fetoscope for fetoscopic laser coagulation. *International Journal of Computer Assisted Radiology and Surgery*, 18(9), 1603-1611. <https://doi.org/10.1007/s11548-023-02905-2>

Citing this paper

Please note that where the full-text provided on King's Research Portal is the Author Accepted Manuscript or Post-Print version this may differ from the final Published version. If citing, it is advised that you check and use the publisher's definitive version for pagination, volume/issue, and date of publication details. And where the final published version is provided on the Research Portal, if citing you are again advised to check the publisher's website for any subsequent corrections.

General rights

Copyright and moral rights for the publications made accessible in the Research Portal are retained by the authors and/or other copyright owners and it is a condition of accessing publications that users recognize and abide by the legal requirements associated with these rights.

- Users may download and print one copy of any publication from the Research Portal for the purpose of private study or research.
- You may not further distribute the material or use it for any profit-making activity or commercial gain
- You may freely distribute the URL identifying the publication in the Research Portal

Take down policy

If you believe that this document breaches copyright please contact librarypure@kcl.ac.uk providing details, and we will remove access to the work immediately and investigate your claim.

Development and Validation of a Flexible Fetoscope for Fetoscopic Laser Coagulation

Mirza Awais Ahmad* · Mouloud Ourak ·
Dirk Wenmaekers · Ignacio Valenzuela ·
David Basurto · Sebastien Ourselin · Tom
Vercauteren · Jan Deprest · Emmanuel
Vander Poorten

Received: date / Accepted: date

Abstract

Purpose Fetoscopic Laser Coagulation for Twin-to-Twin Transfusion Syndrome is challenging for anterior placenta due to the rigidity of current tools. The capacity to keep entry port forces minimal is critical for this procedure, as is optimal coagulation distance and orientation. This work introduces technological tools to this end.

Methods A novel fetoscope is presented with a rigid shaft and a flexible steerable segment at the distal end. The steerable segment can bend up to 90° even when loaded with a laser fiber. An artificial pneumatic muscle makes such acute bending possible while allowing for a low-weight and disposable device.

Results The flexible fetoscope was validated in a custom-made phantom model to measure visual range and coagulation efficacy. The flexible fetoscope shows promising results when compared to a clinical rigid curved fetoscope to reach anterior targets. The new fetoscope was then evaluated in-vivo (pregnant ewe) where it successfully coagulated placental vasculature.

Conclusion The flexible fetoscope improved the ability to achieve optimal coagulation angle and distance on anteriorly located targets. The fetoscope also showed the potential to lead fetoscopic laser coagulation and other fetal surgical procedures toward safer and more effective interventions.

Keywords Twin-to-twin transfusion syndrome · Flexible fetoscope · Artificial muscle · Steerable endoscopes · In-vivo validation.

M. A. Ahmad · M. Ourak · D. Wenmaekers · E. Vander Poorten
KU Leuven, Department of Mechanical Engineering, Leuven, Belgium
E-mail: mirzaawais.ahmad@kuleuven.be
ORCID: 0000-0002-3975-012X

T. Vercauteren · Sebastien Ourselin
Department of Imaging and Biomedical Engineering, Kings College, London, United Kingdom

I. Valenzuela · D. Basurto · J. Deprest
UZ Leuven, Department of Obstetrics and Gynaecology, Leuven, Belgium

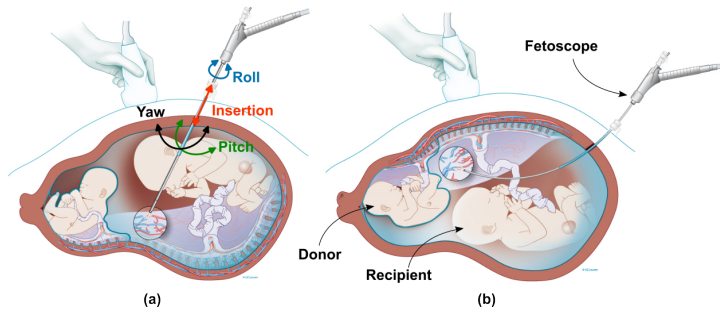


Fig. 1: Fetoscopic Laser Coagulation (FLC) for TTTS: **(a)** a straight rigid fetoscope is used in case of posterior placenta **(b)** a curved rigid fetoscope is typically used for anterior placenta.

1 Introduction

10% of monochorionic twins experience twin-to-twin transfusion syndrome (TTTS) due to a specific anastomotic pattern, causing imbalanced blood flow [14]. If left untreated, the mortality can go up to 80%, due to extremely premature delivery or in utero death [6]. The standard of care today is fetoscopic laser coagulation (FLC), typically done under local anesthesia and sono-endoscopic visualization. The fetoscopes house a working channel for the laser fiber, a channel for water irrigation, an image conduit (fiber), and illumination fibers. The instrument is inserted into the amniotic sac through a cannula in a placenta-free area (figure 1). The surgeon identifies the key landmarks such as umbilical cord insertions, the dividing membrane, and placental borders; oversees the chorionic plate, and then maps and coagulates all the intertwin anastomoses [21].

Effective coagulation requires complete visualization of the vascular equator, identification of the anastomoses, ideally a perpendicular angle, and an optimal distance of the laser fiber to the anastomoses. The surgeon assumes effective obliteration of the blood flow through the anastomosis, by visual confirmation of complete and persisting blanching of the targeted vessels (figure 2). Touching the vessels or overdosing the laser energy can cause vessel perforation, leading to potentially lethal hemorrhage for the fetus(es) [8]. Effective lasering may be hindered by fetal structures, blood or debris-stained fluid, and placental or maternal anatomical limitations not permitting appropriate cannula insertion and optimal orientation of the fetoscope. This increases the risk of missing anastomoses, resorting to unselective coagulation of normal vessels, or insufficient obliteration. Incomplete dichorionization [13] may lead to persisting or recurrent transfusion and/or single or double fetal death [15, 19].

For a completely anterior placenta, optimal working conditions are not present (figure 1b). A variety of techniques can then facilitate the procedure. One is the use of a 30° rod lens endoscope with a deflecting mechanism for the fiber [10]. Another trick is to advance the cannula against the placenta so that one could somehow tumble the placenta in front of the cannula and coagulate from within the cannula [12]. One could consider a mini-laparotomy for fundal access, or a laparoscopy and use a posterior entry. Because of invasiveness, mini-laparotomy and posterior

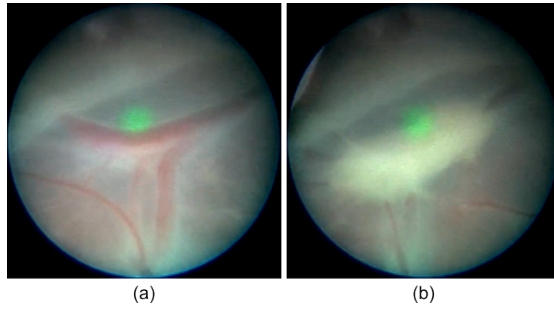


Fig. 2: Visual confirmation of coagulation of vessels. **(a)** shows a vessel before coagulation. **(b)** shows the vessel with persisting blanching indicating coagulation. The green dot is a low-energy laser further referred to as "aiming reticle".

laparoscopy have not gained much acceptance [6, 16]. Usually, a curved fetoscope is used to increase visual coverage of the placental surface and lasering angle (figure 1b). Sun et al. [20] and Yao et al. [22] proposed fetoscopes with flexible tool shafts. According to our experience with using the flexible uretero-roscope (Karl Storz FLEXX2), this leads to usability issues and difficulty to keep the flexible tool shaft in a stable position when treating TTTS.

The limited dexterity of classical rigid fetoscopes can increase the risk of iatrogenic Preterm Premature Rupture of Membranes (iPPROM)[3] due to large forces required to gain visual coverage. To address these challenges, we propose a flexible fetoscope with a short distal tip that is actuated using pneumatic artificial muscle. The proposed fetoscope retains the intuitiveness, stability, and hand-eye coordination of the rigid fetoscope while increasing the visual range and allowing to bend the clinical laser fiber up to 90° , without causing fatigue to the surgeon's hands. The purpose of this study is to present the development of this novel flexible fetoscope for fetal surgery.

2 Methods

Current tools for fetoscopic laser coagulation have limitations that don't meet clinical needs. Ahmad et al. [2] established that adding one extra degree of freedom at the distal tip in the form of a flexible steerable segment enables the fetoscope to more easily achieve a desired orientation and distance even for anteriorly placed placentas. The proposed fetoscope's functional requirements, design parameters, and development are discussed next based on this concept.

2.1 Design and development

Table 1 lists 10 specifications for a functional steerable flexible fetoscope. This subsection elaborates on the design choices made to meet these requirements. A typical endoscopic instrument has two parts, the handle, and the tool shaft. In our design, all the interface and the actuation components are housed inside

Feature	Value
Outer Diameter (OD)	10.5 Fr.
Rigid Length (l_1)	27 cm
Flexible Length (l_2)	3 cm
Bending Angle	90°
Functionality	Water irrigation, illumination, imaging, water tightness
Working Channel	4 Fr.
Handle	Ergonomic
Total Weight	$\leq 250g$ i.e. the rigid scope's weight
Interface	Intuitive steering control
Actuation	Computer controlled, bandwidth $\geq 1Hz$, 6N pulling force

Table 1: Values and methods forming the key requirements.

the handle. The connection to the tool shaft entails a mechanical, optical, and electronic connection to the distal components.

2.1.1 Handle

The instrument handle's shape and ergonomics are important for comfortable use over a period of 15 to 30 minutes. A design thinking approach [4] was taken to ensure ease of use and accessibility of the device. A mock instrument handle with a configurable shape (e.g. straight vs. pistol grip), buttons, and slider locations was 3D printed. Expert surgeons tested this handle in a TTTS mixed reality simulator [11] and concluded that a pistol grip was ideal. A slider, positioned under the surgeon's thumb, was found to be intuitive to control the bending angle, allowing single-hand operation. To inform the surgeon about the current tip curvature, an avatar of the distal flexible tip is displayed in the corner of the screen that shows the fetoscopic image (figure 5). Electrical and air connections are located at the handle's base, designed for easy disconnection, enabling portability and sterile packaging of the fetoscope.

2.1.2 Actuation method

A lever/knob and tendon (cable) based actuation used in typical flexible endoscopes requires a two-hand operation and can be tiring for prolonged use (as is here the case). In our flexible fetoscope, a required 6N pulling force was measured to achieve a 90° flexion with a high-power laser fiber inside. To counter the surgeon's fatigue, this work introduces an active artificial muscle into the handle that pulls the tendons when pressurized with air. The artificial muscles provide a high power-to-weight ratio and affordability, hence, in principle, the fetoscope could be made disposable. The controller uses the slider position to determine the required air pressure for a target bending angle.




Fig. 3: Prototype of the flexible fetoscope.

2.1.3 Tool shaft

The tool shaft has a straight rigid segment ($l_1=27\text{cm}$) and a distal flexible backbone ($l_2=3\text{cm}$). The overall length is similar to that of the clinical rigid fetoscope. It is important to have the length of the bendable segment as short as possible while maintaining large bending angles (up to 90°) such that it is possible to get a good visualization of the anastomoses at placental boundaries even when the cannulation is done very close to said boundaries. The tool shaft is made out of a single nickel-titanium (NiTi) tube (O.D. 3.4 mm and I.D. 2.9 mm). The flexible segment is created by laser cutting notches with a pattern that Devreker et al. [7] optimized to increased stiffness yet allowing maximum bending angles over a short segment.

2.1.4 Camera

Due to a flexible distal tip, a chip-on-tip camera that transports the image data digitally over flexible electrical cables was chosen. It is an OVM6946 CMOS camera sensor produced by OmniVision™. The camera has $1\times 1\text{mm}$ footprint and 400×400 pixels resolution. Fetal surgeons tested the camera's image and color quality in an underwater environment and found it satisfactory.

2.1.5 Illumination

A pair of flexible optical fibers are embedded into the distal tip. These fibers are connected to an external light source. A chip-on-tip LED light source could also be considered a suitable alternative. The distal tip itself is made in-house by encasing all the components (camera, optical fibers, working channel, pulling cables) in a medical-grade clear epoxy (figure 3). This allows maximum illumination of the in-utero environment through the optical fibers.

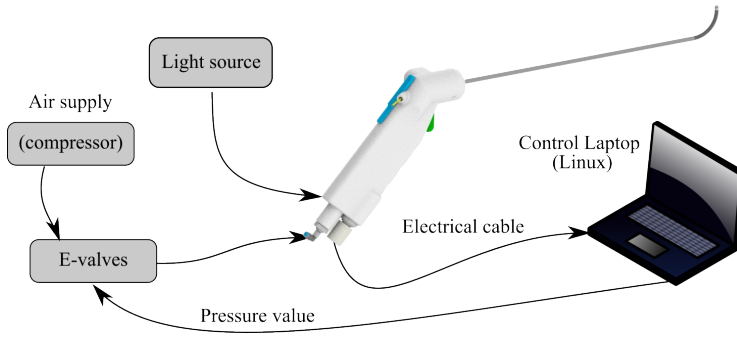


Fig. 4: The control loop of the flexible fetoscope. The electrical signals from the scope go to a laptop that displays the fetoscopic image and sends required air pressure values to the electro-valves to bend the flexible tip.

2.1.6 Working Channel

A 4 Fr. working channel is embedded in the instrument. High-power laser fibers used to perform FLC typically range from 0.4 mm to 1 mm in diameter. The remaining space in the working channel is used for water irrigation in order to keep the fiber tip clean from debris.

2.1.7 Water tightness

To ensure patient and instrument safety, the instrument and especially the distal tool shaft must be waterproof. The epoxy-encased distal tip is glued to the tool shaft using medical-grade flexible CA glue (Loctite™ 4902 FL) which also acts as a sealant. A medical-grade rubber sleeve covers this joint and the flexible segment notches to seal the distal tip.

2.1.8 Control

Actuation based on an artificial muscle and tendon is prone to non-linearities (hysteresis). To ensure a stable, repetitive and precise control, compensation of the non-linearities was included. A modified generalized Prandtl-Ishlinskii model [17] was implemented and used in a feedforward fashion to compensate for the hysteresis. The controller is implemented in C++, in a computer with a 2.90 GHz i7 core Intel CPU with a Linux distribution. The general control loop setup is depicted in figure 4.

3 Validation and Evaluation

Keeping the procedural steps in mind, a silicon phantom model was designed to validate the fetoscope. The fetoscope was also evaluated in an in-vivo model to measure the feasibility and efficacy in a real clinical environment.

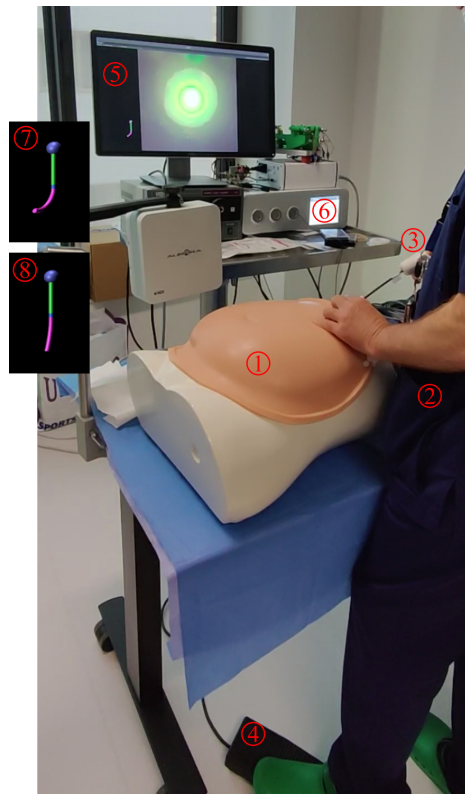


Fig. 5: The experimental setup for the silicon phantom trials. (1) universal abdominal model, (2) surgeon, (3) instrument, (4) laser activation pedal, (5) fetoscopic display, (6) light source, (7) digital avatar of distal flexible tip bent to $\sim 90^\circ$, (8) digital avatar of distal flexible tip unbent to $\sim 0^\circ$. The video is available as supporting material.

3.1 Silicon phantom trials

In the experimental setup (figure 5), a universal maternal abdomen model (MAM) [18] is placed on the table in front of the surgeon. A pedal under surgeon's foot activates the laser and the fetoscopic display is placed in front of the surgeon's torso at eye height. Figure 6 shows the silicon-based placenta phantom, which is placed inside the MAM. The phantom was modeled with visually realistic vessels using 3D sculpting tools in the Blender 3D software [5] and its mold was 3D printed (stl files are available as supporting material).

The phantom was placed inside the MAM such that one side is plugged into the posterior (figure 6a, orange), and the other side curves around the fundal and then towards the anterior side (figure 6a, red). Eleven alphabetical targets, 3 in each row with each row becoming increasingly anterior, were placed on the anterior side of the placenta. The most anterior row contains only 2 targets. The cannula

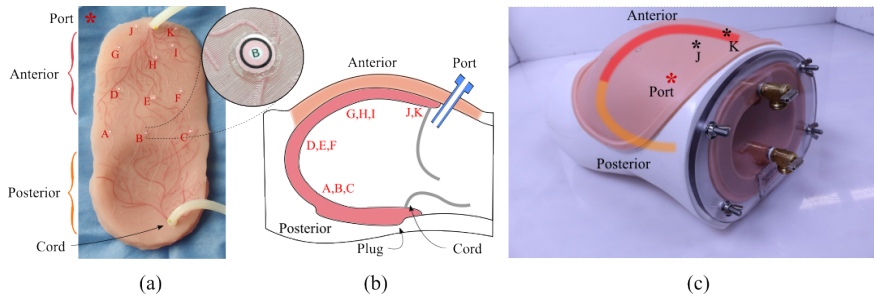


Fig. 6: The silicone phantom with targets is positioned within the maternal abdomen; the entry ports are marked with an '*'; (a) shows the phantom with targets, (b) provides a cross-sectional diagram of the maternal abdomen, demonstrating the location of the phantom and targets in relation to the entry port; (a) and (c) show that the port is a few centimeters away from target 'J'.

'port' was placed 4-5 centimeters away from the placental border on the anterior side.

Ten fetal surgeons including four expert surgeons with multiple years of experience in human interventions and six trainees, participated in the experiments. In each trial, the surgeon used a standard rigid curved fetoscope followed by the flexible fetoscope. With a one-week gap, participants had a second trial. The sequence was not randomized, as in a clinical scenario, the surgeons would always explore first with a conventional rigid instrument (straight or curved), before moving on to the flexible fetoscope for challenging targets. The measured outcomes of the experiment were: visibility range, time, coagulation feasibility based on orientation and distance, accuracy, and usability based on NASA task load index (TLX) [9]. NASA TLX is a subjective rating scale that assesses perceived workload across six dimensions: mental and physical and temporal demand, performance, effort and frustration. Users rate each dimension on a scale of 0 to 100, with higher scores indicating a greater workload.

Participants received a tutorial on how to use the flexible fetoscope, safety instructions, expected outcomes, and the performance scoring criteria (figure 7). A low-power laser is used to mimic the high-power therapeutic laser with the same clinical laser fiber. This laser at a lower intensity simulates aiming reticle, while pressing the pedal produces an audio cue (beep sound) and a visual cue (increased intensity and size of the reticle) to mimic laser activation. Matching the size of the target's inner white dot with the aiming reticle would entail a perfect score (figure 7). The distance and angle with respect to the target could be inferred from the shape and the size of the aiming reticle or the target's black boundary.

Scoring protocol: in each trial, the fetoscopic view was recorded in video format. Each video was post-processed by an engineer with the following protocol:

- At each target, the frame just before laser activation is kept.
- Angle and distance can be objectively estimated in this frame using a deep learning model trained to estimate the distance and orientation of the placental surface with respect to the camera. The employed model is described by Ahmad et al [1].

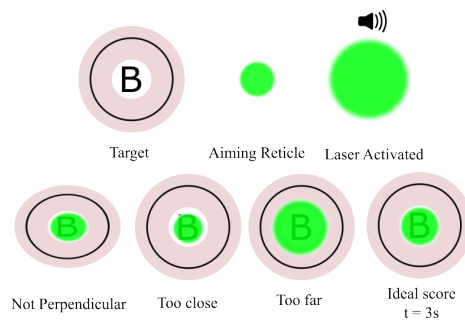


Fig. 7: The scoring criteria of coagulation targets based on the laser aiming reticle.

- Laser activation duration is then measured from the video.
- Coagulation accuracy is scored subjectively from the video sequence of each target as follows:
 - While laser is activated:
 - 0, if laser remains inside the black boundary
 - 1, if laser crosses the black boundary
 - 2, if laser crosses the pink boundary area
 - 3, inadvertent firing of laser at non-targets

3.2 Animal trials

For in-vivo evaluation, a pregnant Swifter ewe with uterine horns from a certified breeder was used at gestational age of 100 days. One horn was used with an expert surgeon while the second horn with a novice. The horn is exteriorized after midline laparotomy. The horn wall thickness of a ewe is not comparable to that of humans, so an oval dome was 3D printed to contain the horn in a fixed standard form (figure 8). At one end of the dome, a thick silicon layer was attached to mimic the thickness of the human uterus. The ceiling of the dome represents an anteriorly located placenta. A 12 Fr. port is inserted through the dome and fixed to the horn. The measured outcomes of the animal trial were: number of placentomes counted using each fetoscope, coagulation feasibility and efficacy (assessed visually), and usability based on NASA TLX.

First, a rigid curved fetoscope is introduced into the uterine dome and the surgeon counts the number of placentomes that were visible from the proximal to the distal end. And then performs coagulation of vessels using the clinical laser if the distance and angle from the placentome are suitable on the right side of the horn. Then, the same exercise is carried out using the flexible fetoscope, but on the left side of the horn. In the end, the ewe is euthanized using 140 mg/kg pentobarbital and the uterus is deflated and placentomes are harvested for visual assessment.

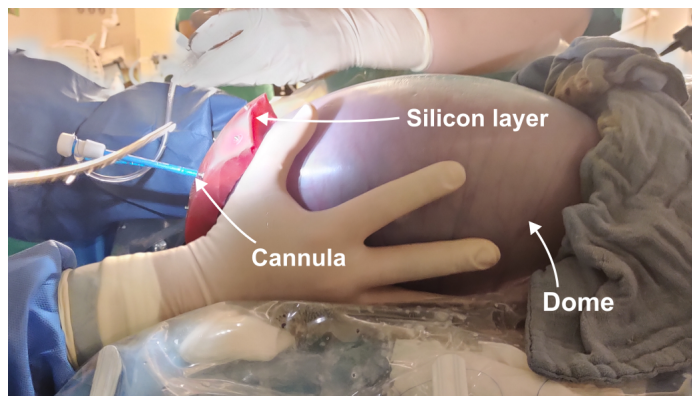


Fig. 8: The uterine horn is exteriorized, placed in the plastic dome to stabilize the shape and filled with warm saline to fill the shape of the dome. A cannula is inserted through the silicon layer at the left end.

4 Results

NASA TLX scores from the phantom trials are presented in figures 9 and 10, categorized by participant's experience. Statistical significance is shown through unpaired t-tests on each category. Figure 11 shows a heat map of the scores computed for the coagulation performance criteria, with each square representing a target on the placenta (A-K). The top right corner of each square indicates the average of the computed scores over all trials. Figure 12 shows the fetoscopic view of each target from both the rigid and flexible fetoscopes. As the targets become more anterior, the fetoscopic view becomes more off-target in case of the rigid scope, hence making appropriate visualization and coagulation impossible.

Figure 13 shows the Nasa TLX scores from the animal trial, with data points from 2 surgeons; an expert and a novice. Figure 14 shows the ultrasound images from the animal trial.

5 Discussion

Figure 9 and 10 show that both expert and novice surgeons assessed the flexible fetoscope as having slightly less mental demand than the rigid fetoscope. Although the medians of both scopes are on the higher side, a significant difference in mental demand was not observed ($p = 0.83$). Regarding physical demand and effort, both the experts and the novices rated the rigid scope higher (worse) than the flexible fetoscope. This indicates that the participants felt less compelled to exert large forces while using the flexible fetoscope, hence lowering forces on the patient's incision site. This was one of the motivating factors for the development of this instrument as large forces on the port may lead to preterm birth [3]. Less physical effort from the surgeons also indicates improved ergonomic user experience.

Significant differences were found in scores for the performance category ($p < 0.001$). The rigid scope is rated poorly by both experts and novices meanwhile the flexible fetoscope's score is close to perfect (0). This also becomes evident with

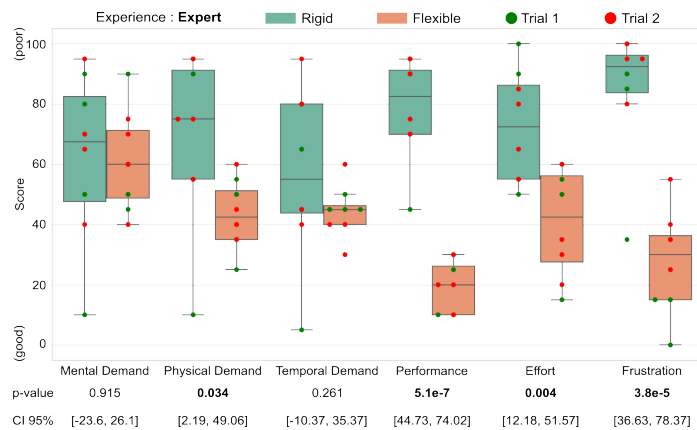


Fig. 9: NASA TLX scores of in-silico trials of expert surgeons. Bottom two rows display the p-value and CI95% of an un-paired t-test.

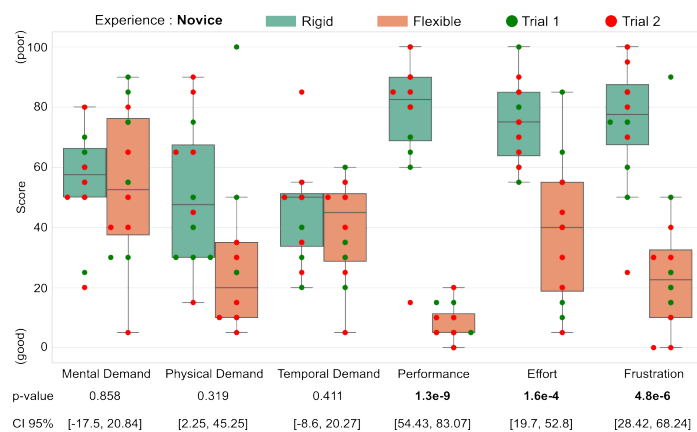


Fig. 10: NASA TLX scores of in-silico trials of novice surgeons. Bottom two rows display the p-value and CI95% of an un-paired t-test.

the comparison of the scores of each coagulation target in figure 11 and 12. The rigid fetoscope was found unable to visualize some of the anteriorly placed targets, hence leading to missed anastomoses and coagulation. Figure 12 also shows that in the case of targets G, H, I, J, and K it is almost impossible to even identify the target due to extreme lateral view. Lastly, both the experts and the novices scored lower frustration levels for the flexible fetoscope indicating a smoother surgical experience. As participants were not given a strict time constraint to finish the task, this may explain very similar medians observed for the temporal demand in the case of both rigid and flexible fetoscope.

Figure 11 shows that expert surgeons and novices skipped some targets when using the rigid fetoscope due to their difficult to visualize location. Both the rigid and flexible fetoscopes performed well on targets ABC, but the error values were slightly higher for the flexible fetoscope. One explanation could be that partic-

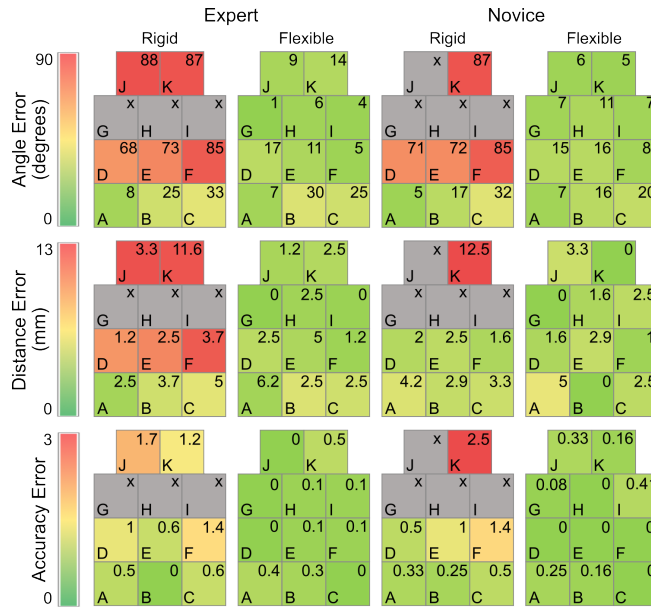


Fig. 11: Heat map of coagulation scores (angle, distance, and accuracy) given to each target location. Value 'x' (grey color) represents the unavailability of data, as some targets were skipped in all trials due to their difficult-to-reach location.

ipants did not utilize the steerability of the flexible tip for these targets as the conditions were still workable. From row DEF, the difference in performance of both fetoscopes starts to become clear. With rigid fetoscope averaging at 76° for angle error and flexible fetoscope averaging at 12° . For more anteriorly placed rows, GHI and JK it becomes more evident that the performance of the flexible fetoscope is superior to that of rigid fetoscope and the latter even fails to visualize most of the targets, yet flexible fetoscope provides an optimal view with error for GHI and JK averaging at 7° and 8.5° respectively. A similar trend of improvement can be observed in the distance errors and the accuracy scores in favour of flexible fetoscope.

Figure 14, shows the ultrasound images of coagulation of placentomes in the uterine horn. A placentome close to the port insertion and at an anterior location was chosen to show the feasibility of flexible fetoscope in an in-vivo environment and its efficacy with a difficult target. The rigid fetoscope (fig. 14a) is unable to achieve an optimal angle with respect to the target surface (placentome peak) whereas the flexible fetoscope (fig. 14b) could.

Three early prototypes were developed and then refined into two final prototypes for the experiments. The distal epoxy bonding with the tendon cable was enhanced in the final version, resulting in its survival for more than 15 trials (despite targeting a disposable device). During the animal trial, it was observed that the image from the flexible fetoscope was over-saturated due to the reflections of the high-power clinical laser (wavelength = $910nm$). Reason being that the CMOS camera chip did not come equipped with appropriate infrared filters.

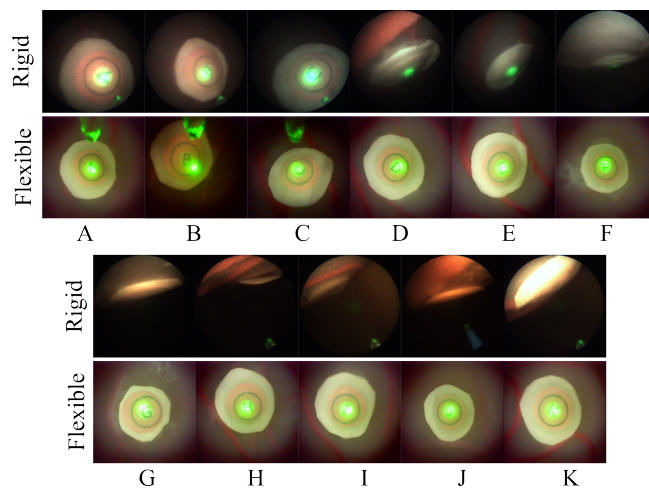


Fig. 12: Fetoscopic view of each target from both rigid and flexible fetoscope. Notice how targets "G" to "K" cannot be seen with the rigid fetoscope due to difficult viewing angle.

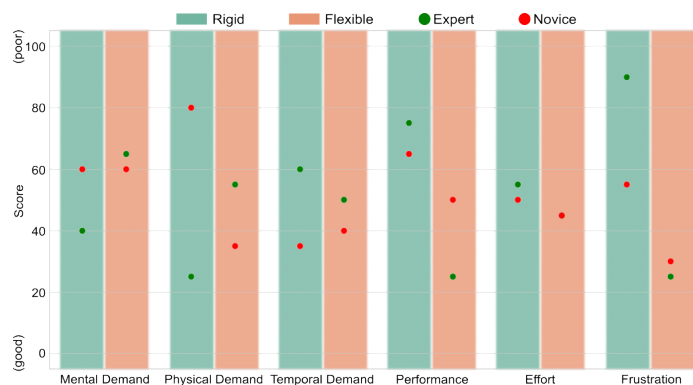


Fig. 13: NASA TLX scores of animal trial. The ewe had two uterine horns and fetoscopy was performed by an expert surgeon followed by a novice surgeon.

Having a permanent reliable image is crucial to visually assess the coagulation efficacy. This problem was solved by adding an infrared glass filter in front of the CMOS camera. It was also discovered that recently commercially available flexible endoscopes (Karl Storz FLEX-X^C and FLEX-X^{C1}), have the ability to filter out the wavelengths used in FLC. An ex-vivo experiment was conducted with our flexible fetoscope with infrared filter and commercially available endoscopes (with chip-on-tip imaging) to coagulate biological material in water bucket, and the image while lasering was found not to be saturated. In conclusion, we have successfully developed an ergonomic flexible fetoscope with high-quality imaging and full functionality, enabling surgeons to reach challenging anastomosis targets under real clinical conditions.

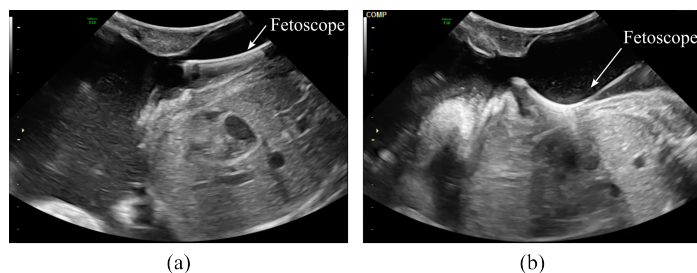


Fig. 14: Ultrasound images from animal trial. (a) shows the rigid fetoscope approaching an anterior placentome for coagulation. (b) shows the flexible fetoscope approaching an anterior placentome.

6 Conclusion

This work presents the development of a novel fetoscope with a distal flexible tip, actuated by an artificial muscle. The artificial muscle allows; fatigue-free operation, bending of the tip more than a conventional flexible instrument with a laser fiber inside, and an instrument with a short distal flexible segment. The shorter tip facilitates port insertion closer to the placenta boundary and achieves optimal lasering angles and distances, requiring minimal workspace in a space-critical environment. The instrument was validated in a silicon-based phantom model with 10 surgeons (4 experts) and in-vivo feasibility was evaluated in an ewe model. The instrument was able to achieve better performance when compared to a rigid curved fetoscope on anterior targets in terms of perpendicularity, optimal distance, and accuracy.

In the usability assessment through NASA-TLX, users rated the performance of the flexible fetoscope significantly better than that of the rigid fetoscope. Although the instrument is designed for FLC, it may be used for other fetoscopic applications such as Fetoscopic Tracheal Occlusion (FETO) to treat Congenital Diaphragmatic Hernia (CDH).

Acknowledgements M.A.Ahmad is supported by Erasmus Mundus FetalMed PhD Program. This work received funding from the FLEXFET project (3E200384), Wellcome [WT101957; 203148/Z/16/Z] and EPSRC [NS/A000027/1; NS/A000049/1]. T. Vercauteren is supported by a Medtronic / Royal Academy of Engineering Research Chair [RCSRF1819/7/34].

Ethical approval

This experiment was approved by the Animal Ethics Committee of the Group Biomedical Sciences of the KU Leuven (P143/2022).

Conflict of Interest

The authors declare that they have no conflict of interest.

Informed Consent

The participant has consented to the submission of the case report to the journal.

References

1. Ahmad, M.A., Ourak, M., Gruijthuijsen, C., Deprest, J., Vercauteren, T., Vander Poorten, E.: Deep learning-based monocular placental pose estimation: towards collaborative robotics in fetoscopy. *International Journal of Computer Assisted Radiology and Surgery* **15**(9), 1561–1571 (2020)
2. Ahmad, M.A., Ourak, M., Gruijthuijsen, C., Legrand, J., Vercauteren, T., Deprest, J., Ourselin, S., Vander Poorten, E.: Design and shared control of a flexible endoscope with autonomous distal tip alignment. In: 2019 19th International Conference on Advanced Robotics (ICAR), pp. 647–653. IEEE (2019)
3. Amberg, B.J., Hodges, R.J., Rodgers, K.A., Crossley, K.J., Hooper, S.B., DeKoninck, P.L.: Why do the fetal membranes rupture early after fetoscopy? a review. *Fetal Diagnosis and Therapy* **48**(7), 493–503 (2021)
4. Brown, T.: Design thinking. *Harvard business review* **86**(6), 84 (2008)
5. Community, B.O.: Blender - a 3D modelling and rendering package. Blender Foundation, Stichting Blender Foundation, Amsterdam (2018). URL <http://www.blender.org>
6. Deprest, J., Van Schoubroeck, D., Van Ballaer, P., Flageole, H., Van Assche, F.A., Vandenberghe, K.: Alternative technique for nd: Yag laser coagulation in twin-to-twin transfusion syndrome with anterior placenta. *Ultrasound in Obstetrics and Gynecology: The Official Journal of the International Society of Ultrasound in Obstetrics and Gynecology* **11**(5), 347–352 (1998)
7. Devreker, A., Rosa, B., Qian, J., Vercauteren, T., Ourselin, S., Vander Poorten, E., Reynaerts, D.: Design and validation of pneumatically actuated fetoscope. In: Proceedings of the 5th Joint Workshop on New Technologies for Computer/Robot Assisted Surgery, pp. 127–129 (2015)
8. Evrard, V.A., Deprest, J.A., Van Ballaer, P., Lerut, T.E., Vandenberghe, K., Brosens, I.A.: Underwater nd: Yag laser coagulation of blood vessels in a rat model. *Fetal diagnosis and therapy* **11**(6), 422–426 (1996)
9. Hart, S.G., Staveland, L.E.: Development of nasa-tlx (task load index): Results of empirical and theoretical research. In: *Advances in psychology*, vol. 52, pp. 139–183. Elsevier (1988)
10. Huber, A., Baschat, A., Bregenzler, T., Diemert, A., Tchirikov, M., Hackelöer, B., Hecher, K.: Laser coagulation of placental anastomoses with a 30° fetoscope in severe mid-trimester twin–twin transfusion syndrome with anterior placenta. *Ultrasound in Obstetrics and Gynecology: The Official Journal of the International Society of Ultrasound in Obstetrics and Gynecology* **31**(4), 412–416 (2008)
11. Javaux, A., Bouget, D., Gruijthuijsen, C., Stoyanov, D., Vercauteren, T., Ourselin, S., Deprest, J., Denis, K., Vander Poorten, E.: A mixed-reality surgical trainer with comprehensive sensing for fetal laser minimally invasive surgery. *International journal of computer assisted radiology and surgery* pp. 1–9 (2018)
12. Klaritsch, P., Albert, K., Van Mieghem, T., Gucciardo, L., Done', E., Bynens, B., Deprest, J.: Instrumental requirements for minimal invasive fetal surgery. *BJOG: An International Journal of Obstetrics & Gynaecology* **116**(2), 188–197 (2009)
13. Lewi, L., Devlieger, R., De Catte, L., Deprest, J.: Twin-twin transfusion syndrome: the good news is; there is still room for improvement... *Acta Obstetrica et Gynecologica Scandinavica* **91**(10), 1131–1133 (2012)
14. Lewi, L., Gucciardo, L., Van Mieghem, T., De Koninck, P., Beck, V., Medek, H., Van Schoubroeck, D., Devlieger, R., De Catte, L., Deprest, J.: Monochorionic diamniotic twin pregnancies: natural history and risk stratification. *Fetal diagnosis and therapy* **27**(3), 121–133 (2010)
15. Lewi, L., Jani, J., Cannie, M., Robyr, R., Ville, Y., Hecher, K., Gratacos, E., Vandecruys, H., Vandecaveye, V., Dymarkowski, S., Deprest, J.: Intertwin anastomoses in monochorionic placentas after fetoscopic laser coagulation for twin-to-twin transfusion syndrome: is there more than meets the eye? *American journal of obstetrics and gynecology* **194**(3), 790–795 (2006)

16. Papanna, R., Johnson, A., Ivey, R., Olutoye, O., Cass, D., Moise, K.: Laparoscopy-assisted fetoscopy for laser surgery in twin–twin transfusion syndrome with anterior placentation. *Ultrasound in Obstetrics and Gynecology: The Official Journal of the International Society of Ultrasound in Obstetrics and Gynecology* **35**(1), 65–70 (2010)
17. Shakiba, S., Ourak, M., Vander Poorten, E., Ayati, M., Yousefi-Koma, A.: Modeling and compensation of asymmetric rate-dependent hysteresis of a miniature pneumatic artificial muscle-based catheter. *Mechanical Systems and Signal Processing* **154**, 107532 (2021)
18. Simulators, S.T.: Universal maternal model, <https://www.surgicaltouch.com/universal-maternal-abdomen>. URL <https://www.surgicaltouch.com/universal-maternal-abdomen>
19. Slaghekke, F., Lewi, L., Middeldorp, J.M., Weingertner, A.S., Klumper, F.J., Dekoninck, P., Devlieger, R., Lanna, M.M., Deprest, J., Favre, R., Oepkes, D., Lopriore, E.: Residual anastomoses in twin-twin transfusion syndrome after laser: the solomon randomized trial. *American Journal of Obstetrics and Gynecology* **211**(3), 285–e1 (2014)
20. Sun, J., Sun, L., Zhong, L.: Flexible fetoscope in the treatment of twin-to-twin transfusion syndrome. *ANZ Journal of Surgery* **91**(11), 2499–2502 (2021)
21. Van Der Veeken, L., Couck, I., Van Der Merwe, J., De Catte, L., Devlieger, R., Deprest, J., Lewi, L.: Laser for twin-to-twin transfusion syndrome: a guide for endoscopic surgeons. *Facts, Views & Vision in Obgyn* **11**(3), 197 (2019)
22. Yao, W., Elangovan, H., Nicolaides, K.: Design of a flexible fetoscopy manipulation system for congenital diaphragmatic hernia. *Medical engineering & physics* **36**(1), 32–38 (2014)