



King's Research Portal

DOI:

[10.1038/s41415-020-2350-8](https://doi.org/10.1038/s41415-020-2350-8)

Document Version

Peer reviewed version

[Link to publication record in King's Research Portal](#)

Citation for published version (APA):

Olley, R. C., Renton, T. F., & Frost, P. (2021). 15-year unique observational study of Intraligamentary-Local-Anaesthesia for posterior mandibular extractions. *British Dental Journal*. <https://doi.org/10.1038/s41415-020-2350-8>

Citing this paper

Please note that where the full-text provided on King's Research Portal is the Author Accepted Manuscript or Post-Print version this may differ from the final Published version. If citing, it is advised that you check and use the publisher's definitive version for pagination, volume/issue, and date of publication details. And where the final published version is provided on the Research Portal, if citing you are again advised to check the publisher's website for any subsequent corrections.

General rights

Copyright and moral rights for the publications made accessible in the Research Portal are retained by the authors and/or other copyright owners and it is a condition of accessing publications that users recognize and abide by the legal requirements associated with these rights.

- Users may download and print one copy of any publication from the Research Portal for the purpose of private study or research.
- You may not further distribute the material or use it for any profit-making activity or commercial gain
- You may freely distribute the URL identifying the publication in the Research Portal

Take down policy

If you believe that this document breaches copyright please contact librarypure@kcl.ac.uk providing details, and we will remove access to the work immediately and investigate your claim.

Title of article

15-year unique observational study of Intraligamentary-Local-Anaesthesia for posterior mandibular extractions

Short Title

ILA for posterior mandibular extractions

Abstract

Introduction Intraligamentary Local Anaesthesia (ILA) with articaine is described as an effective alternative to Inferior Alveolar Nerve Block (IANB) for extraction of posterior teeth in the mandible, with reduced risk of complications.

Aim To investigate ILA with 4% Articaine and conventional syringe as a unique method for providing tooth extractions in the posterior mandible.

Materials and methods All consecutive teeth to be extracted in the posterior mandible were recruited to the study, within exclusion criteria, between 2002 and 2017 in one London NHS and private dental practice. 4% articaine was given by ILA with a conventional syringe slowly at two points lingual and two points buccal adjacent to each tooth. Extraction procedures were all performed flapless. Heavily broken-down teeth (n = 43) were extracted by sectioning of roots, guttering and elevation with luxators using socket preservation techniques. Demographic, quantitative and qualitative data were collected at initial appointments and up to 15 years at review.

Results The median age was 64 years (IQR 17). Teeth extracted included 272 mandibular molars and second premolars, due to periodontal disease (34%), irreversible pulpitis (29%) or posterior tooth fracture (27%). The majority of extractions were second molars (44%), followed by first molars (29%), second premolars (17%) and third molars (10%). Sufficient anaesthesia was achieved within 5 minutes for all extractions. Procedures lasted less than 30 minutes. Patient feedback reported that the extraction using ILA was quicker than expected and painless, with limited anaesthesia of tissues other than the teeth to be extracted. Numeric Rating Scales (NRS) for pain (0-10) were all less than 3. No complications were recorded.

Conclusion The ILA anaesthetic technique is effective for the purpose of a broad range of posterior tooth extractions in the mandible and within certain clinical parameters. It mitigates

risks, including nerve injury and cardiovascular disturbances, associated with repeated IANB. This is the largest study of its kind and is conducted in primary care.

In brief

- Demonstrates that ILA with 4% articaine is for effective for posterior mandibular extractions in many clinical situations;
- Provides information on the technique for ILA in primary dental care, with patient feedback;
- Raises awareness of the techniques for anaesthesia to reduce risk associated with nerve injury.

Keywords

Anaesthesia, Dental; Periodontal Ligament; Tooth Extraction; Anesthesia, Local; Mandible

Manuscript

Introduction

For the purpose of achieving anaesthesia for tooth extraction, a variety of techniques exist¹. Perhaps the most commonly used technique for mandibular posterior tooth extractions is the Inferior-Alveolar-Nerve-Block (IANB)¹. Despite this, there are concerns regarding risks associated with IANB and suggestions have been offered for alternative anaesthetic techniques for extraction of mandibular teeth^{1,2}. In a meta-analysis comparing IANB with an alternative Intraligamentary-Local-Anaesthesia (ILA) technique, unwanted risks from IANB included cardiovascular disturbances and risk of nerve injury (involving paraesthesia or dysesthesia or loss of sensation or taste)³. Considering the relatively small risks of permanent nerve injury⁴, concerns have been expressed in the British Dental Journal, of the possible need to record consent for any procedure involving risk no matter how small, which itself may not be productive⁵. It is suggested that this may alienate patients as well as perhaps increase anxiety and workload⁵. Extrapolation of data from studies suggests the incidence of permanent alveolar or lingual nerve injury as a result of an IANB alone is low, but ranges hugely from 1:26,762 to 1:160, 571⁶. In addition, a reported incidence of dysesthesia or some perception of pain as a result of nerve damage due to IANB in 36% of individuals is worrying⁶. The only means of elimination of this risk is to use an alternative method of anaesthesia, either ILA or Infiltration-Local-Anaesthesia (IFA)¹. In addition, aside from risk, other more commonly reported problems with IANB include greater

anaesthetic latency time, the amount of anaesthetic agent used and the duration of anaesthesia³ or perhaps even more pain on injection than alternative methods of anaesthesia including ILA using specialised pressure sensitive syringes⁷. Other studies have also reported a need for supplemental anaesthesia, following IANB, in order to achieve sufficient pulpal anaesthesia⁸ or anaesthesia to extract mandibular posterior teeth⁹.

An alternative, IFA, has reported lower efficacy results compared with IANB for posterior mandibular extractions¹. In one study, only just over half of patients obtained anaesthesia for extraction of mandibular posterior teeth with IFA, often requiring supplementary IANB or additional IFA¹⁰. Other work in primary care compared IFA with IANB (using 4% articaine) and showed that IFA produced anaesthesia in only 35% of cases¹¹. Another article confirms these findings¹². In summary, the effectiveness of IFA for posterior mandibular extractions is questionable¹³. An alternative approach to anaesthesia is ILA. ILA, in similarity to IANB, is a long established technique, but it has poor uptake in dental practice¹⁴. This may be due to the additional equipment required, including intraligamentary syringes and/or operator inexperience when using the ILA technique¹⁴. In addition, there are limited available studies to demonstrate the effectiveness of anaesthesia with ILA for extraction of mandibular posterior teeth³. Of the studies that do exist, two were conducted in a hospital setting using purpose made intraligamentary syringes for tooth extractions^{7,15} and other work involved routine restorations¹⁶. There are no studies conducted in primary care to investigate ILA for mandibular posterior extractions using conventional syringes and careful operative technique with small anaesthetic doses, without the need for additional equipment, as discussed in a recent review¹.

For the choice of anaesthetic, articaine is becoming increasingly popular in dental practice with limited possible side effects, despite anecdotal concerns over its possible neurotoxicity, osteonecrosis or paraesthesia¹⁷. There are no reports of these complications, and research in adults shows greater effectiveness of 4% articaine over 2% lidocaine for the purpose of tooth extractions¹⁸. In addition, the concentration of adrenaline has little bearing on effectiveness¹⁹, with 1: 200,000 perhaps causing less sympathomimetic side effects²⁰. The aim of this article was therefore to observe ILA administration (using 4% articaine and 1:200,000 adrenaline) as a method of anaesthesia for the extraction of mandibular posterior teeth (first, second and third molars and second premolars) in a primary dental care using a conventional syringe as part of an evaluation of service study.

Materials and methods

This service evaluation took place from 2002. The setting was one mixed NHS/private dental practice in South London. The operator had received clinical verifiable training in the use of the ILA technique. Data collection was based on the FGDP UK national research competencies, updated in 2007²¹. As operator experience has a bearing on ILA¹⁴, the same operator undertook all ILA and tooth extractions. The evaluation continued until completion of a sample size of at least 194 patients in 2017, which compares with the sample size of two existing published prospective studies investigating extraction of posterior teeth using ILA in hospital settings^{7,15}.

All adult subjects (over 17 years old) who required extraction of at least one permanent mandibular posterior tooth (first, second or third molar or second premolar) under local anaesthesia, were recruited to the study consecutively. For compliance of clinical consent, it was explained to the patient that we would be using ILA and 4% articaine (1:200,000 adrenaline), but IANB was offered as an alternative method of anaesthesia. The relative risks of both ILA and IANB methods were explained to the patient. This included a small risk of temporary or ongoing nerve injury (to the tongue, cheek, lip and ipsilateral side of the tongue) or loss of taste following IANB. It was also explained that additional anaesthesia may be required, and the period of anaesthesia was likely to be extended using IANB methods. Risks of ILA included perhaps more pain on injection using the conventional needle and, if anaesthesia were unsuccessful, additional injections to achieve sufficient anaesthesia prior to the extraction. If patients opted for IANB or requested discontinuation of ILA or if ILA were unsuccessful, then the extraction would be performed using IANB. If this occurred, it was recorded, and they would be automatically removed from the study.

Exclusion criteria included deciduous teeth, patients wishing to have sedation or alternative methods of anaesthesia as mentioned previously, facial swelling or significant soft tissue swellings adjacent the injection sites, allergies to articaine or patients requiring surgical extractions involving soft tissue flaps. Patients with head and neck cancer with significant xerostomia and those taking antibiotics were also excluded from the study.

All patients in the study were regular attendees enrolled on a hygiene regime involving six monthly visits to the hygienist and annual visits to the dentist (or more regular as appropriate if high risk of dental disease). Patients with a history of cardiovascular disease including hypertension, heart failure, valvular heart disease, stroke and patients taking anticoagulants were included in the study. For patients taking anticoagulants, INR

checked within 24 hours was less than 4 for extractions in primary care. If INR were greater than 4, patients were referred to oral surgery secondary care and excluded from this study.

Analgesics were prescribed pre-operatively (2x 500mg Paracetamol). The technique used by the operator for providing ILA is published¹. No preoperative anaesthetic was used. Up to 1.8mL (approximately 80% of a 2.2mL cartridge) of 4% Articaine Hydrochloride (with 1:200,000 adrenaline) (Septanest, 1:200,000, Septodont[®]) was given gently into the periodontal ligament of the tooth to be extracted. In general, the amount of anaesthetic used was much lower than 1.8mL. A conventional syringe with pen grip (Septodont[®]) and short 30-gauge needle (Septoject, Septodont[®]) was used. The needle bevel was facing toward the tooth root. The 1.8mL was spread over two sites buccal and two sites lingual per tooth until blanching of the mucosa appeared circumferentially. These four sites were consistently mesio- and disto- lingual, and mesio- and disto-buccal. Figures 1 and 2 show an intra-oral photograph and diagram respectively of ILA. Gentle pressure was used, and the ILA technique was therefore performed slowly, over a period of up to 5 minutes per tooth. High volume suction was used whilst administering ILA.

The teeth were probed with a disposable dental explorer within 5 minutes of injections at buccal, lingual, mesial and distal sites. Then, soft tissue dissection occurred using luxators to gently dissect the gingiva away from the tooth and place the forceps. The tooth was then extracted. For heavily broken-down teeth, extraction was achieved flapless using where necessary, tooth sectioning and guttering methods with a tapered diamond bur in order to preserve the alveolar plate and create space for tooth movement. The roots were then elevated using luxators and/or forceps and haemostasis achieved. If no bleeding was present, the operator run a periodontal probe (DEHP Probe Perio Williams, 14w, Henry Schein[®]) gently over the periosteum to create bleeding until the socket filled up and a stable blood clot formed. For patients requiring more than one extraction, the ILA procedure was then repeated for the next tooth to be extracted in the arch.

The date of extraction, tooth/teeth to be extracted, reasons for extraction and badly broken-down teeth requiring tooth sectioning and guttering techniques were recorded. Demographic data were collected from each patient including date of birth, gender and ethnicity. Patients were then reviewed 1 week, and 2 months post operatively, and again at least annually up to 15 years until 2017 as part of their routine dentist visits. At 1 week and 2 month follow up appointments, all patients were asked 1) Quantitative pain scores at the extraction appointment, where 1 represents low/no pain and 10 most pain using a Numeric Rating Scale (NRS), which is a straightforward and valid scale for pain²², and 2) Qualitative comments. For qualitative comments, patients were asked the ease of having the

anaesthetic and extraction procedure (if this was their first dental extraction) or how the anaesthetic and extraction procedure differed from their experiences of other dental extractions in the past.

At subsequent annual dental follow up appointments, any further patient qualitative comments concerning extraction appointments, reported pain or changes in sensation within the lips or tongue and changes to taste were recorded in the clinical notes. Consent for anonymised quotes were obtained. Qualitative data were categorized into groups to provide a theoretical understanding.

Results

In total, by 2017, 272 mandibular posterior teeth were extracted in 254 patients with a median age 64 years (IQR 17 years). Ethnicities were Caucasian (99%, n = 269) or mixed race/black (1%, n = 3). Approximately half were female (55%, n = 150). A total of 21 patients were not included following the exclusion criteria.

All teeth were extracted using the ILA technique and included 44% (n = 119) second molars, 29% (n = 79) first molars, 17% (n = 46) second premolars and 10% (n = 28) third molars as shown in figure 3. The proportion of overall teeth extracted using tooth sectioning and guttering was 16% (n = 43), using flapless surgery. No patients declined ILA.

Most of the teeth were extracted due to periodontal disease (34%, n = 92), periapical infection following irreversible pulpitis (29%, n = 80) or posterior tooth fracture in cases with insufficient tooth structure for restoration (27%, n = 73). Others were extracted for orthodontic purposes or to make space for prostheses (10%, n = 27).

Anaesthesia was achieved in all cases within five minutes. Sufficient anaesthesia was obtained in each appointment for up to thirty minutes to enable successful extraction of a single tooth without further anaesthetic supplementation in any patients.

All extractions healed successfully without complications and patients were followed up annually for a minimum of one year, up to 15 years. There was no increase in adverse events or post-operative symptoms (no paraesthesia, dysesthesia, loss of sensation, changes in taste, or temporary symptoms such as nausea or dizziness) observed clinically or reported by patients. There were no medical emergencies.

All patients tolerated extractions with ILA. NRS pain scores at the extraction appointment were all less than three representing little or no pain. Patients did not record an NRS of 0, whereas 61% (n = 155) reported a score of 1 and 39% (n = 99) reported a score

of 2. Qualitative data including comments by patients regarding the extraction and anaesthetic were positive towards ILA. Commonly reported statements included; “the extraction was not painful”, the procedure “was painless and far quicker than they imagined”; “I was advised to take analgesics thirty minutes before the extraction. The numbness from the injection had worn off after forty-five minutes and by that time the analgesic had taken over”; “I was left with no numbness after three or four hours unlike when your colleague injected me with a lower jaw injection (nerve block) when the numbness lasted at least four hours”. In addition, some patients reported that the mouth “did not feel as numb” as when they had had previous extractions in the past. Some patients also reported that the ILA “had an unpleasant taste” but did not request discontinuation of ILA.

Patients with a history of cardiovascular disease including hypertension, heart failure, valvular heart disease, stroke and patients taking anticoagulants included 63% of individuals (n = 160).

Discussion

ILA given with a conventional syringe and 4% articaine (1: 200,000 adrenaline) was effective for the purpose of all consecutive extractions of mandibular posterior teeth, without need for alternative anaesthetic techniques or reported complications. This is the largest study of its kind and was conducted in primary dental care.

Extractions included first, second and third mandibular molars and second mandibular premolars. The majority of tooth extractions were mandibular second molars. Common reasons for extractions were periodontal disease, irreversible pulpitis or posterior tooth fracture. These reasons for tooth extraction are supported in another study of a different sample in dental practice²³. No complications such as infected or dry socket or adverse medical events were noted.

The extraction of teeth with periodontal disease alone may be a weakness of the study. However, extractions for periodontal disease contributed approximately one third of teeth. Almost two thirds of teeth were also extracted due to posterior root fractures with insufficient coronal tooth structure remaining or due to periapical infection following irreversible pulpitis. Furthermore, although ILA is often anecdotally said to be used with caution during endodontic procedures with ‘hot’ pulps, approximately one third of teeth extracted in the present study had irreversible pulpitis and hyperaemic pulps. In all these cases, ILA was successfully administered alone as anaesthetic; it should be noted, that although irreversible pulpitis was present, these teeth were without associated facial swelling or significant soft tissue swellings adjacent the injection sites as per the exclusion criteria. In

addition, almost a fifth of all teeth could not be extracted conventionally and required guttering and tooth sectioning to provide access. The results of the present study therefore demonstrate ILA was effective for a broad range of tooth extractions in a primary dental care setting.

The pain scores provided by patients at the extraction appointment were low, below three with no scores of 0. The difference between a pain score of 1 and 2 is negligible²². The qualitative data showed prescription of pre-operative analgesics as useful to deal with end of anaesthesia following extractions and no patients returned or complained of pain following extraction procedures. In addition to the short anaesthetic time, the reported limited soft tissue anaesthesia associated with ILA reduced the chance of patients biting soft tissues, including their lip or tongue. The duration of anaesthesia and anaesthesia of the tongue following IANB is often not preferred by many patients²⁴, as reported by many patients in the present study. However, some patients reported disadvantages of ILA included the unpleasant taste of the anaesthetic following ILA, which may have leaked more readily into the oral cavity despite high volume suction. However, patients did not decline or request discontinuation of ILA as a result. Despite the taste, it is possible to deliver small doses with ILA, less than 1.8mL, which is often smaller than the dose administered with IANB²⁵. As reported elsewhere²⁵, the authors also found ILA a useful technique for patients with limited opening/trismus and those with severe gag responses. Long term data were collected and no pain or changes in sensation or taste were reported in the subjects enrolled in this study for a minimum follow up time of 1 year, up to 15 years.

Operator skill and experience is reported as important to the success of ILA²⁶ in particular with ensuring that the procedure results in successful anaesthesia delivery directly adjacent to the tooth to be extracted and without substantial pain on delivery of the anaesthetic¹⁴. Important aspects of this are allowing sufficient time to discuss the procedure with the patient and to perform the anaesthesia delivery slowly using a skilful careful technique¹⁴. Forceful injections are associated with more pain²⁷ and may occur with less experience of the procedure. In the present study, the technique was performed slowly with anaesthetic delivery over 5 minutes and the patient was pre-warned of possible pain on injection with ILA. Studies have shown that pain will occur on forcible injection, but this pain is reduced using gentle pressure below 120N using pressure controlled syringe systems⁷, which are more expensive. This study demonstrates that with practice, gentle technique and enabling sufficient time for the ILA procedure, ILA can be used with a conventional syringe in practice.

ILA offers a safe alternative to IANB. Almost two thirds of patients had cardiovascular disease or were taking anti-coagulants (with an INR less than 4). Due to the risk of cardiovascular disturbances with IANB³, ILA may be used as an alternative for extractions in patients taking anti-coagulants, or patients with bleeding diatheses or cardiovascular disease risk³. These patients were not excluded in the present study and no complications arose using ILA. As mentioned previously, ILA also avoids risks, albeit low, of nerve damage associated with alternative anaesthetic techniques including IANB.

Although the need for consent for IANB has been deliberated and, perhaps concerningly, the need for consent for almost any almost procedure performed may then arise¹⁷, the ILA is a safer alternative and consent taking for nerve risks would be mitigated. Moving away from this, it may be suggested that due to the route of administration of anaesthetic with ILA, a lot of solution enters the cancellous bone and reaches the tooth via these spaces. It has therefore been proposed ILA is similar to an intraosseous, as opposed to periodontal, anaesthetic¹ and may in theory deliver more intravascular anaesthetic than, say, IFA. Nevertheless, IFA is unreliable for extraction in the posterior mandible as mentioned previously. Moreover, due to the limited space available for ILA, often less anaesthetic dose is delivered than with alternative IFA or IANB techniques. Although no CVD was found in this study and previous studies report less risk than IANB³, there should nonetheless be an awareness of risk and the technique could be restricted to specific clinical situations such as simple extractions.

The minimal latency and shorter and more controllable duration of ILA compared with techniques such as IANB, as reported in the literature²⁸, is an advantage for extraction procedures in a busy dental practice. The 30-minute appointment duration enabled sufficient time for extraction without supplementary anaesthetic delivery in all cases. This provides a realistic window of time for simple extractions in the posterior mandible. It may offer applications in, for example, socket preservation techniques, which involve limited surgery in preparation for later implant placement²⁹. However, the length of anaesthesia with ILA is considerably less than IANB anaesthetic techniques, which may last up to four hours according the literature³. The IANB may therefore continue to be an advantage for longer procedures such as more complex surgical extractions. Nonetheless, if simpler extraction procedures were to continue slightly beyond the thirty-minute window discussed in this paper and require further anaesthesia, the authors would recommend use of supplemental ILA. This may require multiple tissue injections, although these were not necessary in the present study.

ILA was avoided on teeth with severe soft tissue infection due to the possible risk of bacteraemia as reported in one study conducted albeit in children³⁰. There is a lack of evidence in the literature to support this theory in adult patients, but our exclusion criteria meant ILA was perhaps rightly not used in some patients with severe local infections and swelling. Other disadvantages associated with ILA, from animal studies, report periodontal damage^{31,32}. This may be a contraindication if the tooth in question were anaesthetised for the purposes of its restoration although changes to the ligament are sometimes described as reversible³¹ and are not found to affect long term tooth survival¹⁶. In the present study, any damage to the periodontal ligament using ILA was advantageous and the authors found ILA helped displace the tooth from the socket for the purpose of extraction. ILA may also be contraindicated in situations of ankylosed teeth. Although rare, in these cases, the tooth was referred to an oral surgery secondary care centre due to extraction complexity.

The population age was a median 64 years. As the population ages, this creates pressure on a curative model of healthcare provision in a population with changing oral healthcare needs^{33,34}. Periodontal disease, caries or posterior tooth fracture with limited tooth structure were common reasons for tooth loss in the population of this study. All patients were nonetheless enrolled on a strict oral hygiene regime with at least six-monthly hygienist appointments. The study was conducted in a practice with excellent follow up rates, which enabled long term assessment of all patients, soft tissue healing and long-term restorative planning following extraction.

Conclusion

ILA avoids IANB and provides effective anaesthesia for simple extraction of most posterior mandibular teeth in a general dental practice setting by an experienced operator. The duration of anaesthesia, following up to 1.8mL of 4% articaine (1:200, 000 adrenaline) by ILA, was sufficient for extraction of a single tooth involving minor surgery and socket preserving techniques.

There were no complications or patient dissatisfaction recorded, with low pain scores reported. All patients were reviewed for up to 15 years and no changes in sensation or taste were reported. ILA is relevant to dental care professionals undertaking lower posterior extractions in certain clinical situations and mitigate risks, albeit small, associated with IANB.

Declaration of interests

The authors confirm there are no conflicts of interest

Acknowledgements

The authors wish to acknowledge the support of all nurses, technical and support staff that helped contribute data collection for service evaluation at the Dental Practice.

References

- 1 Olley RC, Renton T FP. Intraligamentary Local Anaesthesia for Posterior Mandibular Extractions. *Dent Update* 2020; **47**: 2013–2016.
- 2 Malamed SF. The periodontal ligament (PDL) injection: an alternative to inferior alveolar nerve block. *Oral Surg Oral Med Oral Pathol* 1982; **53**: 117–121.
- 3 Shabazfar N, Daublander M, Al-Nawas B, Kammerer PW. Periodontal intraligament injection as alternative to inferior alveolar nerve block--meta-analysis of the literature from 1979 to 2012. *Clin Oral Investig* 2014; **18**: 351–358.
- 4 Garlsto GA, Gaffen AS, Lawrence HP, Tenenbaum HC, Haas DA. Occurrence of paresthesia after dental local anesthetic administration in the United States. *J Am Dent Assoc* 2010; **141**: 836–844.
- 5 Mehdizadeh A. Anaesthesia: A sense of balance. *Bdj* 2017; **223**: 746.
- 6 Pogrel MA, Thamby S. Permanent nerve involvement resulting from inferior alveolar nerve blocks. *J Am Dent Assoc* 2000; **131**: 901–907.
- 7 Kammerer PW, Adubae A, Buttchereit I, Thiem DGE, Daublander M, Frerich B. Prospective clinical study comparing intraligamentary anesthesia and inferior alveolar nerve block for extraction of posterior mandibular teeth. *Clin Oral Investig* 2018; **22**: 1469–1475.
- 8 Reitz J, Reader A, Nist R, Beck M, Meyers WJ. Anesthetic efficacy of the intraosseous injection of 0.9 mL of 2% lidocaine (1:100,000 epinephrine) to augment an inferior alveolar nerve block. *Oral Surg Oral Med Oral Pathol Oral Radiol Endod* 1998; **86**: 516–523.
- 9 Kanaa MD, Whitworth JM, Corbett IP, Meechan JG. Articaine buccal infiltration enhances the effectiveness of lidocaine inferior alveolar nerve block. *Int Endod J* 2009; **42**: 238–246.
- 10 Awal DH, Yilmaz Z, Osailan S, Renton T. Articaine-only buccal infiltrations for mandibular molar extractions: an alternative to inferior dental nerve blocks. *Dent*

- Update* 2017; **44**: 838–845.
- 11 Thiem DGE, Schnaith F, Van Aken CME *et al.* Extraction of mandibular premolars and molars: comparison between local infiltration via pressure syringe and inferior alveolar nerve block anesthesia. *Clin Oral Investig* 2018; **22**: 1523–1530.
 - 12 Rayati F, Noruziha A, Jabbarian R. Efficacy of buccal infiltration anaesthesia with articaine for extraction of mandibular molars: a clinical trial. *Br J Oral Maxillofac Surg* 2018; **56**: 607–610.
 - 13 Renton T. Optimal Local Anaesthesia for Dentistry. *Prim Dent J* 2019; **7**: 51–61.
 - 14 Endo T, Gabka J, Taubenheim L. Intraligamentary anesthesia: benefits and limitations. *Quintessence Int* 2008; **39**: e15-25.
 - 15 Pradhan R, Kulkarni D, Shetty L. Evaluation of Efficacy of Intraligamentary Injection Technique for Extraction of Mandibular Teeth-A Prospective Study. *J Clin Diagn Res* 2017; **11**: ZC110–ZC113.
 - 16 Olley RC, Andiappan M, Frost PM. An up to 50-year follow-up of crown and veneer survival in a dental practice. *J Prosthet Dent* 2018; **119**: 935–941.
 - 17 Hopman AJG, Baart JA, Brand HS. Articaine and neurotoxicity - a review. *Br Dent J* 2017; **223**: 501–506.
 - 18 Kanaa MD, Whitworth JM, Corbett IP, Meechan JG. Articaine and lidocaine mandibular buccal infiltration anesthesia: a prospective randomized double-blind cross-over study. *J Endod* 2006; **32**: 296–298.
 - 19 McEntire M, Nusstein J, Drum M, Reader A, Beck M. Anesthetic efficacy of 4% Articaine with 1:100,000 epinephrine versus 4% articaine with 1:200,000 epinephrine as a primary buccal infiltration in the mandibular first molar. *J Endod* 2011; **37**: 450–454.
 - 20 Daublander M, Muller R, Lipp MD. The incidence of complications associated with local anesthesia in dentistry. *Anesth Prog* 1997; **44**: 132–141.
 - 21 FGDP. RESEARCH COMPETENCIES. 2007. [https://www.fgdp.org.uk/sites/fgdp.org.uk/files/docs/in-practice/Research/research competencies.pdf](https://www.fgdp.org.uk/sites/fgdp.org.uk/files/docs/in-practice/Research/research%20competencies.pdf).
 - 22 Sirintawat N, Sawang K, Chaiyasamut T, Wongsirichat N. Pain measurement in oral

- and maxillofacial surgery. *J Dent Anesth pain Med* 2017; **17**: 253–263.
- 23 Olley RC, Renton T, Frost PM. Observational study investigating tooth extraction and the shortened dental arch approach. *J Oral Rehabil* 2017; **44**. doi:10.1111/joor.12523.
- 24 Meechan JG. The use of the mandibular infiltration anesthetic technique in adults. *J Am Dent Assoc* 2011; **142 Suppl**: 19S-24S.
- 25 Dower JSJ, Barniv ZM. Periodontal ligament injection: review and recommended technique. *Gen Dent* 2004; **52**: 537–42; quiz 543, 527–8.
- 26 Currie CC, Meechan JG, Whitworth JM, Corbett IP. Is mandibular molar buccal infiltration a mental and incisive nerve block? A randomized controlled trial. *J Endod* 2013; **39**: 439–443.
- 27 Dumbrigue HB, Lim M V, Rudman RA, Serranon A. A comparative study of anesthetic techniques for mandibular dental extraction. *Am J Dent* 1997; **10**: 275–278.
- 28 Kaufman E, LeResche L, Sommers E, Dworkin SF, Truelove EL. Intraligamentary anesthesia: a double-blind comparative study. *J Am Dent Assoc* 1984; **108**: 175–178.
- 29 Kalsi AS, Kalsi JS, Bassi S. Alveolar ridge preservation: why, when and how. *Br Dent J* 2019; **227**: 264–274.
- 30 Roberts GJ, Simmons NB, Longhurst P, Hewitt PB. Bacteraemia following local anaesthetic injections in children. *Br Dent J* 1998; **185**: 295–298.
- 31 Anneroth G, Danielsson KH, Evers H, Hedstrom KG, Nordenram A. Periodontal ligament injection. An experimental study in the monkey. *Int J Oral Surg* 1985; **14**: 538–543.
- 32 Froum SJ, Tarnow D, Caiazzo A, Hochman MN. Histologic response to intraligament injections using a computerized local anesthetic delivery system. A pilot study in miniswine. *J Periodontol* 2000; **71**: 1453–1459.
- 33 Austin RS, Olley RC, Ray-Chaudhuri A, Gallagher JE. Oral disease prevention for older people. *Prim Dent Care* 2011; **18**: 101–106.
- 34 Olley RC, Sehmi H. The rise of dentine hypersensitivity and tooth wear in an ageing population. *Br Dent J* 2017; **223**: 293–297.

Figures

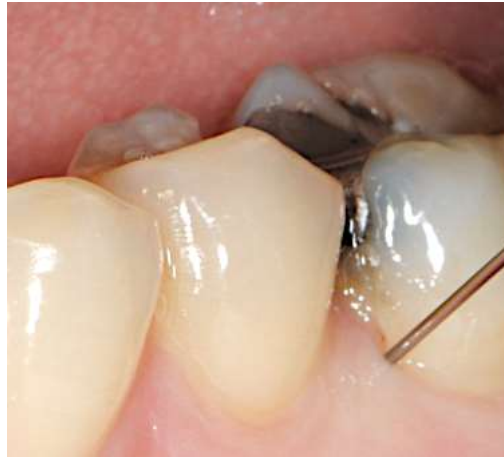

Figure 1 Intra-oral photograph showing the position of a conventional needle for ILA in a mandibular first molar tooth

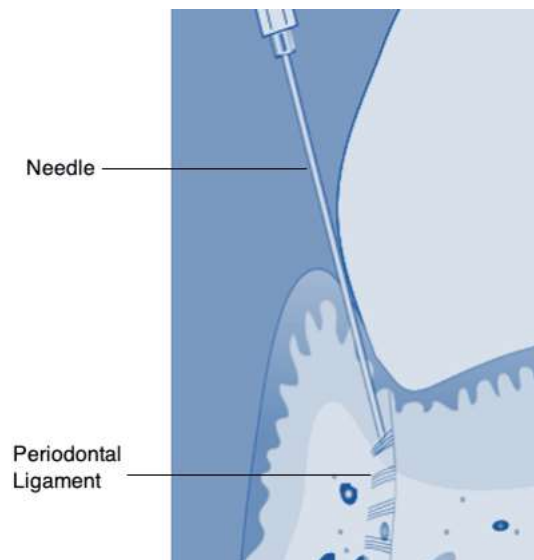


Figure 2 Diagram showing position of conventional needle into the periodontal ligament for ILA in a mandibular tooth

Figure 3 Posterior teeth extracted following ILA technique

