



King's Research Portal

DOI:

[10.1016/j.clinph.2018.08.019](https://doi.org/10.1016/j.clinph.2018.08.019)

Document Version

Peer reviewed version

[Link to publication record in King's Research Portal](#)

Citation for published version (APA):

daSilva Morgan, K., Elder, G. J., ffytche, D. H., Collerton, D., & Taylor, J-P. (2018). The utility and application of electrophysiological methods in the study of visual hallucinations. *Clinical Neurophysiology*, 129(11), 2361-2371. <https://doi.org/10.1016/j.clinph.2018.08.019>

Citing this paper

Please note that where the full-text provided on King's Research Portal is the Author Accepted Manuscript or Post-Print version this may differ from the final Published version. If citing, it is advised that you check and use the publisher's definitive version for pagination, volume/issue, and date of publication details. And where the final published version is provided on the Research Portal, if citing you are again advised to check the publisher's website for any subsequent corrections.

General rights

Copyright and moral rights for the publications made accessible in the Research Portal are retained by the authors and/or other copyright owners and it is a condition of accessing publications that users recognize and abide by the legal requirements associated with these rights.

- Users may download and print one copy of any publication from the Research Portal for the purpose of private study or research.
- You may not further distribute the material or use it for any profit-making activity or commercial gain
- You may freely distribute the URL identifying the publication in the Research Portal

Take down policy

If you believe that this document breaches copyright please contact librarypure@kcl.ac.uk providing details, and we will remove access to the work immediately and investigate your claim.

Accepted Manuscript

Review

The utility and application of electrophysiological methods in the study of visual hallucinations

Katrina daSilva Morgan, Greg J. Elder, Dominic H. ffytche, Daniel Collerton, John-Paul Taylor


PII: S1388-2457(18)31205-7
DOI: <https://doi.org/10.1016/j.clinph.2018.08.019>
Reference: CLINPH 2008639

To appear in: *Clinical Neurophysiology*

Received Date: 11 May 2018
Revised Date: 16 July 2018
Accepted Date: 21 August 2018

Please cite this article as: daSilva Morgan, K., Elder, G.J., ffytche, D.H., Collerton, D., Taylor, J-P., The utility and application of electrophysiological methods in the study of visual hallucinations, *Clinical Neurophysiology* (2018), doi: <https://doi.org/10.1016/j.clinph.2018.08.019>

This is a PDF file of an unedited manuscript that has been accepted for publication. As a service to our customers we are providing this early version of the manuscript. The manuscript will undergo copyediting, typesetting, and review of the resulting proof before it is published in its final form. Please note that during the production process errors may be discovered which could affect the content, and all legal disclaimers that apply to the journal pertain.



The utility and application of electrophysiological methods in the study of visual hallucinations

Katrina daSilva Morgan^{1*}, Greg J Elder^{1,2}, Dominic H ffytche³, Daniel Collerton⁴, John-Paul Taylor¹

¹ Institute of Neuroscience, Campus for Ageing and Vitality, Newcastle University, Newcastle upon Tyne, NE4 5PL, United Kingdom.

² Department of Psychology, Faculty of Health and Life Sciences, Northumbria University, Newcastle upon Tyne, NE1 8ST, United Kingdom

³ Institute of Psychiatry, King's College London, De Crespigny Park, London, SE5 8AF, United Kingdom

⁴ Northumberland, Tyne and Wear NHS Foundation Trust, Bensham Hospital, Gateshead, NE8 4YL, United Kingdom

*corresponding author at: Institute of Neuroscience, Campus for Ageing and Vitality, Newcastle University, Newcastle upon Tyne, NE4 5PL, United Kingdom. *E-mail address:* k.da-silva-morgan@ncl.ac.uk

Abbreviations:

VH: Visual hallucinations; EEG: Electroencephalography; MEG: Magnetoencephalography; ERG: Electroretinogram; TMS: Transcranial magnetic stimulation; VEP: Visual evoked potential; SAI: Short-Latency afferent inhibition; PT: Phosphene threshold; ECS: Electrical cortical stimulation; tDCS: Transcranial direct current stimulation; rTMS: repetitive transcranial magnetic stimulation; tACS: transcranial alternating current stimulation; tRNS: transcranial random noise stimulation; fMRI: functional magnetic resonance imaging; LBD: Lewy body dementia; PD: Parkinson's disease; PDD: Parkinson's disease dementia; DLB: Dementia with Lewy Bodies; CBS: Charles Bonnet Syndrome; HPPD: Hallucinogen persisting perception disorder; AD: Alzheimer's disease; LSD: Lysergic acid diethylamide

Highlights

- Electrophysiology offers a new perspective on dynamic aspects of visual hallucination aetiology
- Bottom-up, top-down, and network dysfunction is evident in visual hallucination prone pathologies
- Limitations in the literature restricts interrogation of visual hallucination mechanisms

Abstract

Visual hallucinations (VH) are a common symptom in multiple clinical and non-clinical populations. Although structural and functional neuroimaging has informed the understanding of VH, temporal resolution is limited. Electrophysiological techniques provide a complimentary perspective on dynamic and temporal aspects of neural functioning, offering greater insight into the mechanisms underlying their formation. In this review we examine and critically evaluate the emerging evidence base utilising electrophysiological approaches in the study of VH. Overall, increased visual system excitability, dysfunctional visual processing and network connectivity, and cholinergic dysfunction have been consistently observed in VH-prone pathologies. However, a major limitation is in the lack of robust experimental studies and the reliance on single case reports. We conclude that electrophysiology provides tentative evidence for the contribution of bottom-up, top-down, and network dysfunction in the aetiology of VH, supporting several existing VH models. Furthermore, we discuss how electrophysiology has been directly utilised in specific clinical interventions for VH. Further exploration utilising electrophysiology in combination with, for example, neuroimaging will help better understand VH aetiology while aiding in the development of novel therapeutic interventions for this difficult to treat symptom.

Key words: Electrophysiology; Visual Hallucinations; EEG; Transcranial Magnetic Stimulation; Brain Stimulation; Visual Cortex

1. Introduction

Visual hallucinations (VH) are a common symptom in both clinical and non-clinical populations, including a wide range of psychiatric, neurological, and ophthalmologic conditions such as schizophrenia, neurodegenerative dementias, eye disease, delirium and

drug-induced hallucinosis (Abraham and Duffy 1996; Menon et al. 2003; Collerton et al. 2005; Armstrong 2012; ffytche and Wible 2014).

Manifestations of VH range from simple hallucinations, consisting of flashing lights, geometric patterns, or formless colour (photopsia), through to more complex hallucinations, such as involuntary vivid perceptions of people, animals, or objects (Collerton et al. 2005). Recurrent VH, particularly in the presence of preserved insight, have sometimes been described as pleasant or entertaining experiences (Cox and ffytche 2014). However, for others, VH can be both distressing and detrimental to everyday functioning (Dudley et al. 2012).

The aetiology of VH is a matter of continuing debate. Neurophysiological investigations of VH provide evidence to support several key VH models (Table 1.) where the majority of studies utilise functional neuroimaging. While some studies posit spontaneous changes in visual cortical activity (i.e. ffytche et al. 1998; Santhouse et al. 2000; Oertel et al. 2007; Jardri et al. 2013) and cortical disinhibition as key in the formation of VH (i.e. Onofri et al. 2013), others have proposed a more complex cognitive interaction between visual, executive and attentional networks (i.e. Collerton et al. 2005; Diederich et al. 2005; Shine et al. 2011). Similarly, neuroimaging has supported the role of visuo-cortical dysfunction and visuo-perceptual deficits in conditions including Parkinson's disease (PD) and Lewy body dementias (LBD), with VH associated with decreased activity in extra-striate and visual association areas in combination with dysfunction in frontal regions, supporting the role of top-down attentional processes in VH (Stebbins et al. 2004; Meppelink et al. 2009; Taylor et al. 2012). In schizophrenia, models of VH are adapted versions of those developed for auditory verbal hallucinations, with evidence for specific involvement of the temporo-parietal junction and hippocampus (ffytche and Wible 2014).

[Table 1]

Table 1.*Key models of VH formation and maintenance including key associated pathologies*

Model	Description	Associated Pathologies
Deafferentation/Release Phenomena (i.e. Cogan 1973)	Diminished visual input due to visual system or retinal dysfunction results in spontaneous, compensatory hyper-excitability and disinhibition of the visual cortex, producing both simple and complex VH.	CBS; Occipital stroke; Visual system lesion
Cortical irritation (i.e. Noda et al. 1993)	Over-activity in brain regions containing specific imagery, memories and representations results in complex VH.	Occipital and temporal Epilepsy; CBS
Perception and Attention Deficit (PAD) (Collerton et al. 2005)	The combination of attentional and visual perceptual impairments interact with visual scene representations, resulting in incorrect perceptual proto-objects.	DLB; PDD; Schizophrenia
Visual Misperception and Network Dysfunction (Shine et al. 2011)	Network dysfunction and impaired signalling between the default mode network and ventral attentional network, in addition to lack of filtering from the dorsal attentional network, results in perceptual errors and the formation of VH.	PD; DLB
Integrative Model (Diederich et al. 2005)	The integrative contribution of poor vision, aberrant visual and associative cortex activation with disinhibition results in disturbance of gating and filtering of external perceptions and the production of internal images.	PD; PDD; DLB; CBS

Abbreviations: VH: Visual Hallucinations; CBS: Charles Bonnet Syndrome; DLB: Dementia with Lewy bodies; PDD: Parkinson's disease dementia; PD: Parkinson's disease.

Nevertheless, despite providing superior spatial insight into regional dysfunction, the relatively poor temporal resolution of functional neuroimaging impedes our understanding of the more dynamic aspects of cortical functioning and visual processing, limiting the scope of any conclusions drawn about VH aetiology. Comparatively, electrophysiology can offer further insight into nuances of cortical activity and dynamic function involved in VH and may be key in understanding the neurophysiological basis of this pervasive symptom. Techniques such as electroencephalography (EEG) and magnetoencephalography (MEG) may be used to reveal distinct stages in both resting states and complex cognitive processes involved in VH formation as well as having the temporal resolution to capture specific hallucination events as they occur. Visual evoked potentials (VEPs) can allow for

interrogation of temporal aspects of visuo-cortical processing, highlighting potential dysfunction in the form of latency delays and altered amplitudes. Measures of coherence and synchrony can further demonstrate the strength of functional connections between spatially discrete brain regions and cortical networks, revealing aspects of synaptic (dys)function. Electroretinograms (ERG) can provide more precise information regarding the role of retinal dysfunction. Furthermore, utilising forms of brain stimulation such as transcranial magnetic stimulation (TMS) and electrical cortical stimulation (ECS) may provide a more detailed insight into the excitatory and inhibitory processes involved in VH via the active perturbation of neural systems.

The present review sought to identify and evaluate relevant literature in order to examine the extent to which electrophysiological techniques have been used to inform our understanding of neurophysiological dysfunction in VH. The present review also sought to discuss how the use of these techniques can inform the development of treatments for VH.

2. Method

In order to identify relevant studies, PubMed (until 03 April 2018) and PsycINFO (from 1967 until March Week 3 2018) databases were searched independently and semi-systematically by two of the authors (KM and GJE) using the following terms: “visual hallucinations” AND “electrophysiology”, “electroencephalography”, “EEG”, “transcranial magnetic stimulation”, “repetitive transcranial magnetic stimulation”, “TMS”, “rTMS”, “electroretinogram”, “ERG”, “transcranial direct current stimulation”, “tDCS”, “transcranial alternating current stimulation”, “tACS”, “visual evoked potential”, “VEP”, “electrical stimulation”, “magnetoencephalography”, and “MEG”. This search strategy resulted in a total of 525 potential articles for inclusion (Figure 1). Article titles and abstracts were screened for relevance and the reference sections of included papers were also searched to identify

additional relevant studies. Articles were included where they were conducted in human participants. Studies and case reports were included where the study investigated VH phenomena and where the results were discussed in terms of their contribution to the overall understanding of the mechanisms involved in VH. Review articles, non-English and duplicate articles were removed. This resulted in a final total of 55 studies.

[Figure 1]

3. Results

A total of fifty-five studies were identified that utilised electrophysiological approaches in the investigation of VH (Supplementary Table S1). The most common approach used was EEG (28 studies), including 9 studies examining VEP. A total of 20 studies employed other electrophysiological approaches, including MEG (3 studies), TMS (7 studies), ECS (9 studies) and ERG (1 study). Treatment studies identified included tDCS (4 studies) and rTMS (5 studies).

The most common pathology studied was epilepsy (13 studies) followed by LBD (8 studies). Other pathologies studied included Charles Bonnet Syndrome (CBS; 7 studies) PD (5 studies), drug-induced hallucinosis (6 studies), schizophrenia (3 studies), migraine (2 studies), affective disorders including Bipolar disorder and major depression (3 studies), and occipital stroke (3 studies). Five studies were conducted in healthy participants, of which four studies induced VH in participants using intermittent photic stimulation (flicker) across the entire visual field (3 studies) or a computerised pattern-glare task (1 study), while one study assessed VH susceptibility of healthy participants utilising face and Mooney face image stimuli. Twenty-seven papers detailed single or two-person case reports. Due to the heterogeneity of the studies and the wide range of electrophysiological approaches utilised,

these data were not amenable to meta-analysis. An overview of the electrophysiological approaches identified, and relevance, is provided in Table 2.

[Table 2]

Table 2.

Common electrophysiological approaches employed in the investigation of VH.

Electrophysiological approach	Functional Utility in VH	Example Reference
EEG	<p><i>Resting state EEG:</i> allows for the assessment of underlying cortical activity including epileptiform activity, power spectra and oscillatory alterations; possesses the temporal clarity to capture activity both during the VH state and resting state differences in VH-prone patients. Coherence analysis allows for the assessment of the strength and integrity of functional connections between regions and networks.</p> <p><i>VEP:</i> allows for the investigation of time-dependent aspects of distinct visual processes, highlighting dysfunction in the form of latency delays and amplitude alterations.</p>	<p><i>e.g. Kometer et al. (2013); ffytche (2008)</i></p> <p><i>e.g. Matsui et al. (2005);</i></p>
MEG	Measures the same signal as EEG. Able to capture high-frequency activity which EEG cannot and allowing assessment of underlying cortical activity and oscillations during resting-state and VH.	<i>e.g. Carhart-Harris et al. (2016)</i>
ERG	Records the electrical response of the retina to light, allowing for the interrogation of photoreceptor layer and early visual system dysfunction and their contribution to VH.	<i>Devos et al. (2005)</i>
TMS	<p><i>Phosphene threshold assessment:</i> uses a magnetic current to artificially stimulate the visual cortex aiding in the study of visual cortical excitability.</p> <p><i>SAI:</i> TMS paradigm which has been used to examine central cholinergic dysfunction in relation to VH</p>	<p><i>e.g. Taylor et al. (2011);</i></p> <p><i>Manganelli et al. (2009)</i></p>
ECS	Direct electrical stimulation of cortical regions via implanted electrodes and stereo-EEG which can result in complex VH; allows for the examination of cortical regions and networks involved in the production of VH imagery.	<i>e.g. Diederich et al (2000)</i>

Abbreviations: EEG: Electroencephalography; VEP: Visual evoked potentials; MEG: Magnetoencephalography; ERG: Electroretinogram; TMS: Transcranial magnetic stimulation; SAI: Short-latency afferent inhibition; ECS: Electrical cortical stimulation.

The text in the following section will be organised by electrophysiological approach employed and discussed in terms of current VH models.

4. Summary of Findings

4.1 Resting EEG & MEG – Alpha Rhythm

Utilising techniques such EEG and MEG, it is possible to observe alterations in cortical function both in real-time as VH are occurring and resting-state differences in VH-prone individuals. One such spontaneous rhythm, occipital alpha (α), has been implicated as a cortical idling or resting rhythm, with alpha-power maximal when the eyes are closed (Barry et al. 2007). Alpha-rhythm desynchronization has been posited as a measure of active cortical processing and cortical excitability (Pfurtscheller et al. 1996; Thut et al. 2006; Barry et al. 2007; Romei et al. 2008) and decreases in occipital alpha-power are associated with increased excitability and visual attention, while increased occipital alpha-power correlates with reduced occipital excitability (Thut et al. 2006).

4.1.1 Non-clinical studies – induced VH

It has been shown that pharmacologically-induced VH in healthy participants by means of potent serotonergic hallucinogens have been accompanied by significant posterior alpha-power changes. Decreases in parieto-occipital alpha-power have been observed following administration of psilocybin, an effect subsequently blocked by serotonin antagonist ketanserin, indicating a role of serotonin-2A receptor activation in psilocybin induced VH (Kometer et al. 2013), while decreased peak alpha-amplitudes in the posterior cingulate cortex and precuneus strongly correlate with ratings of VH induced by lysergic acid diethylamide (LSD) (Carhart-Harris et al. 2016).

Occipital alpha-power has also been implicated in attention-dependent filtering in the visual system, with decreases in the lower occipital alpha-band signifying increased selective

attention (Pfurtscheller et al. 1996). One study has reported such decreases preceding the presence of hallucinatory colours induced by flickering-light stimulation, with subsequent changes in colour directly followed by increases in gamma synchronisation (Becker et al. 2009). This suggests that decreases in occipital alpha-power may instead operate as a gating mechanism between hallucinatory content, while changes in gamma power allow for the formation of conscious perceptions via access to attentional processes. In support of this, a similar study of flickering-light induced VH noted increased gamma power following hallucinations of circles and point patterns, which is in keeping with its posited role in conscious perception formation (Elliott et al. 2012). As oscillations in both alpha and gamma rhythms have been associated with attentional processing, such evidence may point towards more complex interactions between visual and attentional processing which may be necessary to formulate VH, supporting attentional or integrated models of VH aetiology (i.e. Collerton et al. 2005; Diederich et al. 2005) rather than deafferentation in isolation.

4.1.2 Clinical studies – CBS, HPPD, DLB, PD

Generalised decreased alpha-power has been observed in Charles Bonnet Syndrome (CBS) patients (Hanoglu et al. 2016), a pathology characterised by VH secondary to visual impairment. As occipital alpha-power alterations are indicative of changes in excitability, such changes may indicate a key role of visual-cortical excitability and disinhibition in the formation of VH, which supports functional imaging evidence of increased visual cortical activity during VH (i.e. ffytche et al. 1998). These data underwrite the argument for a bottom-up contribution to VH consistent with deafferentation models of VH formation (Table 1.). A study of individuals experiencing recurrent VH as a long term consequence of LSD usage (Hallucinogen Persisting Perception Disorder, or HPPD), observed accelerated alpha frequencies compared to non-HPPD controls, albeit with an absence of alpha-amplitude differences (Abraham and Duffy 1996). Accelerated alpha rhythms observed in LSD animal

studies (i.e. Brawley and Duffield 1972) have been postulated to be an observable effect of disrupted inhibitory function of serotonin-2 receptors by LSD; consequently, such acceleration in HPPD may similarly indicate chronic disinhibition of the visual system contributing to the occurrence of VH.

As many VH-prone pathologies (i.e. DLB, PDD) exhibit attentional deficits (Stebbins et al. 2004; Collerton et al. 2005; Taylor et al. 2012; Onofrij et al. 2013) the type, distribution and functional significance of resting EEG oscillatory alterations in VH may differ. While decreased resting-state posterior alpha-power has been recorded in VH-prone pathologies, including DLB and PDD (Bonanni et al. 2008; Bosboom et al. 2009; Ponsen et al. 2013), no studies have directly investigated the relationship between this phenomena and the occurrence of VH in these cohorts, or made comparisons with non-hallucinating counterparts. Consequently, it is unclear whether these differences are inherently related to the disease state itself or play a role in VH susceptibility. Cholinesterase inhibitors, frequently used in the treatment of VH-prone pathologies such as PDD, can result in increases to parieto-occipital and temporal alpha-power (Bosboom et al. 2009). As such, investigating the amelioration of VH symptoms in response to pharmacologically induced alpha-power changes may constitute an interesting avenue of research on the causal or epiphenomenal role of alpha-power alterations in VH.

4.2 Resting EEG – cortical slowing and epileptiform activity

Generalised cortical slowing is frequently an indicator of underlying diffuse cerebral dysfunction so that, with the exception of studies of theta activity, the literature in this area relates to clinical disorders. In VH cohorts, widespread slowing of cortical oscillations has been observed during complex VH in CBS, but not in cerebrovascular infarction and frontal lobe dementia (Lorberboym et al. 2002), while widespread rhythmic slow-waves and

suppression of rhythmic sharp waves across the temporo-parieto-occipital region were observed during complex ictal VH in a case of nonconvulsive status epilepticus (Kim et al. 2012). For the latter, both rhythmic EEG alterations and VH were abolished following treatment with Lorazepam, indicating a link between altered EEG and the presence of VH (Kim et al. 2012). Slowing in posterior and occipital regions in the absence of epileptiform discharge has also been observed in a patient with seizures and another patient with CBS during complex VH (Josephson and Kirsch 2006). Furthermore, epileptiform discharges in conjunction with complex VH have been observed over right-sided centro-parietal regions in a patient with CBS, with both epileptic activity and VH diminishing following antiepileptic treatment (Ossola et al. 2010). However, slowing is not a consistently reported phenomena; both intermittent and continuous periodic occipital and temporal sharp and spike waves have been observed in occipital epilepsy with elementary VH (Yalçın et al. 2000; Oishi et al. 2003; Alves-Leon et al. 2011), while epileptic mechanisms including generalised periodic synchronous discharges have also been observed in conjunction with complex VH and cognitive dysfunction in DLB (Sun et al. 2014).

Altered posterior theta-wave activity, commonly associated with drowsiness and sleep, is also evident in VH-prone cohorts. Increased posterior and temporal theta activity has been demonstrated in CBS, epilepsy and AD (Lopez et al. 1991; Oishi et al. 2003; Hanoglu et al. 2016), although the latter study did not differentiate their analysis between AD patients with VH compared with those with auditory hallucinations. Increased theta synchronisation in parieto-occipital regions has also been observed in a patient with complex VH following occipital stroke (Tombini et al. 2012), while significant increases to posterior theta-power were observed during flicker-induced VH of circle and point patterns in healthy participants (Elliott et al. 2012). Nevertheless, diminished posterior theta-power has also been reported during VH in a patient with CBS and in the precuneus during LSD-induced VH (Kazui et al.

2009; Carhart-Harris et al. 2016) while high-theta band synchronisation has been negatively correlated with the severity of VH in DLB (Peraza et al. 2018).

While diffuse cortical slowing is evident in several VH-prone pathologies in the absence of active VH, including CBS (Pliskin et al. 1996) and DLB (Mckeith et al. 2005; Gaig et al. 2011), it is unclear whether this electrophysiological feature is directly related to VH. Nevertheless, cortical slowing may instead generate a physiological brain state permissive to VH occurrence; but in this context other factors may be needed to allow for VH manifestation.

Diffuse slow-wave activity and focal sharp-waves observed during VH may support cortical release models of VH formation, which suggest that VH occur due to functional changes in early visual cortex or visual association cortices in conjunction with the suppression of normal inhibitory input (Manford and Andermann 1998). However, the wider distribution of EEG abnormalities also suggests involvement of higher-level brain networks in VH. For example, abnormal EEG activity including cortical slowing or sharp and spike waves during complex VH is typically observed over posterior, temporal and parietal regions (Sowa and Pituck 1989; Josephson and Kirsch 2006; Ossola et al. 2010; Kim et al. 2012). Meanwhile, evidence for the involvement of additional limbic structures and frontal networks has been observed in a patient with bipolar disorder demonstrating rhythmic frontal spike waves followed by generalised cortical slowing in the presence of complex emotional VH (Manfioli et al. 2013).

Nevertheless, a major limitation of the studies identified is that they predominantly consist of single case observations and lack adequate comparisons with non-hallucinating counterparts. Additionally, studies often provide insufficiently detailed or poorly-defined descriptions of

slow-wave and ictal EEG activity, such as defining activity only as ‘abnormal’ (i.e. (Pliskin et al. 1996), which prevents meaningful comparisons being made.

While EEG studies during VH can provide insight into active oscillatory changes involved in the VH state (i.e. Josephson and Kirsch 2006; Ossola et al. 2010; Kim et al. 2012; Manfioli et al. 2013; Sun et al. 2014; Carhart-Harris et al. 2016; Hanoglu et al. 2016), studies reporting trait differences in the cortical oscillations of VH-prone patients are often challenged when drawing direct conclusions about their relative contribution to VH susceptibility (i.e. Lopez et al. 1991; Pliskin et al. 1996; Mckeith et al. 2005; Gaig et al. 2011; Peraza et al. 2018).

Moreover, as the studies reported predominantly demonstrate correlational evidence linking cortical oscillation alterations to VH, it is not possible to draw adequate conclusions regarding the specific influence of these alterations on VH susceptibility or their formation.

4.3 Coherence and Connectivity Dysfunction

Measures of EEG coherence can provide an indication of synchrony and connectivity between cortical regions during VH, with particular sensitivity to specific frequency bands indicative of different aspects of neural activity and the strength of functional connections. This approach is appealing given that the basis of VH models, including PAD, network, and integrative models (Table 1), typically encompass multiple brain areas and their interactions.

4.3.1 Non-clinical studies – induced VH

The incidence of hallucinations of colours, geometric patterns, and motion (Purkinje patterns) induced by flickering light stimulation in healthy participants have been associated with increased coherence between occipito-parietal regions and Cz (central midline) (ffytche 2008). Additionally, differences have been described between the onset and maintenance of long and short-range coherence within the occipital lobe, with connectivity initially

decreasing but then slowly increasing and correlating with the gradual occurrence of VH (ffytche 2008).

4.3.2 Clinical studies – Stroke, HPPD

Increased synchronisation between parieto-occipital regions have been observed in an occipital stroke patient with VH during hyperventilation (Tombini et al. 2012). Enhanced regional occipital coherence has been observed in HPPD during the eyes-closed state, but with reduced synchrony observed between occipital regions and more distant cortical areas (Abraham and Duffy 2001).

Both HPPD and non-clinical induced hallucination studies indicate a potential role of network connectivity in VH formation. However, while ffytche et al (2008) measured coherence during the VH state, coherence in HPPD was measured in VH-prone individuals whilst VH were absent. While there may be fundamental differences in pathological locus between these studies, it is possible that these differences may provide insight into the role of network connectivity in state versus trait aspects of VH and their formation. While gradual changes in coherence between regions may indicate a physiological aspect of the VH state, overall resting-state alterations in synchrony between visual system, perceptual and attentional networks may facilitate the formation of VH and overall VH susceptibility. Nevertheless, research in this area is limited and further investigation is needed before more concrete conclusions can be made.

4.4 Abnormal Visual Evoked Potentials

Event related potentials collected from EEG recordings of the visual cortex during visual stimulation enable the investigation of visual pathways leading from the retina to the visual cortex. The subsequent visual evoked potentials (VEPs) can, in turn, be used to examine distinct visual processes, including pattern recognition and target detection, using measures

of VEP waveform latency and amplitude. VEP latency provides information about the integrity of visual pathways and transmission between cortical areas, while the amplitude reflects the synchronicity of the site being recorded.

4.4.1 Non-clinical studies

Significantly reduced early VEP amplitudes (P100) have been noted over parieto-temporal regions in healthy individuals with a high susceptibility to VH during visual stimulation, compared to those with low susceptibility, while later components associated with perceptual processing (N170) remain unaffected, suggesting altered early visual processing may play a role in VH susceptibility in this cohort (Schwartzman et al. 2008). Nevertheless, P100 amplitudes have been observed to be increased by psilocybin over occipital regions, which may be linked to a generalised serotonergic effect believed to mediate the perceived brightness of psychedelic-VH (Kometer et al. 2011).

VEP alterations are not isolated to early visual processing components, with delays evident in intermediate components associated with perceptual processing. Decreased N170 amplitudes are associated with the occurrence of VH in healthy participants following psilocybin administration (Kometer et al. 2013), with overall reductions in right extrastriate and posterior parietal activation (measured by standardised low-resolution electromagnetic tomography) positively correlating with VH intensity (Kometer et al. 2011).

4.4.2 Clinical studies – DLB, PD, HPPD, AD

Elongated VEP components in various stages of visual processing have been associated with the occurrence of VH and in VH-prone pathologies. The P100 component, which is a marker of early visual processing, has been observed to be elongated in PD patients with VH but not in non-hallucinating counterparts (Matsui et al. 2005), supporting, albeit indirectly, the role of bottom-up components such as deafferentation in VH formation.

As in non-clinical studies, VEP alterations are not isolated to early visual components, with notable delays evident in intermediate components associated with perceptual processing, such as the P200, in both PD and DLB hallucinators (Kurita et al. 2010) and shorter peak P200 latencies observed in HPPD compared to controls (Abraham and Duffy 1996). Such findings may present further evidence of perceptual dysfunction associated with VH formation, supporting models such as the PAD (Collerton et al. 2005).

Increased P300 latencies, a VEP component associated with higher-order visual and attentional processing, has been noted in PD, PDD and DLB patients with VH, as compared to non-hallucinating AD patients (Kurita et al. 2005, 2010) and controls (Chang et al. 2016). Although evidence is limited, such alterations may further indicate attentional dysfunction involved in VH formation. Nevertheless, while delayed P300 have been observed in PD, these abnormalities did not appear to correlate with the incidence of VH, instead REM sleep behaviour disturbances were more prominently linked to VH formation, implying that dysfunction in later visual processing alone may be insufficient to elicit VH in this patient group (Onofrj et al. 2002). Nonetheless, unlike many electrophysiology studies, several VEP studies identified provide direct comparisons with non-hallucinators, tentatively allowing researchers to draw more conclusions regarding the electrophysiological nature of VH and VH susceptibility.

4.5 Electroretinogram

The retina and dysfunctional visual input has been implicated in the aetiology of VH (Bernardin et al. 2017). Using electroretinogram (ERG), visual processing abnormalities can be investigated by recording the electrical response of the retina to light stimulus as a biphasic wave form, consisting of the a-wave and b-wave.

4.5.1 Clinical studies – DLB, PD

In DLB, cone a-waves, b-waves and rod b-waves demonstrate significant latency increases, while rod b-waves display decreases in amplitude compared to PD patients without VH and healthy controls, indicating the influence of photoreceptor layer dysfunction and degraded sensory input on the formation of VH in this patient group (Devos et al. 2005)(Table 3). Similar abnormalities have been observed in PD, which in turn have been linked to dysfunction of the dopaminergic retinal system, decreases in surround inhibition in the eye, and have further been associated with the formation of VH (Diederich et al. 2005; Onofrij et al. 2006; Weil et al. 2016). Nonetheless, investigation utilising ERG in CBS is still notably absent. It is not clear, for example, whether the ERG in patients with a given eye condition differs in those with CBS compared to those without it. As CBS is arguably the archetypical condition demonstrating the contribution of aberrant bottom-up processing in VH formation, it is an area of investigation that should be pursued further.

4.6 Transcranial Magnetic Stimulation

Artificial stimulation of the cortical visual system, via means of perturbation of external visual stimuli (i.e. scotomas) or the induction of artificial percepts using magnetic or electrical currents, has been used as a means of understanding visual function and pathways in both healthy volunteers and various pathologies. Transcranial magnetic stimulation (TMS) has been used to investigate visual cortical excitability in healthy individuals (i.e. Antal et al. 2003), with the lowest intensity of stimulator output needed to elicit transient visual phenomena, typically manifesting as spots of light in the visual field (known as ‘phosphenes’) corresponding with the level of visual cortical excitability.

4.6.1 Clinical Studies – DLB, PD

TMS has been utilised to investigate differing cortical excitability in regards to VH. In DLB, TMS of the primary visual cortex has demonstrated that lower phosphene thresholds (PT;

denoting increased cortical excitability) correlate strongly with the severity and frequency of VH (Taylor et al. 2011). While PT in DLB have not been found to significantly differ from those of healthy controls, they have been observed to negatively correlate with the magnitude of blood oxygen level dependent (BOLD) response in the primary visual cortex in response to checkerboard stimuli, compared to the positive correlation observed in healthy controls (Taylor et al. 2016). These findings suggest that DLB may be characterised by loss of inhibition in the occipital cortex, with increased cortical excitability acting as a marker of VH severity. Similarly, significantly lower PT have been observed in users of the drug ‘ecstasy’ who experience VH compared to those who do not (Oliveri and Calvo 2003), and migraine patients experiencing aberrant visual aura when compared to patients without aura (Aurora et al. 2003) and controls (Khedr et al. 2006).

Table 3.

Examples of the contribution of electrophysiological investigation to the understanding of VH in dementia with Lewy bodies (DLB) with example references.

Electrophysiological Technique	Key Findings	Example reference
EEG	Altered EEG may act as a marker of complex VH frequency and severity in DLB evidenced by a significant correlation between diminished high-theta band synchronisation and ratings of VH in DLB patients.	<i>Peraza et al (2018)</i>
VEP	Perceptual and attentional processing dysfunction may be associated with VH in DLB, evidenced by significantly elongated latencies in P200 and P300 VEP components when compared to AD and controls.	<i>Kurita et al (2010)</i>
ERG	Impaired bottom-up processing and photoreceptor layer dysfunction may influence the formation of VH in DLB evidenced by significantly increased latencies in cone a- and b-waves, and significantly decreased amplitudes and increased latencies in rod b-waves compared to PD patients without VH and controls	<i>Devos et al (2005)</i>
TMS	Increased visual cortical hyperexcitability may act as a marker of VH severity and frequency in DLB, demonstrated by a negative correlation between phosphene thresholds and ratings of VH.	<i>Taylor et al (2011)</i>

[Table 3]

While evidence of disinhibition and increased cortical excitability supports VH models postulating the contribution of bottom-up deafferentation in VH formation, heterogeneity in the results, such as increased PTs in a patient with complex VH following occipital stroke (Tombini et al. 2012) may further suggest that the pathological locus of VH may be highly dependent on disease group, with bottom-up dysfunction more prominent in certain groups (i.e. eye disease, occipital infarct) while higher visual processing dysfunction may functionally disinhibit lower visual areas in other pathologies (i.e. DLB)(Table 3). The use of TMS to enhance or perturb cortical regions outside of the visual cortex (i.e. parietal regions) has also been observed to influence aspects of visual functioning and attention in healthy participants (i.e. (Hilgetag et al. 2001; Chambers et al. 2006), but similar investigations have not yet been conducted in VH patients.

4.7 Cholinergic Dysfunction

Short-latency afferent inhibition (SAI), a TMS based paradigm stimulating inhibitory circuits of the motor cortex, can be used as an indirect measure of cholinergic dysfunction. Reduction in SAI occurs in PD patients with VH compared to non-hallucinators and controls, and is further associated with impaired visuospatial and attentional function (Manganelli et al. 2009). Similarly, DLB patients demonstrate reduced SAI in comparison to controls which significantly positively correlate with VH (Marra et al. 2012). In this context, the loss of cortico-pedal cholinergic tone may lead to broader network dysfunction, which impacts the visual system and results in a predisposition to VH in these patient groups.

4.8 Electrical Cortical Stimulation

Frequently used in neurosurgical interventions for epilepsy, stimulation of cortical regions via implanted depth electrodes and stereo-EEG using electrical cortical stimulation (ECS) can induce complex hallucinatory experiences. The nature of the resulting hallucinations can range from face hallucinations to detailed topographic scenes and coloured characters, and seemingly depend on the specific cortical regions stimulated (Penfield and Perot 1963; Blanke et al. 2000; Diederich et al. 2000; Lee et al. 2000; Vignal et al. 2000; Schulz et al. 2007; Jonas et al. 2014a, 2014b, 2018; Mégevand et al. 2014). The external stimulation of regions containing visual memories/visual representations supports theories of cortical irritation in VH formation (Noda et al. 1993) and may parallel the observations of increased spontaneous occipital excitability in other VH pathologies such as CBS, which demonstrates phasic increases in regional activity related to VH content (ffytche et al. 1998).

ECS further demonstrates that VH can be elicited via the stimulation of diverse regions, though spread of stimulus current from one region to another (particularly in more historical studies) cannot be discounted, and thus topological co-localisation of structures to VH and their specific phenomenology is rarely straightforward. Similar VH can be produced when stimulating distinct regions both separately or in tandem (i.e. stimulation of occipito-parietal sulcus, right posterior precuneus, fusiform face area, and inferior frontal gyrus are all observed to evoke varying forms of face hallucination - Vignal et al. 2000; Jonas et al. 2014a, 2014b, 2018) suggesting that there may be no single locus of VH and reinforcing the integral involvement of complex networks in the production of VH and VH content. Further supporting this, deep brain stimulation of the subthalamic nucleus in a patient with PD resulted in elaborate recurrent VH, which were extinguished only upon termination of the stimulations, demonstrating a possible role of pathways between the subthalamic nucleus and limbic systems in the pathophysiology of VH in PD (Diederich et al. 2000). Stimulation of the amygdala and hippocampus in patients with epilepsy has been observed to result in

complex VH related to autobiographic memories and may further indicate the role of these complex higher-level networks in epilepsy VH (Vignal et al. 2007). Furthermore, electrical stimulation during a reading task in a patient with focal epilepsy provoked complex VH of reading content, perhaps also signifying the integral role of working memory networks in VH phenomenology (Schulz et al. 2007).

While challenges with stimulation precision make it difficult to pinpoint the precise topological origin of specific VH content using ECS, utilising this technique may allow for further interrogation of which networks are most relevant to different VH phenomenologies and, by implication, the different underlying pathological conditions with which they are associated.

5. Utilising electrophysiology in the treatment of VH

Using electrophysiology, it has been possible to identify a number of neurophysiological aspects of VH indicating hyperexcitability, cortical disinhibition and cholinergic dysfunction in several pathologies, which may have distinct implications for future treatment interventions. In this section we describe studies which have directly utilised electrophysiological approaches to target these abnormalities in the treatment of VH.

5.1 Therapeutic TMS

TMS has been used to suppress cortical activity in hallucinators with some therapeutic success. Recurrent courses of low-frequency, inhibitory, repetitive TMS (rTMS) applied over temporo-parietal regions in auditory hallucinators with schizophrenia have produced significant symptomatic improvements, including the reduction of the frequency and severity of hallucinations when compared to placebo stimulation (i.e. Hoffman et al. 1999; Chibbaro et al. 2005; Fitzgerald et al. 2006; Vercammen et al. 2010). Despite positive therapeutic

indications in auditory hallucinators, however, rTMS studies in VH groups are limited to a handful of single case reports; for example, inhibitory rTMS of V5/MT has been observed to successfully suppress motion VH in a patient with CBS (Meppelink et al. 2010), while occipital rTMS following occipital stroke successfully suppressed complex VH for up to a week post-stimulation (Merabet et al. 2003). Similarly, repeated sessions of occipital and occipito-temporal rTMS have reduced the frequency and severity of VH (Jolfaei et al. 2016) and audio-visual multisensory hallucinations (Jardri et al. 2009) in schizophrenia. More recently, rTMS of the lesion site following occipital stroke was observed to reduce the occurrence of simple VH while simultaneously normalising imbalanced cortical activity at both the stimulation site and across remotely connected cortical regions (Rafique et al. 2016).

5.2 Transcranial electrical stimulation

Applying a weak, low-voltage current through electrodes on the scalp, techniques including direct, alternating and random noise transcranial current stimulation (tDCS, tACS, and tRNS respectively) have more recently been applied as a means of modulating cortical activity in relation to neuropsychiatric symptoms that may be the result of changes in neuronal membrane polarisation (Nitsche et al. 2008; Stagg and Nitsche 2011). Like rTMS, positive therapeutic benefits have been observed for auditory verbal hallucinations in schizophrenia, with tDCS applied over multiple days leading to prolonged reductions in hallucination severity (Brunelin et al. 2012). To date, very few studies have employed transcranial electrical stimulation with regards to VH. A study investigating the predisposition of healthy participants to VH induced during a computerised pattern-glare task found that, during medium-intensity visual stimulation, excitatory (anodal) tDCS (relative to sham stimulation) increased the number of reported VH-like experiences while, to a lesser extent, inhibitory

(cathodal) stimulation decreased them, indicating a role of cortical hyperexcitability in VH susceptibility in this cohort (Braithwaite et al. 2015). Utilised as a clinical tool, two case reports employing identical stimulation protocols describe positive results, with cathodal tDCS of the occipital area across multiple sessions resulting in the successful reduction of VH in a patient with major depression lasting several weeks (Koops and Sommer 2017) and a patient with schizophrenia lasting over two months (Shiozawa et al. 2013). More recently, the complete remission of VH symptoms in a patient with depression was observed following four weeks of cathodal stimulation of the right temporal area; interestingly, these symptomatic changes were also accompanied by a significant reduction in occipital alpha-power post-treatment, which contradicts earlier studies suggesting a pathological role of decreased occipital alpha in VH formation and thus may indicate differing mechanisms involved in the occurrence of VH in depression (Gomes et al. 2017). Additionally, studies in the healthy visual system using tDCS have also indicated that stimulation alters the amplitude of cortical VEPs (Antal et al. 2004; Accornero et al. 2007) and TMS-evoked PT (Antal et al. 2003). Since VH pathologies also demonstrate alterations in these domains, further experimental studies assessing the effects of tDCS upon VH may provide an insight both into their aetiology and potential treatment.

A major limitation of many therapeutic rTMS and tDCS studies is the lack of placebo conditions. As placebo effects can be particularly large in therapeutic investigations (Kaptchuk and Miller 2015), this may raise questions about whether the amelioration of VH symptoms are solely due to the stimulation treatment itself or placebo effect. Moreover, producing appropriate placebo conditions can prove challenging in stimulation studies, with common difficulties involving unsuccessful blinding and confounding sensory side-effects of sham stimulation (Duecker and Sack 2015). Furthermore, therapeutic stimulation studies often employ differing stimulation protocols, including different stimulation intensities,

stimulation duration, and cortical targets, making it difficult to pinpoint the optimal parameters needed to produce beneficial effects in different pathologies. Further investigation in VH cohorts should utilise larger, appropriately placebo-controlled study designs, testing a range of stimulation parameters, before adequate inferences about the therapeutic benefits of transcranial stimulation can be made (Elder and Taylor 2014). It should also be noted that while there are limited reports of successful amelioration of VH symptoms using transcranial stimulation, there is also a distinct lack of negative reports, which may also reflect a positive publication bias in the literature. It is important that negative findings are fully reported so that the extent of any potential clinical benefits can be assessed, including which stimulation parameters may be the most appropriate for different patient cohorts.

6. Discussion

While electrophysiological approaches have provided important insights into the underlying mechanism of VH and novel treatment options, they are still relatively underused when compared to techniques such as neuroimaging. Nevertheless, current electrophysiological evidence supports several VH models. Evidence of bottom-up dysfunction, visuo-cortical hyperexcitability and disinhibition has been observed utilising EEG, MEG, TMS and ERG (i.e. Abraham and Duffy 1996; Devos et al. 2005; Matsui et al. 2005; Taylor et al. 2011; Carhart-Harris et al. 2016; Hanoglu et al. 2016), while alterations in VEP latencies and amplitudes have reflected deficits in top-down visual attentional and perceptual processing (i.e. Kurita et al. 2005; Kometer et al. 2013; Chang et al. 2016). Wider cortical network dysfunction in the form of EEG coherence alterations and TMS-measured cholinergic dysfunction is also evident in several pathologies (i.e. Abraham and Duffy 2001; ffytche 2008; Manganelli et al. 2009), while the stimulation of diverse cortical regions using ECS has

demonstrated a role of complex networks in the formation of VH phenomenology (i.e. Diederich et al. 2000; Schulz et al. 2007; Manfioli et al. 2013) (Figure 2). However, there is currently insufficient evidence to arbitrate between different models or to clarify the relative contribution of bottom-up and top-down dysfunction in different conditions. From an electrophysiological perspective, it remains unclear whether the same mechanism underlies VH in all conditions or whether different mechanisms, or differences in their relative contribution, underlie VH in different conditions. Such distinctions are important from a clinical perspective as they determine whether a single approach to treatment is required for VH or different treatments for each pathology.

The superior temporal resolution of electrophysiological approaches, for example when comparing EEG to neuroimaging techniques such as fMRI, make them particularly suited for studies of the dynamic changes at the time of VH. However, there are substantial methodological challenges in capturing VH phenomena, such as unpredictability in when they occur, and subsequently many of the studies identified rely on single observational case reports or small, potentially atypical, patient groups. Electrophysiological techniques also make important contributions to our understanding of visual and cognitive function in VH-prone patients. However, relatively few studies to date have been able to successfully disentangle non-specific changes related to the underlying condition and changes specific to VH susceptibility.

[Figure 2]

Heterogeneity within the literature presents a further limitation. The broad spectrum of clinical and non-clinical populations reported include participants with varying degrees of VH severity, intensity and phenomenology. Consequently, it is difficult to meaningfully compare the contribution of common mechanisms involved in VH both across and within

cohorts due to underlying differences in physical pathology and the manifestation of VH symptoms. Furthermore, the diverse range of electrophysiological approaches reported, and the broad number of methodologies, prevents direct comparison between many studies, making delineating the impact of different electrophysiological alterations on overall VH formation and susceptibility difficult.

It is imperative that future research studies employ rigorous experimental designs to identify VH specific changes, including collection of experimentally controlled data from larger samples, better characterisation of hallucinating and non-hallucinating groups, and a trans-diagnostic perspective. However, such studies may not in themselves be able to provide a complete account of the mechanism of VH. Combined approaches may be required such as those linking EEG power, coherence and cortical excitability measured with changes in cerebral blood flow (e.g. ffytche 2008; Meppelink et al. 2010; Carhart-Harris et al. 2016; Rafique et al. 2016; Taylor et al. 2016) in order to gain a more complete perspective of both the spatial and temporal mechanisms involved in VH. Combining techniques such as TMS and EEG will undoubtedly allow for enhanced interrogation of temporal aspects of VH (i.e. Murphy et al. 2017), including characteristics of visual system and cortical network dysfunction and their contribution to the emergence of VH. Furthermore, when investigating potential treatments such as rTMS and tDCS, which are only capable of indirectly affecting deep subcortical areas that are networked to the structures receiving stimulation, combined electrophysiology and neuroimaging techniques may be required to fully understand changes across networks in relation to VH.

7. Conclusion

Findings from electrophysiology have highlighted several examples of widespread visual system dysfunction evident across multiple VH-prone pathologies, reflecting a dynamic set of

impairments that may contribute to VH. While common electrophysiological features can be observed across multiple VH pathologies, heterogeneity in the literature and the lack of exhaustive or experimentally controlled research in this area means that it is currently difficult to confidently assess how these features contribute to VH formation or susceptibility. Nevertheless, electrophysiological methods may provide a means of mapping the dynamic changes that occur across the visual system leading to VH, offering a new perspective on aspects of neural functioning not captured by techniques such as neuroimaging and allowing for the interrogation of existing VH models and the development of novel interventions for VH.

Acknowledgments

This research was supported by a Randerson Foundation studentship awarded to KdSM; by a Fight for Sight/Thomas Pocklington Trust Small Grant Award (24TP172) to GJE, National Institute for Health Research (NIHR) Programme Grants for Applied Research (SHAPED RP-PG-0610-10100) and the NIHR Newcastle Biomedical Research Unit awarded to the Newcastle upon Tyne Hospitals NHS Foundation Trust and Newcastle University. The views expressed are those of the authors and not necessarily those of the NHS, the NIHR or the Department of Health.

Conflict of interest

None of the authors have any potential conflicts of interest to be disclosed.

References

- Abraham HD, Duffy FH. Stable quantitative EEG difference in post-LSD visual disorder by split-half analysis: evidence for disinhibition. *Psychiatry Res - Neuroimaging*. 1996;67:173–87.
- Abraham HD, Duffy FH. EEG coherence in post-LSD visual hallucinations. *Psychiatry Res - Neuroimaging*. 2001;107(3):151–63.
- Accornero N, Li Voti P, La Riccia M, Gregori B. Visual evoked potentials modulation during direct current cortical polarization. *Exp Brain Res*. 2007;178(2):261–6.
- Alves-Leon SV, Nunes RG, Andraus MEC, Junior JCB, Hemb M, Genofre MA. Clinical and electroencephalographic characteristics of benign occipital epilepsy of childhood in two tertiary Brazilian hospitals. *Arq Neuropsiquiatr*. 2011;69(4):648–53.
- Antal A, Kincses TZ, Nitsche MA, Bartfai O, Paulus W. Excitability changes induced in the human primary visual cortex by transcranial direct current stimulation: direct electrophysiological evidence. *Invest Ophthalmol Vis Sci*. 2004;45(2):702–7.
- Antal A, Kincses TZ, Nitsche MA, Paulus W. Manipulation of phosphene thresholds by transcranial direct current stimulation in man. *Neuropsychologia*. 2003;150:375–8.
- Armstrong R. Visual signs and symptoms of dementia with Lewy bodies. *Clin Exp Optom*. 2012;95:621–30.
- Aurora SK, Welch KMA, Al-Sayed F. The threshold for phosphenes is lower in migraine. *Cephalalgia*. 2003;23:258–63.
- Barry RJ, Clarke AR, Johnstone SJ, Magee CA, Rushby JA. EEG differences between eyes-closed and eyes-open resting conditions. *Clin Neurophysiol*. 2007;118:2765–73.
- Becker C, Gramann K, Müller HJ, Elliott MA. Electrophysiological correlates of flicker-induced color hallucinations. *Conscious Cogn*. 2009;18(1):266–76.
- Bernardin F, Schwan R, Lalanne L, Ligier F, Angioi-Duprez K, Schwitzer T, et al. The role of the retina in visual hallucinations: A review of the literature and implications for psychosis. *Neuropsychologia*. 2017;99(March):128–38.
- Blanke O, Landis T, Seeck M. Electrical cortical stimulation of the human prefrontal cortex evokes complex visual hallucinations. *Epilepsy Behav*. 2000;1(5):356–61.
- Bonanni L, Thomas A, Tiraboschi P, Perfetti B, Varanese S, Onofri M. EEG comparisons in early Alzheimer's disease, dementia with Lewy bodies and Parkinson's disease with dementia patients with a 2-year follow-up. *Brain*. 2008;131(3):690–705.
- Bosboom JLW, Stoffers D, Stam CJ, Berendse HW, Wolters EC. Cholinergic modulation of MEG resting-state oscillatory activity in Parkinson's disease related dementia. *Clin Neurophysiol*. 2009;120(5):910–5.
- Braithwaite JJ, Mevorach C, Takahashi C. Stimulating the aberrant brain: Evidence for increased cortical hyperexcitability from a transcranial direct current stimulation (tDCS) study of individuals predisposed to anomalous perceptions. *Cortex*. 2015;69:1–13.
- Brawley P, Duffield JC. The Pharmacology of Hallucinogens. *Pharmacol Rev*. 1972;34(1):31–66.

- Brunelin J, Mondino M, Gassab L, Haesebaert F, Gaha L, Suaud-Chagny MF, et al. Examining transcranial direct-current stimulation (tDCS) as a treatment for hallucinations in schizophrenia. *Am J Psychiatry*. 2012;169(7):719–24.
- Carhart-Harris RL, Muthukumaraswamy S, Roseman L, Kaelen M, Droog W, Murphy K, et al. Neural correlates of the LSD experience revealed by multimodal neuroimaging. *Proc Natl Acad Sci*. 2016;113(17):4853–8.
- Chambers CD, Stokes MG, Janko NE, Mattingley JB. Enhancement of visual selection during transient disruption of parietal cortex. *Brain Res*. 2006;1097:149–55.
- Chang Y-P, Yang Y-H, Lai C-L, Liou L-M. Event-Related Potentials in Parkinson's Disease Patients with Visual Hallucination. *Parkinsons Dis*. 2016;1–7.
- Chibbaro G, Daniele M, Alagona G, Di Pasquale C, Cannavò M, Rapisarda V, et al. Repetitive transcranial magnetic stimulation in schizophrenic patients reporting auditory hallucinations. *Neurosci Lett*. 2005;383:54–7.
- Cogan DG. Visual hallucinations as release phenomena. *Albr von Graefes Arch für Klin und Exp Ophthalmol*. 1973;188(2):139–50.
- Collerton D, Perry E, McKeith I. Why people see things that are not there: A novel Perception and Attention Deficit model for recurrent complex visual hallucinations. *Behav Brain Sci*. 2005;28(6):737–94.
- Cox TM, ffytche DH. Negative outcome Charles Bonnet Syndrome. *Br J Ophthalmol*. 2014;98(9):1236–9.
- Devos D, Tir M, Maurage CA, Waucquier N, Defebvre L, Defoort-Dhellemmes S, et al. ERG and anatomical abnormalities suggesting retinopathy in dementia with Lewy bodies. *Neurology*. 2005;65(7):1107–10.
- Diederich NJ, Alesch F, Goetz CG. Visual Hallucinations Induced by Deep Brain Stimulation in Parkinson's Disease. *Clin Neuropharmacol*. 2000;23(5):287–9.
- Diederich NJ, Goetz CG, Stebbins GT. Repeated Visual Hallucinations in Parkinson's Disease as Disturbed External/Internal Perceptions: Focused Review and a New Integrative Model. *Mov Disord*. 2005;20(2):130–40.
- Dudley R, Wood M, Spencer H, Brabban A, Mosimann UP, Collerton D. Identifying Specific Interpretations and Use of Safety Behaviours in People with Distressing Visual Hallucinations : An Exploratory Study. *Behav Cogn Psychother*. 2012;40:367–75.
- Duecker F, Sack AT. Rethinking the role of sham TMS. *Front Psychol*. 2015;6:1–5.
- Elder GJ, Taylor JP. Transcranial magnetic stimulation and transcranial direct current stimulation: Treatments for cognitive and neuropsychiatric symptoms in the neurodegenerative dementias? *Alzheimer's Res Ther*. 2014;6(74):1–11.
- Elliott MA, Twomey D, Glennon M. The dynamics of visual experience, an EEG study of subjective pattern formation. *PLoS One*. 2012;7(1):1–8.
- ffytche DH. The hodology of hallucinations. *Cortex*. 2008;44(8):1067–83.
- ffytche DH, Howard RJ, Brammer MJ, David A, Woodruff P, Williams S. The anatomy of conscious vision : an fMRI study of visual hallucinations. *Nature*. 1998;1(8):738–42.

- ffytche DH, Wible CG. From Tones in Tinnitus to Sensed Social Interaction in Schizophrenia : How Understanding Cortical Organization Can Inform the Study of Hallucinations and Psychosis. *Schizophr Bull.* 2014;40(4):305–16.
- Fitzgerald PB, Benitez J, Daskalakis JZ, De Castella A, Kulkarni J. The treatment of recurring auditory hallucinations in schizophrenia with rTMS. *world J Biol psychiatry.* 2006;7(2):119–22.
- Gaig C, Valldeoriola F, Gelpi E, Ezquerro M, Llufrui S, Buongiorno M, et al. Rapidly progressive diffuse Lewy body disease. *Mov Disord.* 2011;26(7):1316–23.
- Gomes JS, Dias AM, Scorza FA, Cordeiro Q, Sato IA, Akiba H, et al. Transcranial direct current stimulation for refractory major depressive disorder temporal lobe epilepsy: a quantitative electroencephalography study. *Epilepsy Behav.* 2017;72:205–7.
- Hanoglu L, Yildiz S, Polat B, Demirci S, Tavli A, Yilmaz N, et al. Therapeutic effects of rivastigmine and alfa-lipoic acid combination in Charles Bonnet Syndrome: Electroencephalography correlates. *Curr Clin Pharmacol.* 2016;11:270–3.
- Hilgetag CC, Theoret H, Pascual-leone A. Enhanced visual spatial attention ipsilateral to rTMS-induced “virtual lesions” of human parietal cortex. *Nature.* 2001;4(9):953–7.
- Hoffman RE, Boutros NN, Berman RM, Roessler E, Belger A, Krystal JH, et al. Transcranial magnetic stimulation of left temporoparietal cortex in three patients reporting hallucinated “voices.” *Biol Psychiatry.* 1999;46(1):130–2.
- Jardri R, Pins D, Bubrovsky M, Lucas B, Lethuc V, Delmaire C, et al. Neural functional organization of hallucinations in schizophrenia: Multisensory dissolution of pathological emergence in consciousness. *Conscious Cogn.* 2009;18(2):449–57.
- Jardri R, Thomas P, Delmaire C, Delion P, Pins D. The neurodynamic organization of modality-dependent hallucinations. *Cereb Cortex.* 2013;23(5):1108–17.
- Jolfaei AG, Naji B, Esfehiani MN. Repetitive Transcranial Magnetic Stimulation in Resistant Visual Hallucinations in a Woman With Schizophrenia : A Case Report. *Iran J Psychiatry Behav Sci.* 2016;10(1):10–2.
- Jonas J, Brissart H, Hossu G, Colnat-coulbois S, Vignal J-P, Rossion B, et al. A face identity hallucination (palinopsia) generated by intracerebral stimulation of the face-selective right lateral fusiform cortex. *Cortex.* 2018;99:296–310.
- Jonas J, Frismand S, Vignal JP, Colnat-Coulbois S, Koessler L, Vespignani H, et al. Right hemispheric dominance of visual phenomena evoked by intracerebral stimulation of the human visual cortex. *Hum Brain Mapp.* 2014a;35(7):3360–71.
- Jonas J, Maillard L, Frismand S, Colnat-Coulbois S, Vespignani H, Rossion B, et al. Self-face hallucination evoked by electrical stimulation of the human brain. *Neurology.* 2014b;83(4):336–8.
- Josephson SA, Kirsch HE. Complex visual hallucinations as post-ictal cortical release phenomena. *Neurocase.* 2006;12(2):107–10.
- Kaptchuk TJ, Miller FG. Placebo Effects in Medicine. *N Engl Med.* 2015;373(1):8–9.
- Kazui H, Ishii R, Yoshida T, Ikezawa K, Takaya M, Tokunaga H, et al. Neuroimaging studies in patients with Charles Bonnet Syndrome. *Psychogeriatrics.* 2009;9(2):77–84.

- Khedr EM, Ahmed MA, Mohamed KA. Motor and visual cortical excitability in migraineurs patients with or without aura: Transcranial magnetic stimulation. *Clin Neurophysiol.* 2006;36(1):13–8.
- Kim T-E, Kim H-J, Park J-H, Lee T-K, Lee JD, Park SA. Cognitive dysfunction with complex visual hallucinations due to focal nonconvulsive status epilepticus: a neuropsychological study and SISCOM. *Seizure [Internet].* 2012;21(8):658–60. Available from: <http://www.ncbi.nlm.nih.gov/pubmed/22832396>
- Kometer M, Cahn BR, Andel D, Carter OL, Vollenweider FX. The 5-HT_{2A/1A} agonist psilocybin disrupts modal object completion associated with visual hallucinations. *Biol Psychiatry.* 2011;69(5):399–406.
- Kometer M, Schmidt A, Jäncke L, Vollenweider FX. Activation of serotonin 2A receptors underlies the psilocybin-induced effects on α oscillations, N170 visual-evoked potentials, and visual hallucinations. *J Neurosci.* 2013;33(25):10544–51.
- Koops S, Sommer IEC. Transcranial direct current stimulation (tDCS) as a treatment for visual hallucinations: a case study. *Psychiatry Res.* 2017;258:616–7.
- Kurita A, Murakami M, Takagi S, Matsushima M, Suzuki M. Visual hallucinations and altered visual information processing in Parkinson disease and dementia with Lewy bodies. *Mov Disord.* 2010;25(2):167–71.
- Kurita A, Nakamura M, Suzuki M, Mochio S, Inoue K. Visual and auditory event-related potential comparisons between Parkinson's disease with dementia and Alzheimer's disease. *Int Congr Ser.* 2005;1278:57–60.
- Lee HW, Hong SCB, Seo DW, Tae WS, Hong SCB. Mapping of functional organization in human visual cortex: electrical cortical stimulation. *Neurology.* 2000;54(4):849–54.
- Lopez OL, Becker JT, Brenner RP, Rosen J, Bajulaiye OI, Reynolds CF. Alzheimer's disease with delusions and hallucinations: Neuropsychological and electroencephalographic correlates. *Neurology.* 1991;41(6):906–12.
- Lorberboym M, Lampl Y, Gilad R, Sadeh M. Tc-99m ethylcysteinate dimer brain SPECT perfusion imaging in ictal nonepileptic visual hallucinations. *Clin Nucl Med.* 2002;27(2):87–91.
- Manfioli V, Saladini M, Cagnin A. Ictal visual hallucinations due to frontal lobe epilepsy in a patient with bipolar disorder. *Epilepsy Behav Case Reports.* 2013;1:146–9.
- Manford M, Andermann F. Complex visual hallucinations: Clinical and neurobiological insights. *Brain.* 1998;121(10):1819–40.
- Manganelli F, Vitale C, Santangelo G, Pisciotta C, Iodice R, Cozzolino A, et al. Functional involvement of central cholinergic circuits and visual hallucinations in Parkinson's disease. *Brain.* 2009;132(9):2350–5.
- Marra C, Quaranta D, Profice P, Pilato F, Capone F, Iodice F, et al. Central cholinergic dysfunction measured “in vivo” correlates with different behavioral disorders in Alzheimer's disease and dementia with Lewy body. *Brain Stimul.* 2012;5(4):533–8.
- Matsui H, Uda F, Tamura A, Oda M, Kubori T, Nishinaka K, et al. The relation between visual hallucinations and visual evoked potential in Parkinson disease. *Clin Neuropharmacol.* 2005;28(2):79–82.

- Mckeith IG, Dickson DW, Lowe J, Emre M, Brien JTO, Feldman H, et al. Diagnosis and management of dementia with Lewy bodies: Third report of the DLB consortium. *Neurology*. 2005;65(12):1863–72.
- Mégevand P, Groppe DM, Goldfinger MS, Hwang ST, Kingsley PB, Davidesco I, et al. Seeing scenes: topographic visual hallucinations evoked by direct electrical stimulation of the parahippocampal place area. *J Neurosci*. 2014;34(16):5399–405.
- Menon GJ, Rahman I, Menon SJ, Dutton GN. Complex Visual Hallucinations in the Visually Impaired: The Charles Bonnet Syndrome. *Surv Ophthalmol*. 2003;48(1):58–72.
- Meppelink AM, de Jong BM, van der Hoeven JH, van Laar T. Lasting visual hallucinations in visual deprivation; fMRI correlates and the influence of rTMS. *J Neurol Neurosurg Psychiatry*. 2010;81(11):1295–6.
- Meppelink AM, de Jong BM, Renken R, Leenders KL, Cornelissen FW, van Laar T. Impaired visual processing preceding image recognition in Parkinson's disease patients with visual hallucinations. *Brain*. 2009;132:2980–93.
- Merabet LB, Kobayashi M, Barton J, Pascual-Leone A. Suppression of complex visual hallucinatory experiences by occipital transcranial magnetic stimulation: a case report. *Neurocase*. 2003;9(5):436–40.
- Murphy N, Killen A, Graziadio S, Rochester L, Taylor J. Evoked Potentials from Concurrent TMS-EEG Demonstrate Altered Visual Pathway Efficiency in Parkinson's Disease with Dementia. *Conf 13th Int Conf Alzheimer's Park Dis*. 2017;(March).
- Nitsche MA, Cohen LG, Wassermann EM, Priori A, Lang N, Antal A, et al. Transcranial direct current stimulation: State of the art 2008. *Brain Stimul*. 2008;1:206–23.
- Noda S, Mizoguchi M, Yamamoto A. Thalamic experiential hallucinosis. *J Neurol Neurosurg Psychiatry*. 1993;56:1224–6.
- Oertel V, Rotarska-Jagiela A, van de Ven VG, Haenschel C, Maurer K, Linden DEJ. Visual hallucinations in schizophrenia investigated with functional magnetic resonance imaging. *Psychiatry Res - Neuroimaging*. 2007;156(3):269–73.
- Oishi M, Otsubo H, Kameyama S, Wachi M, Tanaka K, Masuda H, et al. Ictal magnetoencephalographic discharges from elementary visual hallucinations of status epilepticus. *J Neurol Neurosurg Psychiatry*. 2003;74(4):525–7.
- Oliveri M, Calvo G. Increased visual cortical excitability in ecstasy users: a transcranial magnetic stimulation study. *J Neurol Neurosurg Psychiatry*. 2003;74(8):1136–8.
- Onofrj M, Bonanni L, Albani G, Mauro A, Bulla D, Thomas A. Visual hallucinations in Parkinson's disease: Clues to separate origins. *J Neurol Sci*. 2006;248:143–50.
- Onofrj M, Taylor JP, Monaco D, Franciotti R, Anzellotti F, Bonanni L, et al. Visual Hallucinations in PD and Lewy body dementias: Old and new hypotheses. *Behav Neurol*. 2013;27(4):479–93.
- Onofrj M, Thomas A, D'Andreamatteo G, Iacono D, Luciano AL, Di Rollo A, et al. Incidence of RBD and hallucination in patients affected by Parkinson's disease: 8-year follow-up. *Neurol Sci*. 2002;23:91–4.
- Ossola M, Romani A, Tavazzi E, Pichiecchio A, Galimberti CA. Epileptic mechanisms in

- Charles Bonnet syndrome. *Epilepsy Behav.* 2010;18(1–2):119–22.
- Penfield W, Perot P. The brain's record of auditory and visual experience. *Brain.* 1963;86(4):596–696.
- Peraza LR, Cromarty R, Kobeleva X, Firbank MJ, Killen A, Graziadio S, et al. Electroencephalographic derived network differences in Lewy body dementia compared to Alzheimer's disease patients. *Sci Rep.* 2018;8(4637):1–14.
- Pfurtscheller G, Stancak Jr A, Neuper C. Event-related synchronization (ERS) in the alpha band - an electrophysiological correlate of cortical idling: A review. *Int J Psychophysiol.* 1996;24:39–46.
- Pliskin NH, Kiolbasa TA, Towle VL, Pankow L, Ernest JT, Noronha A, et al. Charles Bonnet syndrome: an early marker for dementia? *J Am Geriatr Soc.* 1996;44(9):1055–61.
- Ponsen MM, Stam CJ, Bosboom JLW, Berendse HW, Hillebrand A. A three dimensional anatomical view of oscillatory resting-state activity and functional connectivity in Parkinson's disease related dementia : An MEG study using atlas-based beamforming. *NeuroImage Clin.* 2013;2:95–102.
- Rafique SA, Richards JR, Steeves JKE. rTMS reduces cortical imbalance associated with visual hallucinations after occipital stroke. *Neurology.* 2016;87(14):1493–500.
- Romei V, Brodbeck V, Michel C, Amedi A, Pascual-Leone A, Thut G. Spontaneous Fluctuations in Posterior α -Band EEG Activity Reflect Variability in Excitability of Human Visual Areas. *Cereb Cortex.* 2008;18:2010–8.
- Santhouse AM, Howard RJ, ffytche DH. Visual hallucinatory syndromes and the anatomy of the visual brain. *Brain.* 2000;123:2055–64.
- Schulz R, Woermann FG, Ebner A. When written words become moving pictures: Complex visual hallucinations on stimulation of the lateral occipital lobe. *Epilepsy Behav.* 2007;11(1):147–51.
- Schwartzman D, Maravic K, Kranczoch C, Barnes J. Altered early visual processing components in hallucination-prone individuals. *Neuroreport.* 2008;19(9):933–7.
- Shine JM, Halliday GM, Naismith SL, Lewis SJG. Visual Misperceptions and Hallucinations in Parkinson's Disease: Dysfunction of Attentional Control Networks? *Mov Disord.* 2011;26(12):2154–9.
- Shiozawa P, Da Silva ME, Cordeiro Q. Transcranial direct current stimulation (tDCS) for the treatment of persistent visual and auditory hallucinations in schizophrenia: A case study. *Brain Stimul.* 2013;6(5):831–3.
- Sowa M V, Pituck S. Prolonged Spontaneous Complex Visual Hallucinations and Illusions as Ictal Phenomena. *Epilepsia.* 1989;30(5):524–6.
- Stagg CJ, Nitsche MA. Physiological Basis of Transcranial Direct Current Stimulation. *Neuroscientist.* 2011;17(1):37–53.
- Stebbins GT, Goetz CG, Carrillo MC, Bangen KJ, Turner DA, Glover GH, et al. Altered cortical visual processing in PD with hallucinations: an fMRI study. *Neurology.* 2004;63(8):1409–16.
- Sun L, Cao J, Chu FN, Wang Z, Lv Y. Dementia with Lewy bodies versus nonconvulsive

- status epilepticus in the diagnosis of a patient with cognitive dysfunction, complex visual hallucinations and periodic abnormal waves in EEG: a case report. *BMC Neurol.* 2014;14(112):1–4.
- Taylor J-P, Firbank M, Barnett N, Pearce S, Livingstone A, Mosimann U, et al. Visual hallucinations in dementia with Lewy bodies: transcranial magnetic stimulation study. *Br J Psychiatry.* 2011;199(6):492–500.
- Taylor J, Firbank MJ, He J, Barnett N, Pearce S, Livingstone A, et al. Visual cortex in dementia with Lewy bodies : magnetic resonance imaging study. *Br J Psychiatry.* 2012;200:491–8.
- Taylor JP, Firbank M, O'Brien JT. Visual cortical excitability in dementia with Lewy bodies. *Br J Psychiatry.* 2016;208:497–8.
- Thut G, Nietzel A, Brandt SA, Pascual-leone A. α -Band Electroencephalographic Activity over Occipital Cortex Indexes Visuospatial Attention Bias and Predicts Visual Target Detection. *J Neurosci.* 2006;26(37):9494–502.
- Tombini M, Pellegrino G, Zappasodi F, Quattrocchi CC, Assenza G, Melgari JM, et al. Complex visual hallucinations after occipital extrastriate ischemic stroke. *Cortex.* 2012;48(6):774–7.
- Vercammen A, Knegtering H, Liemburg EJ, Boer JA den, Aleman A. Functional connectivity of the temporo-parietal region in schizophrenia: Effects of rTMS treatment of auditory hallucinations. *J Psychiatr Res.* 2010;44(11):725–31.
- Vignat JP, Chauvel P, Halgren E. Localised Face Processing By the Human Prefrontal Cortex: Stimulation-Evoked Hallucinations of Faces. *Cogn Neuropsychol.* 2000;17(1–3):281–91.
- Vignat JP, Maillard L, McGonigal A, Chauvel P. The dreamy state: Hallucinations of autobiographic memory evoked by temporal lobe stimulations and seizures. *Brain.* 2007;130(1):88–99.
- Weil RS, Schrag AE, Warren JD, Crutch SJ, Lees AJ, Morris HR. Visual dysfunction in Parkinson's disease. *Brain.* 2016;1–17.
- Yalçın AD, Kaymaz A, Forta H. Reflex occipital lobe epilepsy. *Seizure.* 2000;9(6):436–41.

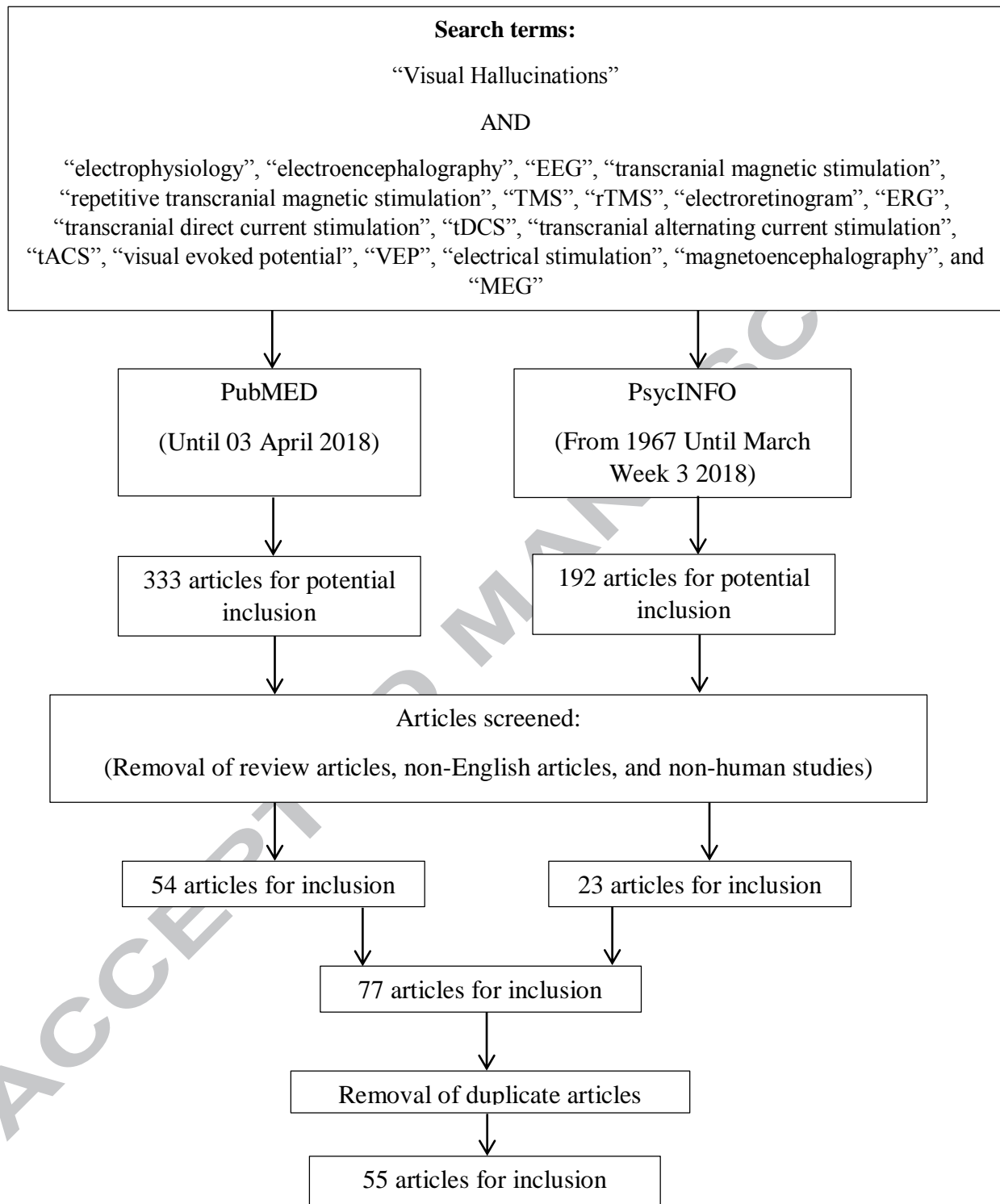


Figure 1. Review search strategy, including search terms, number of articles included, and number of articles containing specific electrophysiological techniques or VH pathologies.

ACCEPTED MANUSCRIPT



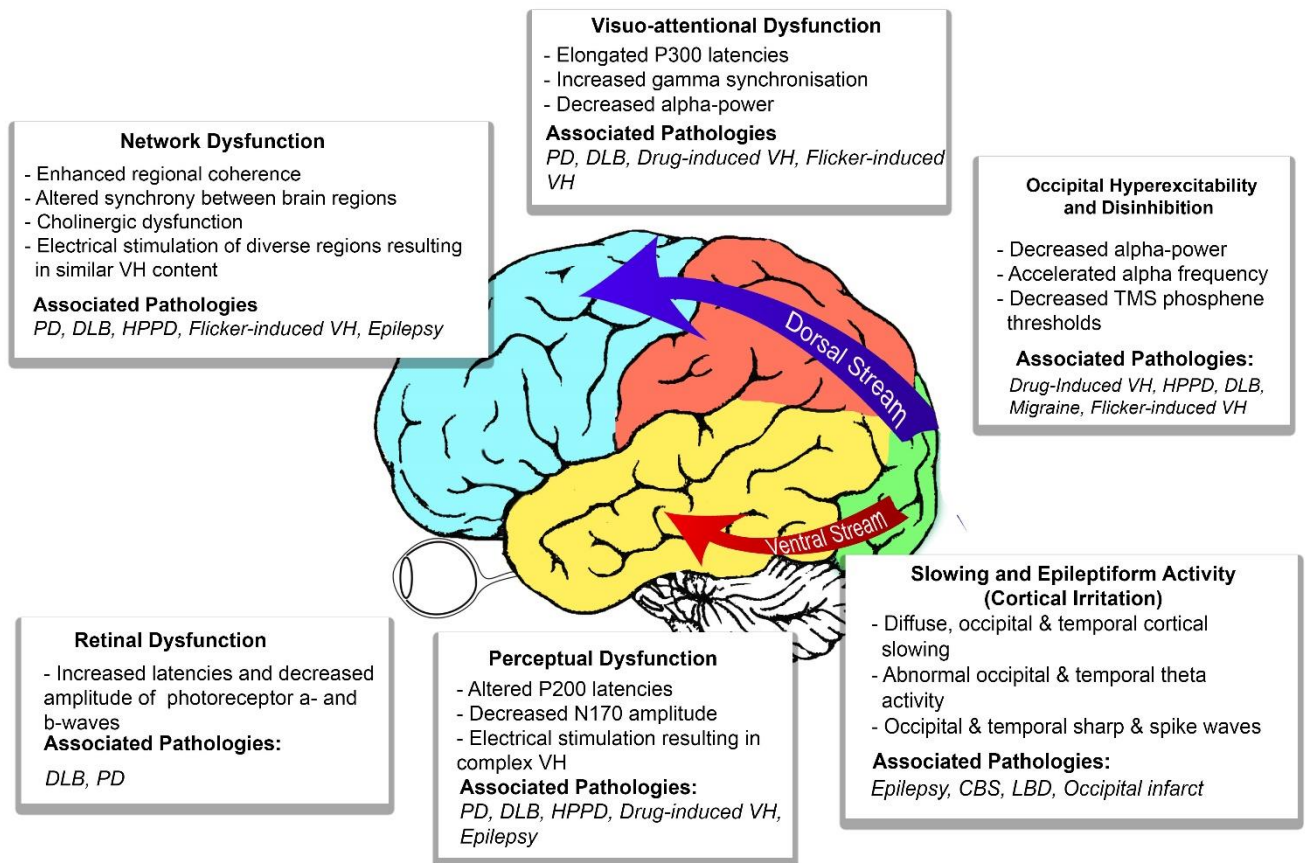


Figure 2. Summary of widespread visual system dysfunction observed across VH-prone pathologies including related regions and visual processing streams.

ACCEPTED MANUSCRIPT