



King's Research Portal

DOI:

[10.1016/j.critrevonc.2018.02.012](https://doi.org/10.1016/j.critrevonc.2018.02.012)

Document Version

Peer reviewed version

[Link to publication record in King's Research Portal](#)

Citation for published version (APA):

Gariani, J., Westerland, O., Natas, S., Verma, H., Cook, G., & Goh, V. (Accepted/In press). Comparison of whole body magnetic resonance imaging (WBMRI) to whole body computed tomography (WBCT) or 18F-fluorodeoxyglucose positron emission tomography/CT (18F-FDG PET/CT) in patients with myeloma: Systematic review of diagnostic performance. *Critical Reviews in Oncology/Hematology*.
<https://doi.org/10.1016/j.critrevonc.2018.02.012>

Citing this paper

Please note that where the full-text provided on King's Research Portal is the Author Accepted Manuscript or Post-Print version this may differ from the final Published version. If citing, it is advised that you check and use the publisher's definitive version for pagination, volume/issue, and date of publication details. And where the final published version is provided on the Research Portal, if citing you are again advised to check the publisher's website for any subsequent corrections.

General rights

Copyright and moral rights for the publications made accessible in the Research Portal are retained by the authors and/or other copyright owners and it is a condition of accessing publications that users recognize and abide by the legal requirements associated with these rights.


- Users may download and print one copy of any publication from the Research Portal for the purpose of private study or research.
- You may not further distribute the material or use it for any profit-making activity or commercial gain
- You may freely distribute the URL identifying the publication in the Research Portal

Take down policy

If you believe that this document breaches copyright please contact librarypure@kcl.ac.uk providing details, and we will remove access to the work immediately and investigate your claim.

Accepted Manuscript

Title: Comparison of whole body magnetic resonance imaging (WBMRI) to whole body computed tomography (WBCT) or ¹⁸F-fluorodeoxyglucose positron emission tomography/CT (¹⁸F-FDG PET/CT) in patients with myeloma: Systematic review of diagnostic performance



Authors: Joanna Gariani, Olwen Westerland, Sarah Natas, Hema Verma, Gary Cook, Vicky Goh

PII: S1040-8428(17)30541-3
DOI: <https://doi.org/10.1016/j.critrevonc.2018.02.012>
Reference: ONCH 2509

To appear in: *Critical Reviews in Oncology/Hematology*

Received date: 3-7-2017
Revised date: 5-12-2017
Accepted date: 22-2-2018

Please cite this article as: Gariani Joanna, Westerland Olwen, Natas Sarah, Verma Hema, Cook Gary, Goh Vicky. Comparison of whole body magnetic resonance imaging (WBMRI) to whole body computed tomography (WBCT) or ¹⁸F-fluorodeoxyglucose positron emission tomography/CT (¹⁸F-FDG PET/CT) in patients with myeloma: Systematic review of diagnostic performance. *Critical Reviews in Oncology and Hematology* <https://doi.org/10.1016/j.critrevonc.2018.02.012>

This is a PDF file of an unedited manuscript that has been accepted for publication. As a service to our customers we are providing this early version of the manuscript. The manuscript will undergo copyediting, typesetting, and review of the resulting proof before it is published in its final form. Please note that during the production process errors may be discovered which could affect the content, and all legal disclaimers that apply to the journal pertain.

Title page:

Comparison of whole body magnetic resonance imaging (WBMRI) to whole body computed tomography (WBCT) or ^{18}F -fluorodeoxyglucose positron emission tomography/CT (^{18}F -FDG PET/CT) in patients with myeloma: Systematic review of diagnostic performance and impact on management

^{1,2}Joanna Gariani

^{1,3}Olwen Westerland

^{1,3}Sarah Natas

^{1,3}Hema Verma

^{1,4}Gary Cook

^{1,3}Vicky Goh

¹Cancer Imaging, Division of Imaging Sciences & Biomedical Engineering, King's College London

²Division of Radiology, Department of Imaging and Medical Information Sciences, Geneva University Hospitals, Geneva, Switzerland

³Department of Radiology, Guy's & St Thomas' NHS Foundation Trust, London

⁴The PET Centre, St Thomas' Hospital, London

Corresponding author:

Vicky Goh
Radiology, Level 1, Lambeth Wing
St Thomas' Hospital
Westminster Bridge Road,
London
SE1 7EH

Email: vicky.goh@kcl.ac.uk

Tel: +44 207 188 5538

Highlights:

- Current imaging studies are limited by methodological heterogeneity, potential accrual bias and lack of an independent reference standard for lesions
- Meta-analysis is not possible currently due to the quality of studies to date.
- Further prospective research is required to assess the impact on management

Abstract

Objectives: To undertake a systematic review to determine the diagnostic performance of whole body MRI (WBMRI) including diffusion weighted sequences (DWI) compared to whole body computed tomography (WBCT) or ^{18}F -fluorodeoxyglucose positron emission tomography/CT (^{18}F -FDG PET/CT) in patients with myeloma.

Methods: Two researchers searched the primary literature independently for WBMRI studies of myeloma. Data were extracted focusing on the diagnostic ability of WBMRI versus WBCT and ^{18}F -FDG PET/CT. Meta-analysis was intended.

Results: 6 of 2857 articles were eligible that included 147 patients, published from 2008-2016. Studies were heterogeneous including both newly diagnosed & relapsed patients. All were single centre studies. Four of the six studies (66.7%) accrued prospectively and 5/6 (83.3%, 3 prospective) included WBMRI and ^{18}F -FDG PET/CT. Three of seven (42.9%) included DWI. The lack of an independent reference standard for individual lesions was noted in 5/6 (83.3%) studies. Studies reported that WBMRI detected more lesions than ^{18}F -FDG PET/CT (sensitivity 68-100% versus 47-100%) but was less specific (specificity 37-83% versus 62-85.7%). No paper assessed impact on management.

Conclusions: Studies were heterogeneous, the majority lacking an independent reference standard. Future prospective trials should address these limitations and assess the impact of WBMRI on management.

Key words:

Multiple myeloma, whole-body MRI, ^{18}F -FDG PET/CT, whole-body CT, DWI

1. INTRODUCTION

Myeloma is a haematological malignancy characterised by the clonal proliferation of plasma cells and excessive monoclonal protein in the blood and/or urine. For many patients, it is a debilitating disease causing unremitting bone pain and pathological

fractures with a 5 year survival rate of 47% [1]. Diagnosis of active multiple myeloma as defined by the IMWG classically relies on histological confirmation of plasma cell infiltration of the bone marrow with clonal bone marrow plasma cells $\geq 10\%$ (or extramedullary plasmacytoma) and any one of the following CRAB (calcium, renal, anaemia, bone) features: hypercalcaemia, renal insufficiency, anaemia and bone lesions. Almost all cases of myeloma are preceded by a premalignant asymptomatic stage, monoclonal gammopathy of undetermined significance (MGUS) [2; 3]. The trigger for progression from MGUS to myeloma is poorly understood but multifactorial including genetic mutations and alterations in the bone marrow microenvironment favouring clonal proliferation [4; 5].

The role of imaging in myeloma has evolved in recent years due to the increasing availability of high platform imaging: computed tomography (CT), magnetic resonance imaging (MRI) and integrated positron emission tomography/CT (PET/CT)[6-19]. There is currently a lack of reference standard for lesions. Although skeletal survey is accepted by the EMN imaging algorithm, CT has now been integrated into the diagnostic criteria and has been shown to be more sensitive in the detection of lesions and easy to perform [20; 21]. Since myeloma can affect any marrow-containing bone, an assessment of the whole skeleton by cross-sectional imaging is required in patients with either 10 – 60% plasma cells on their biopsy or an M-protein of $\geq 30\text{g/L}$. It is recognised that the axial skeleton is the main site of disease in the majority of patients [22] with only 10% of patients present with extra-axial disease only. Extra-medullary involvement in myeloma is rare, estimated to be around 3.4% at diagnosis [23] and is associated with a poor prognosis.

The new International Myeloma Working Group (IMWG) definition of myeloma includes the presence more than one unequivocal focal lesion ($\geq 5\text{mm}$) by cross-

sectional imaging as a diagnostic criterion for myeloma [24]. Nevertheless, it remains unclear which cross-sectional imaging modality is advantageous at initial assessment and what their impact on subsequent management is. To this end we performed a systematic review of the available medical literature, focussing on the diagnostic performance of whole body MRI (WBMRI) including diffusion weighted imaging (DWI) compared to whole body computed tomography (WBCT) and ^{18}F -fluorodeoxyglucose positron emission tomography/CT (^{18}F -FDG PET/CT) in the initial assessment of myeloma, to identify if there is sufficient evidence for WBMRI to replace WBCT or ^{18}F -FDG PET/CT, and the impact of WBMRI on subsequent management.

2. METHODS

2.1. Data sources and search strategy

Inclusion criteria

We identified primary studies comparing WBMRI \pm DWI with ^{18}F -FDG PET/CT or WBCT in the diagnosis of patients with myeloma. PUBMED and EMBASE databases were included in the literature search. We combined terms in the following search string to identify relevant studies:

“Myeloma, multiple myeloma, smouldering myeloma, whole body MRI, whole body magnetic resonance imaging, magnetic resonance imaging, MRI, diffusion weighted MRI, DWI, DW-MRI, ^{18}F -FDG PET/CT, ^{18}F -FDG positron emission tomography, PET, whole body CT, whole body computed tomography, CT”.

Exclusion criteria

Results were then limited to humans (using: AND "humans"[MeSH Terms]), limited to English and French language (using: AND English[lang], AND French[lang]). We used the systematic review filter (AND pmh_sr[sb]) to identify prior systematic reviews and reviewed the initial search (i.e. excluding filters) to identify any articles excluded incorrectly.

Electronic abstracts of identified studies were read and the following exclusion criteria applied. Case reports, small cases series (less than 10 patients), narrative reviews, letters/correspondence and conference abstracts were excluded since these would not contribute sufficient unbiased data able to answer our research question. Studies outwith of the diagnostic setting were also excluded. An excluded study log recorded reasons for exclusions.

The search was performed by 2 radiologists with a specialist interest in oncological imaging (>7 & 15 years' imaging experience, respectively) and any disagreement was resolved by consensus.

2.2. Data Extraction

Data were extracted from full articles by each radiologist independently into a database (Excel, Microsoft, Redmond WA). For each article, the first author, publication year, primary characteristics of the study (sample size, age, gender, single or multicentre study, and whether accrual was prospective or retrospective), imaging parameters (type of imaging, scanning sequence, MRI field strength, DWI b value, tracer administered activity, analysis technique) reference standard and diagnosis method were recorded. We designated WBMRI including diffusion weighted sequences as the index test. We designated WBCT as the imaging reference standard for the analysis of focal lesions.

2.3. Quality Assessment

To assess the quality of the eligible studies in terms of generalisability and risk of bias, the quality assessment for studies of diagnostic accuracy tool (QUADAS-2) [25] was utilised covering the following domains: patient selection, index test, reference standard, and flow of patients through each study. Questions within each of the domains was scored as 'yes', 'no' or 'unclear'. Factors such as study design (retrospective or prospective), reference standard or imaging characteristics (1.5T or 3T-MRI, DWI b-value, skeletal coverage) were assessed for potential bias/heterogeneity.

2.4. Meta-analysis

We intended at outset to perform a meta-analysis to obtain pooled estimate of sensitivity and specificity. However meta-analysis was prevented by the small number of studies retrieved that presented adequate data, combined with excessive methodological heterogeneity.

3. RESULTS

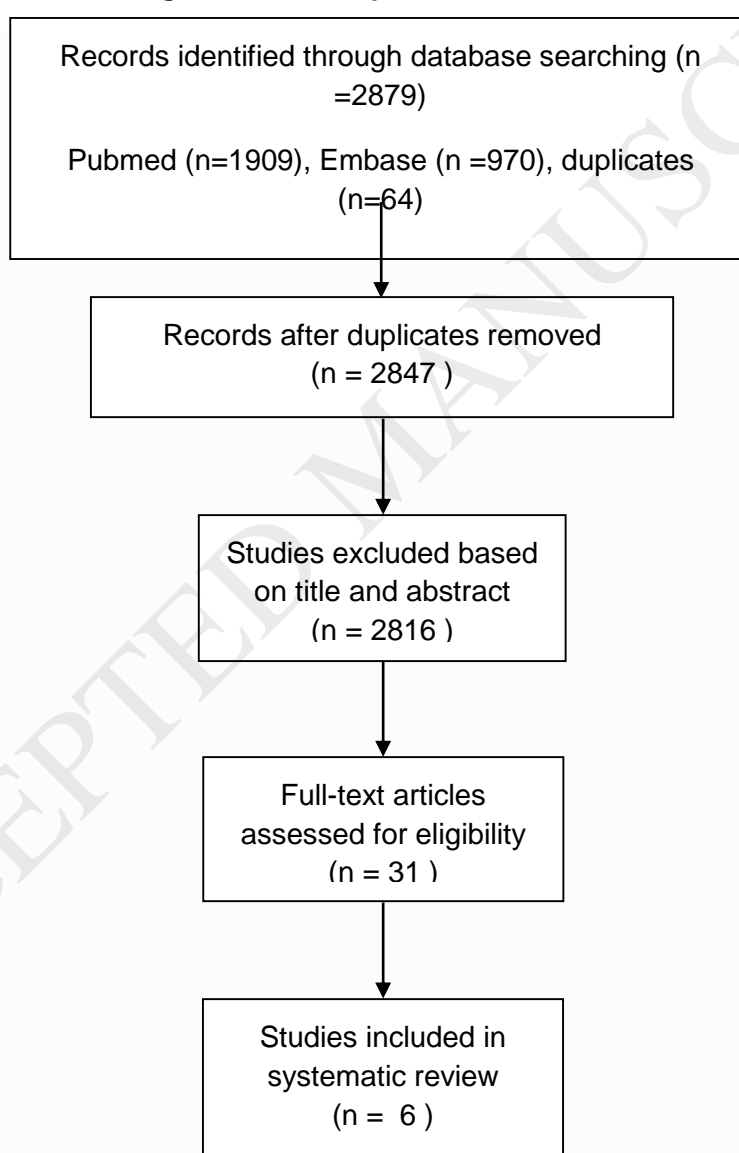
We followed PRISMA guidelines for transparent reporting of systematic reviews.

3.1. Eligible studies

The initial search performed on 6 January 2017 yielded 2879 articles, after removing duplicates 2847 remained. 2816 articles were excluded following evaluation of abstracts. The remaining 31 articles were retrieved in full text, and eventually 6/31 (19.4%) studies were included in the systematic review [26-32], of which 5/6

(83.3%) compared WBMRI with ^{18}F -FDG PET/CT and 1/6 (16.7%) with WBCT; 3/6 (50.0%) included DWI. The PRISMA flow chart is shown in Figure 1. Four of the 6 (66.7%) studies were performed prospectively. Two of the 6 (33.3%) studies reported imaging results at diagnosis, the remainder included imaging at both diagnosis and during follow-up. Five of the 6 (83.3%) studies compared WBMRI to ^{18}F -FDG PET/CT. The remaining study compared WBMRI with WBCT.

Figure 1. Flow of studies through the selection process.



3.2. Patient population

Characteristics for included studies are described in Table 1.1. 147 patients were included in the studies with an individual range between 19 and 41. All of the studies enrolled patients with a diagnosis of myeloma but included both new and previously treated relapsed patients; 1 study also included patients with MGUS. Patient age range was 39 to 88 years. Of studies stating gender, 61 (48%) patients were male. None were multicentre studies. Spectrum bias influencing patient accrual was potentially present in 2/6 studies (33.3%) as accrual was retrospective and relied upon identifying patients via a database and keyword search. All identified studies were European in origin (Germany, Italy, France, UK, Republic of Ireland).

Table 1. Study Characteristics

Author Year Sample size	Patient type	Timing of imaging	Single or Multi- Centr e	Accrual	Index Test	Reference Test Lesions	MR Field Strengt h (Tesla)	MRI Sequence	DWI b- value s/mm ²	FDG Tracer administere d activity MBq
Baur- Melnyk 2008 n=41	Myelo ma	Diagnosis	Single	Prospective	MRI	CT	1.5	STIR T1	N/A	N/A
Shortt 2009 n=24	Myelo ma	Diagnosis Follow-up	Single	Prospective	MRI, 18F- FDG PET/C T	None	1.5	STIR T1	N/A	250-440
Cascini 2013 n=22	Myelo ma	Diagnosis Follow-up	Single	Prospective	MRI 18F- FDG PET/C T	None	1.5	STIR T1	N/A	370
Sachpekidi 2015 n=24	Myelo ma	Diagnosis Follow-up	Single	Prospective	DWI, 18F- FDG PET/C T	CT of PET/CT	3	STIR T1 T2 DWI	0, 800	
Brillet 2012	Myelo ma	Diagnosis	Single	Retrospectiv e	MRI 18F-	None	1.5	STIR T1	0, 800	5*

n=19	MGUS				FDG PET/C T			DWI		
Pawlyn 2016 n=17	Myelo ma	Diagnosis Follow-up	Single	Retrospectiv e	MRI 18F- FDG PET/C T	None	1.5	DWI	50, 900	400

MRI Sequence: STIR: Short tau inversion recovery, DWI: Diffusion weighted imaging; *5MBq/kg

3.3. Quality assessment

Methodological quality as assessed using the QUADAS criteria are presented in Figure 2. Selection criteria was clearly described in 5/6 studies (83.3%). With respect to the index test in 5/6 studies, 2 index tests were used. While all studies included biopsy-proven myeloma patients, in 4/6 studies an independent imaging reference test was not used for lesions identified and this constituted a major limitation. In 1 study CT was used as an independent reference standard, however, the time period between the index and reference test was only stated in 1 study and CT only performed independently in 1 study. A blinding method was not used during interpretation of the index test and reference standard; thus there was a clear risk of bias.

	Risk of bias				Applicability concerns		
	Patient selection	Index test	Reference standard	Flow timing and	Patient selection	Index test	Reference standard
Baur-Melnyk et al.	+	+	+	+	+	-	-
Brillet et al.	+	-	-	-	+	-	+
Cascini et al.	+	?	?	-	+	-	+
Pawlyn et al.	?	?	?	?	?	-	+
Sachpekidis et al.	+	-	-	+	+	-	-
Shortt al.	+	?	-	+	+	-	+

+ = yes, - = no, ? = unclear

Figure 2. QUADAS-2 Quality assessment

	Risk of bias				Applicability concerns
	Patient selection	Index test	Reference standard	Flow and timing	Patient selection
Baur-Melnyk et al.	+	+	+	+	+
Brillet et al.	+	-	-	-	+
Cascini et al.	+	?	?	-	+
Pawlyn et al.	?	?	?	?	?
Sachpekidis et al.	+	-	-	+	+
Shortt al.	+	?	-	+	+

There was heterogeneity in imaging acquisition (Table 2). The majority of MRI was performed at 1.5T (5/6, 83.3%) with skeletal coverage from skull vertex to ankles in 3/6, 50.0%) and to mid-thigh in the remainder. Individual MRI sequences varied in each study: short tau inversion recovery (STIR) and T1 spin echo (SE) or turbo spin echo (TSE) were performed most commonly. DWI b-values were either 0,800 s/mm² or 50, 900 s/mm² in 50% respectively.

Table 2. WB MRI, ¹⁸F-FDG PET/CT & CT Acquisition Characteristics

Author Year Sample size	MR Field Strength (Tesla)	MRI Sequence	Standard MRI Orientation Slice thickness	Coverage	DWI Orientation Slice thickness	DWI b- value s/mm ²	FDG Tracer Dose MBq	CT component Orientation Slice thickness
Baur-Melnyk 2008 n=41	Siemens 1.5	STIR T1 SE	Axial STIR/T1: Skull Coronal STIR/T1: Thorax, Pelvis, Legs	Skull Vertex to ankles	N/A	N/A	N/A	Axial 3mm*

			Sagittal STIR/T1: Spine 5mm					
Shortt 2009 n=24	Phillips 1.5	STIR T1 TSE	Axial STIR: Whole body Coronal STIR: Whole body Sagittal T1: Whole body 8mm	Skull Vertex to ankles	N/A	N/A	250-440	Axial Not specified
Cascini 2013 n=22	Phillips 1.5	STIR T1 TSE	Coronal STIR: Whole body Sagittal T1: Spine Not specified	Skull Vertex to ankles	N/A	N/A	370	Axial Not specified
Sachpekidis 2015 n=24	3	STIR T1 TSE T2 TSE DWI	Coronal STIR: Whole body Coronal T1: Whole body Sagittal T1: Whole body Sagittal T2: Whole body 5mm (cor) 3mm (sag)	Skull Vertex to mid-thigh	Axial DWI: Whole body	0,800	Not specified	Axial Not specified
Brillet 2012 n=19	1.5	STIR T1 TSE DWI	Coronal STIR: Whole body Sagittal T1: Spine	Skull vertex to mid-thigh	Axial DWI: Whole body	800	5+	Axial 3.75mm
Pawlyn 2016 n=17	1.5	DWI	N/A	Skull vertex to knees	Axial DWI: Whole body	50,900	400	Axial Not specified

SE: spin echo; TSE: turbo spin echo, STIR: short tau inversion recovery, DWI: diffusion weighted imaging

*CT performed separately; + MBq/kg body weight

3.4. Diagnostic accuracy

WBMRI versus ¹⁸F-FDG PET/CT

5 studies compared WBMRI to ¹⁸F-FDG PET/CT; of these 3/5 (60%) studies used DWI in their MRI protocol. PET/CT tracer administered activity varied from 250-440

MBq FDG. Only 1/5 (20%) included the CT component of the PET/CT as a reference standard for assessing lesions. The remaining studies did not state a reference standard for lesions. ^{18}F -FDG PET/CT lesions were defined as a focal increase in uptake or a diffuse pattern. Individual studies reported MRI to be more sensitive in lesion detection than PET/CT (Table 3) (sensitivity 68-100% versus 47-100%) but less specific (specificity 37-83% versus 62-85.7%).

Table 3. Diagnostic accuracy

Author Year Sample size	Sites assessed	Assessment method	Comparison test	WBMRI Sensitivity Specificity	^{18}F -FDG PET/CT - WBCT Sensitivity Specificity	Study Limitations
Baur-Melnyk 2008 n=41	Skull vertex to ankles	Consensus reading by 2 radiologists. Skeleton divided into 61 regions, each region evaluated for myeloma involvement.	CT	N/A	N/A	
Shortt 2009 n=24	Skull vertex to ankles	Independent reading by 2 radiologists, marrow involvement was compared to bone marrow aspiration and biopsy results.	PET-CT	68% 83%	59% 75%	Lack of imaging reference test
Cascini 2013 n=22	Skull vertex to ankles	Pattern of bone marrow involvement recorded at baseline and compared to bone marrow aspiration and biopsy. Second reading assessed treatment response.	PET-CT	100% / 100% / 100% / 60%*	100% / 82% 78% / 80% *	Lack of imaging reference test
Sachpekidis 2015 n=24	Skull vertex to mid- thigh	Visual analysis for suspicious foci of myeloma performed by 2 nuclear medicine physicians and 2 radiologists.	CT	77% * 90% **	47%* 90% **	
Brillet 2012 n=19	Skull vertex to mid- thigh	Visual analysis for suspicious lesions performed by a nuclear medicine physician and a radiologist independently.	PET-CT	100% 37%	100% 62%	Lack of imaging reference test
Pawlyn 2016	Skull vertex to knees	Consensus reading by 2 radiologists for defined body	PET-CT	N/A	N/A	Lack of imaging reference

n=17		regions to assess disease burden. Compared to bone marrow results.				test
------	--	--------------------------------------------------------------------	--	--	--	------

*after treatment

** mixed population (before and after treatment)

WBMRI versus WBCT

Only 1 study has compared WBMRI to WBCT. The detection rate of bone lesions on WBMRI to WBCT in these 41 patients at diagnosis were statistically higher with understaging in 11 patients with WBCT (Table 3).

3.5. Impact on management

No study assessed impact on initial management thus current data are insufficient to draw any conclusions on the impact on management.

4. DISCUSSION

The limitations of skeletal survey and WBCT for the assessment of myeloma are well known and have been documented previously [33]. In particular, these techniques detect bone destruction and thus have a limited ability for marrow infiltration [26-32]. This has led to other imaging methods that can detect marrow involvement to be considered within the patient pathway including WBMRI and 18F-FDG PET/CT, with the aim of ruling in disease (i.e. a sensitive test with a minimal proportion of false negatives).

Advances in imaging technology have reduced the acquisition time of WBMRI and allowed for sequences such as DWI to be incorporated within an acceptable on-table time. The introduction of multichannel coils, higher gradient amplitudes, introduction

of parallel imaging, and improved sequences including echo planar imaging have benefited DWI in particular. WBMRI with DWI in patients with myeloma aims to maximise detection of diffuse marrow infiltration as well as focal lesions and extra-osseous disease yet maintaining anatomical detail [34]. Several studies have already documented the potential of whole-body DWI, particularly for staging other tumour entities [35-39].

Hillengass et al. investigated the prognostic significance of focal lesions in WBMRI in asymptomatic patients and showed that the presence of lesions in a number greater than 1 were the strongest adverse prognostic factors for progression to symptomatic MM [46]. All of these groups used clinical criteria as reference standards; there was no imaging reference standard used.

The diagnostic criteria for myeloma were revised and published in 2014 by the International Myeloma Working Group (IMWG). Apart from the CRAB criteria, three biomarkers of malignancy have been included as myeloma defining events. The presence of at least one of these biomarkers will be sufficient to diagnose myeloma regardless of the CRAB criteria. These biomarkers are more than one lesion measuring ≥ 5 mm on MRI studies, clonal bone marrow cell plasma percentage $\geq 60\%$, serum involved/uninvolved free light chain ration of 100 or greater [24]. The IMWG also recommends the use of low-dose WBCT, ^{18}F -FDG PET/CT or WBMRI in the initial work-up of patients with smouldering MM [47].

This systematic review confirms the lack of robust imaging evidence to support clinical practice. The impact of imaging on management has not been analysed by

any of the studies identified and included in this systematic review. The published data suggest that WB-MRI is more sensitive but less specific than ¹⁸F-FDG PET/CT. The papers included did not provide lesion verification by either biopsy or follow-up of individual lesions. However, we found that the existing single centre studies were extremely heterogeneous with a mixed population of patients (newly diagnosis/pre-treated myeloma), anatomical variation in imaging coverage of the skeleton, variations in acquisition protocols used and a problematic lack of independent reference standard for individual lesions.

The inclusion of both newly diagnosed and post therapy patients will also contribute to the lower specificity of WB-MRI as anatomical changes after treatment take longer to normalise (up to 12 months) and may mask new sites of disease. The use of limited anatomical MRI sequences, most commonly STIR and T1 SE or TSE also contribute to the lack of specificity, limiting lesion characterisation. Further study of newer sequences including T1 DIXON (allowing the generation of separate fat and proton weighted images in addition to the standard T1-weighted in and opposed phase images, and thus providing different contrast) are warranted for this.

The use of intravenous contrast administration should also be considered in future given the neovascularisation associated with diffuse bone marrow involvement in myeloma [48], although it is recognised that in a proportion of patients this will not be possible due to underlying renal impairment. Initial studies have explored the use of contrast enhancement and dynamic contrast enhancement [40; 41; 48-52] and shown that there is an increased microvessel density resulting in higher contrast enhancement in some myeloma patients with a good agreement in staging when

comparing contrast enhanced T1-sequences with both DWI and clinical data. Whole-body MRI with contrast enhancement has also been used as a tool in treatment assessment.

Another major consideration is the use of multiple index tests and lack of a good reference standard in all studies which included WBMRI and ^{18}F -FDG PET/CT. The lack of blinding between index tests and between index test and a non-independent reference standard will introduce further bias. No studies performed histological confirmation of focal lesions. This has to be addressed in future studies.

The lack of multicentre data is also of concern. Single centre studies are typically from centres with strong expertise. At present WBMRI remains untested in the multicentre setting and its generalisability is unknown. The technical challenges of multiple scanners, multiple vendors, different magnet strengths, and sequences are known to influence MRI quality and can impact on diagnostic accuracy. As yet there are no published data in this arena.

The role and technical aspects of DWI also need to be further evaluated. Of the studies included only 4/6 performed DWI using either b-values of 0,800 and 50, 900 s/mm^2 in each of 2 studies, respectively. Only 2 b-values are typically used in WB DWI studies due to the acquisition time related to using >2 b-values. Lower b-value images have a higher signal-to-noise ratio (SNR) but are influenced by perfusion effects; higher b-values highlight the differences in diffusion of a tissue or lesion but have an inferior SNR [53].

There are currently no guidelines concerning the most appropriate b-value in this clinical setting. The National Cancer Institute consensus statement has recommended a high b-value between 750 and 1000s/mm² for qualitative tumour evaluation in whole-body imaging [36] and the use of three b-values to enable the calculation of perfusion-insensitive ADC values, this should include a b-value of 0 s/mm², a b-value of ≥ 100 s/mm² and a higher b-value of ≥ 500 s/mm². Another consensus statement as recommended by the Prostate Cancer Clinical Trials Working Group (PCWG) for DWI in metastatic prostate cancer has suggested that 2 b-values (b50-100 s/mm² and b800-1000 s/mm²) be used in a core protocol and 3 b-values for a more comprehensive assessment (additional b500-600 s/mm²). The core protocol is aimed at detecting the onset of metastatic disease and the more comprehensive assessment for those patients with known metastatic disease and those in whom serial tumour response assessments (including clinical trials) are planned [54]. To date there is little evidence to support ADC in the diagnostic setting though the calculation of mean ADC values has been shown to correlate significantly with treatment response and may be implemented as a tool in patient monitoring [55].

In conclusion, our systematic review aimed to determine the diagnostic accuracy of WBMRI in the initial assessment of myeloma patients and its impact on management in comparison with ¹⁸F-FDG PET/CT or WBCT. Studies were heterogeneous, with biased accrual, and lack of an independent reference standard precluding meta-analysis. In the future, multicentre studies of WBMRI should be designed to address these gaps, in particular paying attention to minimising accrual bias, assessing the generalisability of these advanced techniques in the multicentre setting, the impact of

different MRI sequences, the impact of standardization of MRI protocols, as well as the impact on management and cost-effectiveness of the different cross-sectional approaches.

Conflict of interest statement:

We declare no conflict of interest.

ACKNOWLEDGEMENTS:

The authors acknowledge the support from the Department of Health via the National Institute for Health Research Comprehensive Biomedical Research Centre award to Guy's & St Thomas' NHS Foundation Trust in partnership with King's College London and King's College Hospital NHS Foundation Trust; and from the King's College London/University College London Comprehensive Cancer Imaging Centre funded by Cancer Research UK and Engineering and Physical Sciences Research Council in association with the Medical Research Council and Department of Health.

REFERENCES

- 1 UK CR (2017) Myeloma Survival statistics. Available via <http://www.cancerresearchuk.org/health-professional/cancer-statistics/statistics-by-cancer-type/myeloma/survival#heading-Zero>. Accessed 11 April 2017
- 2 Landgren O, Kyle RA, Pfeiffer RM et al (2009) Monoclonal gammopathy of undetermined significance (MGUS) consistently precedes multiple myeloma: a prospective study. *Blood* 113:5412-5417
- 3 Weiss BM, Abadie J, Verma P, Howard RS, Kuehl WM (2009) A monoclonal gammopathy precedes multiple myeloma in most patients. *Blood* 113:5418-5422
- 4 Kyle RA, Durie BG, Rajkumar SV et al (2010) Monoclonal gammopathy of undetermined significance (MGUS) and smoldering (asymptomatic) multiple myeloma: IMWG consensus perspectives risk factors for progression and guidelines for monitoring and management. *Leukemia* 24:1121-1127
- 5 Manier S, Sacco A, Leleu X, Ghobrial IM, Roccaro AM (2012) Bone marrow microenvironment in multiple myeloma progression. *J Biomed Biotechnol* 2012:157496
- 6 Dimopoulos MA, Hillengass J, Usmani S et al (2015) Role of magnetic resonance imaging in the management of patients with multiple myeloma: a consensus statement. *J Clin Oncol* 33:657-664
- 7 Dinter DJ, Neff WK, Klaus J et al (2009) Comparison of whole-body MR imaging and conventional X-ray examination in patients with multiple myeloma and implications for therapy. *Ann Hematol* 88:457-464
- 8 Breyer RJ, 3rd, Mulligan ME, Smith SE, Line BR, Badros AZ (2006) Comparison of imaging with FDG PET/CT with other imaging modalities in myeloma. *Skeletal Radiol* 35:632-640
- 9 Bannas P, Hentschel HB, Bley TA et al (2012) Diagnostic performance of whole-body MRI for the detection of persistent or relapsing disease in multiple myeloma after stem cell transplantation. *Eur Radiol* 22:2007-2012
- 10 Bartel TB, Haessler J, Brown TL et al (2009) F18-fluorodeoxyglucose positron emission tomography in the context of other imaging techniques and prognostic factors in multiple myeloma. *Blood* 114:2068-2076
- 11 Bauerle T, Hillengass J, Fechtner K et al (2009) Multiple myeloma and monoclonal gammopathy of undetermined significance: importance of whole-body versus spinal MR imaging. *Radiology* 252:477-485
- 12 Caldarella C, Treglia G, Isgro MA, Treglia I, Giordano A (2012) The role of fluorine-18-fluorodeoxyglucose positron emission tomography in evaluating the response to treatment in patients with multiple myeloma. *Int J Mol Imaging* 2012:175803
- 13 Gleeson TG, Moriarty J, Shortt CP et al (2009) Accuracy of whole-body low-dose multidetector CT (WBLDCT) versus skeletal survey in the detection of myelomatous lesions, and correlation of disease distribution with whole-body MRI (WBMRI). *Skeletal Radiol* 38:225-236
- 14 Ghanem N, Lohrmann C, Engelhardt M et al (2006) Whole-body MRI in the detection of bone marrow infiltration in patients with plasma cell neoplasms in comparison to the radiological skeletal survey. *Eur Radiol* 16:1005-1014
- 15 Hanrahan CJ, Christensen CR, Crim JR (2010) Current concepts in the evaluation of multiple myeloma with MR imaging and FDG PET/CT. *Radiographics* 30:127-142
- 16 Ippolito D, Besostri V, Bonaffini PA, Rossini F, Di Lelio A, Sironi S (2013) Diagnostic value of whole-body low-dose computed tomography (WBLDCT) in bone lesions detection in patients with multiple myeloma (MM). *Eur J Radiol* 82:2322-2327
- 17 Kropil P, Fenk R, Fritz LB et al (2008) Comparison of whole-body 64-slice multidetector computed tomography and conventional radiography in staging of multiple myeloma. *Eur Radiol* 18:51-58

- 18 Zamagni E, Cavo M (2012) The role of imaging techniques in the management of multiple myeloma. *Br J Haematol* 159:499-513
- 19 Zamagni E, Nanni C, Patriarca F et al (2007) A prospective comparison of 18F-fluorodeoxyglucose positron emission tomography-computed tomography, magnetic resonance imaging and whole-body planar radiographs in the assessment of bone disease in newly diagnosed multiple myeloma. *Haematologica* 92:50-55
- 20 Terpos E, Kleber M, Engelhardt M et al (2015) European Myeloma Network guidelines for the management of multiple myeloma-related complications. *Haematologica* 100:1254-1266
- 21 Hillengass J, Moulopoulos LA, Delorme S et al (2017) Whole-body computed tomography versus conventional skeletal survey in patients with multiple myeloma: a study of the International Myeloma Working Group. *Blood Cancer J* 7:e599
- 22 Dimopoulos M, Kyle R, Fermand JP et al (2011) Consensus recommendations for standard investigative workup: report of the International Myeloma Workshop Consensus Panel 3. *Blood* 117:4701-4705
- 23 Usmani SZ, Heuck C, Mitchell A et al (2012) Extramedullary disease portends poor prognosis in multiple myeloma and is over-represented in high-risk disease even in the era of novel agents. *Haematologica* 97:1761-1767
- 24 Rajkumar SV, Dimopoulos MA, Palumbo A et al (2014) International Myeloma Working Group updated criteria for the diagnosis of multiple myeloma. *Lancet Oncol* 15:e538-548
- 25 Whiting PF, Rutjes AW, Westwood ME et al (2011) QUADAS-2: a revised tool for the quality assessment of diagnostic accuracy studies. *Ann Intern Med* 155:529-536
- 26 Baur-Melnyk A, Buhmann S, Becker C et al (2008) Whole-body MRI versus whole-body MDCT for staging of multiple myeloma. *AJR Am J Roentgenol* 190:1097-1104
- 27 Cascini GL, Falcone C, Console D et al (2013) Whole-body MRI and PET/CT in multiple myeloma patients during staging and after treatment: personal experience in a longitudinal study. *Radiol Med* 118:930-948
- 28 Giles SL, Messiou C, Collins DJ et al (2014) Whole-body diffusion-weighted MR imaging for assessment of treatment response in myeloma. *Radiology* 271:785-794
- 29 Pawlyn C, Fowkes L, Otero S et al (2016) Whole-body diffusion-weighted MRI: a new gold standard for assessing disease burden in patients with multiple myeloma? *Leukemia* 30:1446-1448
- 30 Sachpekidis C, Mosebach J, Freitag MT et al (2015) Application of (18)F-FDG PET and diffusion weighted imaging (DWI) in multiple myeloma: comparison of functional imaging modalities. *Am J Nucl Med Mol Imaging* 5:479-492
- 31 Shortt CP, Gleeson TG, Breen KA et al (2009) Whole-Body MRI versus PET in assessment of multiple myeloma disease activity. *AJR Am J Roentgenol* 192:980-986
- 32 Brillet EDOB, A.M.; Devillers, A.; Lamy De La Chapelle, T.; Bertaud-Gounot, V.; Saint-Jalmes, H.; Guillin, R.; Garin, E.; Duvauferrier, R. (2012) Comparison between whole-body diffusion MRI and FDG PET/CT in the diagnosis of symptomatic myeloma. *Med Nucl* 36:313-319
- 33 Regelink JC, Minnema MC, Terpos E et al (2013) Comparison of modern and conventional imaging techniques in establishing multiple myeloma-related bone disease: a systematic review. *Br J Haematol* 162:50-61
- 34 Attariwala R, Picker W (2013) Whole body MRI: improved lesion detection and characterization with diffusion weighted techniques. *J Magn Reson Imaging* 38:253-268
- 35 Collins CD (2010) Multiple myeloma. *Cancer Imaging* 10:20-31
- 36 Padhani AR, Liu G, Koh DM et al (2009) Diffusion-weighted magnetic resonance imaging as a cancer biomarker: consensus and recommendations. *Neoplasia* 11:102-125
- 37 De Filippo M, Pogliacomi F, Albisinni U et al (2008) Occult large epiphyseal solitary plasmacytoma at multidetector row computer tomography detected by magnetic resonance imaging. *Acta Bio-Medica de l Ateneo Parmense* 79:240-245

- 38 Charles-Edwards EM, deSouza NM (2006) Diffusion-weighted magnetic resonance imaging and its application to cancer. *Cancer Imaging* 6:135-143
- 39 Lichy MP, Aschoff P, Plathow C et al (2007) Tumor detection by diffusion-weighted MRI and ADC-mapping--initial clinical experiences in comparison to PET-CT. *Invest Radiol* 42:605-613
- 40 Lin C, Luciani A, Belhadj K et al (2010) Multiple myeloma treatment response assessment with whole-body dynamic contrast-enhanced MR imaging. *Radiology* 254:521-531
- 41 Dutoit JC, Claus E, Offner F, Noens L, Delanghe J, Verstraete KL (2016) Combined evaluation of conventional MRI, dynamic contrast-enhanced MRI and diffusion weighted imaging for response evaluation of patients with multiple myeloma. *Eur J Radiol* 85:373-382
- 42 Dutoit JC, Vanderkerken MA, Verstraete KL (2013) Value of whole body MRI and dynamic contrast enhanced MRI in the diagnosis, follow-up and evaluation of disease activity and extent in multiple myeloma. *Eur J Radiol* 82:1444-1452
- 43 Horger M, Weisel K, Horger W, Mroue A, Fenchel M, Lichy M (2011) Whole-body diffusion-weighted MRI with apparent diffusion coefficient mapping for early response monitoring in multiple myeloma: preliminary results. *AJR Am J Roentgenol* 196:W790-795
- 44 Durie BG, Harousseau JL, Miguel JS et al (2006) International uniform response criteria for multiple myeloma. *Leukemia* 20:1467-1473
- 45 Kyle RA, Rajkumar SV (2009) Criteria for diagnosis, staging, risk stratification and response assessment of multiple myeloma. *Leukemia* 23:3-9
- 46 Hillengass J, Fechtner K, Weber MA et al (2010) Prognostic significance of focal lesions in whole-body magnetic resonance imaging in patients with asymptomatic multiple myeloma. *J Clin Oncol* 28:1606-1610
- 47 Palumbo A, Avet-Loiseau H, Oliva S et al (2015) Revised International Staging System for Multiple Myeloma: A Report From International Myeloma Working Group. *J Clin Oncol* 33:2863-2869
- 48 Baur A, Bartl R, Pellengahr C, Baltin V, Reiser M (2004) Neovascularization of bone marrow in patients with diffuse multiple myeloma: a correlative study of magnetic resonance imaging and histopathologic findings. *Cancer* 101:2599-2604
- 49 Stabler A, Baur A, Bartl R, Munker R, Lamerz R, Reiser MF (1996) Contrast enhancement and quantitative signal analysis in MR imaging of multiple myeloma: assessment of focal and diffuse growth patterns in marrow correlated with biopsies and survival rates. *AJR Am J Roentgenol* 167:1029-1036
- 50 Squillaci E, Bolacchi F, Altobelli S et al (2015) Pre-treatment staging of multiple myeloma patients: comparison of whole-body diffusion weighted imaging with whole-body T1-weighted contrast-enhanced imaging. *Acta Radiol* 56:733-738
- 51 Nosas-Garcia S, Moehler T, Wasser K et al (2005) Dynamic contrast-enhanced MRI for assessing the disease activity of multiple myeloma: a comparative study with histology and clinical markers. *J Magn Reson Imaging* 22:154-162
- 52 Rahmouni A, Montazel JL, Divine M et al (2003) Bone marrow with diffuse tumor infiltration in patients with lymphoproliferative diseases: dynamic gadolinium-enhanced MR imaging. *Radiology* 229:710-717
- 53 Subhawong TK, Jacobs MA, Fayad LM (2014) Diffusion-weighted MR imaging for characterizing musculoskeletal lesions. *Radiographics* 34:1163-1177
- 54 Padhani AR, Lecouvet FE, Tunariu N et al (2017) METastasis Reporting and Data System for Prostate Cancer: Practical Guidelines for Acquisition, Interpretation, and Reporting of Whole-body Magnetic Resonance Imaging-based Evaluations of Multiorgan Involvement in Advanced Prostate Cancer. *Eur Urol* 71:81-92
- 55 Latifoltojar A, Hall-Craggs M, Rabin N et al (2017) Whole body magnetic resonance imaging in newly diagnosed multiple myeloma: early changes in lesional signal fat fraction predict disease response. *Br J Haematol* 176:222-233