



King's Research Portal

DOI:

[10.1016/j.wneu.2017.03.113](https://doi.org/10.1016/j.wneu.2017.03.113)

Document Version

Peer reviewed version

[Link to publication record in King's Research Portal](#)

Citation for published version (APA):

Sokratous, G., Ughratdar, I., Selway, R., Al-Sarraj, S., & Ashkan, K. (2017). Cavernoma: New insights from an unusual case. *World Neurosurgery*. <https://doi.org/10.1016/j.wneu.2017.03.113>

Citing this paper

Please note that where the full-text provided on King's Research Portal is the Author Accepted Manuscript or Post-Print version this may differ from the final Published version. If citing, it is advised that you check and use the publisher's definitive version for pagination, volume/issue, and date of publication details. And where the final published version is provided on the Research Portal, if citing you are again advised to check the publisher's website for any subsequent corrections.

General rights

Copyright and moral rights for the publications made accessible in the Research Portal are retained by the authors and/or other copyright owners and it is a condition of accessing publications that users recognize and abide by the legal requirements associated with these rights.

- Users may download and print one copy of any publication from the Research Portal for the purpose of private study or research.
- You may not further distribute the material or use it for any profit-making activity or commercial gain
- You may freely distribute the URL identifying the publication in the Research Portal


Take down policy

If you believe that this document breaches copyright please contact librarypure@kcl.ac.uk providing details, and we will remove access to the work immediately and investigate your claim.

Accepted Manuscript

Cavernoma: New insights from an unusual case

G. Sokratous, MSc, MRCSEd, I. Ughratdar, FRCS (S/N), R. Selway, FRCS (S/N),
Safa Al-Sarraj, MB ChB, K. Ashkan, FRCS (S/N)



PII: S1878-8750(17)30436-9

DOI: [10.1016/j.wneu.2017.03.113](https://doi.org/10.1016/j.wneu.2017.03.113)

Reference: WNEU 5482

To appear in: *World Neurosurgery*

Received Date: 21 November 2016

Revised Date: 21 March 2017

Accepted Date: 23 March 2017

Please cite this article as: Sokratous G, Ughratdar I, Selway R, Al-Sarraj S, Ashkan K, Cavernoma: New insights from an unusual case, *World Neurosurgery* (2017), doi: 10.1016/j.wneu.2017.03.113.

This is a PDF file of an unedited manuscript that has been accepted for publication. As a service to our customers we are providing this early version of the manuscript. The manuscript will undergo copyediting, typesetting, and review of the resulting proof before it is published in its final form. Please note that during the production process errors may be discovered which could affect the content, and all legal disclaimers that apply to the journal pertain.

Cavernoma: New insights from an unusual case

G Sokratous¹, I Ughratdar², R Selway¹, Safa Al-Sarraj³, K Ashkan¹

¹Department of Neurosurgery. King's College Hospital Denmark Hill London, SE5 9RS United Kingdom

²Department of Neurosurgery. Birmingham University Hospitals NHS Foundation Trust, B15 2TH

³Department of Neuropathology, King's College Hospital Denmark Hill London, SE5 9RS

Authors

Mr Giannis Sokratous, MSc, MRCSEd
Mr Ismail Ughratdar, FRCS (S/N)
Mr Richard Selway, FRCS (S/N)
Prof Safa Al-Sarraj, MB ChB
Prof Keyoumars Ashkan, FRCS (S/N)

Corresponding Author

Mr Giannis Sokratous
King's College Hospital NHS Foundation Trust
Department of Neurosurgery
Denmark Hill
SE5 9RS
Email: giannis.sokratous@nhs.net
Phone: 02032991906
Fax: 02032993587

Cavernoma: New insights from an unusual case

Abstract

Rapid growth in cerebral cavernous malformation is rare. We present the case of a 71 year old patient with known multiple cavernomas over many years in whom one lesion showed rapid expansion in size. Histological examination revealed co-existence of glioblastoma within the cavernoma. We review the literature for similar cases and discuss the potential mechanisms underlying this phenomenon. Review of the literature revealed four cases with known cerebral cavernous malformations that have later developed, at the same site, a high grade glioma. All reported cases involve female patients with age ranging from 25 to 71, with imaging confirming rapid growth in the lesion. We conclude that although rare, rapid expansion of existing cavernoma should be treated as suspicious for development of other malignant tumors, and propose adding the possibility of chronic inflammation in the surrounding brain caused by micro-bleeds and hemosiderin deposition from the cavernoma to the list of possible causes.

Key Words

cavernoma, high grade glioma, glioblastoma, transformation

Introduction

Cerebral cavernous malformations (CCMs) are vascular malformations characterized by enlarged capillary cavities without intervening brain parenchyma. They are rare, with a prevalence of around 0.5% in the general population, accounting for 5-15% of all vascular malformations of the central nervous system and can be either sporadic or familial(2, 20). Familial cavernomatosis represents 10-15% of the total number of cavernoma cases and it is inherited in an autosomal dominant fashion with various degrees of penetration(8). Familial cavernomas are multiple with their risk of hemorrhage being twice as high compared to sporadic ones(17). Cavernomas are usually occult and present with an episode of symptomatic hemorrhage between the second and fifth decades of life. Other common presenting symptoms include headaches, seizures and focal neurological deficits(20).

The co-existence of cerebral cavernous malformations and primary brain gliomas is rare. It is still unknown why this phenomenon occurs with various unverified theories proposed(3, 11, 13, 18, 27). Here we present the case of a 71 year old lady who developed glioblastoma multiforme at the site of a pre-existing cavernoma. To our knowledge, there have only been five reported cases of malignant gliomas arising at the site of pre-existing cavernoma(1, 18, 21, 22, 28). Here, we present our case and discuss potential biological pathways for tumor development in patients with CCMs.

Case Report

A 71 year-old woman with a history of multiple cavernomata presented to the emergency department with a 3 days history of left sided hemiparesis, facial weakness and confusion.

In the year preceeding this admission she sought the advice of her neurologist because of increased seizure frequency and intermittent, profound emotional lability. She had been diagnosed with multiple cavernomata in December 2012, after developing seizures, which were controlled with levetiracetam and lamotrigine.

Patient did not receive radiotherapy or radiosurgery for her cavernomata which were managed conservatively with imaging surveillance under the care of the neurovascular MDT (*figures 1,2*). She underwent formal genetic testing which identified a heterozygous single nucleotide substitution in the CCM2 gene.

On this admission, patient had left sided hemiparesis (MRC grade 4/5), facial weakness, difficulty following commands, as well as difficulty with number comprehension, calculation, and reading. MRI revealed a heterogeneously enhancing lesion with T1 shortening and peripheral contrast enhancement consistent with a high grade tumor (*figure 3*).

The patient underwent craniotomy and resection with histopathological examination revealing glioblastoma multiforme, WHO grade IV, IDH1 negative and cavernoma (*figure 4*). In the tumor sample the MGMT promoter gene was unmethylated. She was subsequently treated with radiation and chemotherapy as per Stupp protocol for the treatment of glioblastoma.

Discussion

Though rare (*Table 1*), the co-existence of high grade gliomas and cavernomas is recognized, but their presence in combination might be more frequent than reported. Various theories have been proposed attempting to describe the etiological relationship between the two, including (a) fortuitous association (b) sequential – secondary due to reactive or neoplastic glial change to a previously existing vascular malformation or vice versa under the influence of tumor angiogenic factor (c) genetic predisposition (d) common viral origin (e) radiation exposure(3, 11, 13, 18, 27).

The common viral origin theory has been proposed more than three decades ago but the supporting evidence is insufficient. Polyoma virus, which belongs to papovavirus family, is a pathogen only for mice and is known to have dose dependent tumorigenic effect. High doses can cause multiple capillary, cystic, or cavernous hemangiomas in brain and spinal cord with the formation of the latter greatly enhanced by suppression of the immune system(11, 25). Polyoma virus is not known to induce glial tumors but it has been shown that another papovavirus, SV 40 virus, causes ependymomas in new-born hamsters(9, 16). Although of interest, applicability of this knowledge to humans remain questionable.

We have recently gained significant knowledge surrounding the molecular genetics of cavernomas through the study of hereditary cavernoma syndromes that confirm link of the latter to three genes: CCM1, CCM2, CCM3(6). A loss-of-function mutation to any of these genes produces an autosomal dominant syndrome that is characterized by one or more cavernomas. Cavernomas can also develop following somatic mutations of these genes(26). Interestingly, monosomy of chromosome 7 that hosts both CCM1 and CCM2, is common following hyper-activation of Ras

oncogenes or mutation of the neurofibromatosis-1 protein indicating that genetic factors within glial and Schwann cell tumors may lead to subsequent development of cavernomas(18).

Additionally, growth factors and cytokines expressed by vascular anomalies in the brain have been shown to promote tumorigenesis. Dai et al, investigated the role of platelet-derived growth factor and platelet-derived platelet factor receptor (PDGF and PDGFR) in cell cultures and in vivo in mice. They presented evidence that some low-grade gliomas may be comprised of proliferating glial progenitor cells with blocked ability to differentiate whereas malignant gliomas have acquired mutations that disrupt the cell cycle arrest pathways such as by loss of *Ink4a-Arf*. Co-expression of PDGF and PDGFR has been demonstrated in human gliomas indicating that autocrine stimulation may be involved in the formation of malignant gliomas. By introducing PDGF to neural progenitors and astrocytes they showed gliomagenesis with *Ink4a-Arf* loss promoting malignant phenotype(7). Various other factors that are secreted by gliomas or the cells surrounding them as well as vascular malformations, including vascular endothelial growth factor (VEGF) and angioprotein-1 have been shown to promote the development of cavernous malformations but also the progression of various intracranial tumors(10, 14, 23, 24).

Another possible explanation for malignant changes in glial cells adjacent to cavernomas may be chronic inflammation caused by micro-bleeds and hemosiderin deposition from the cavernoma. Chronic inflammation is known to promote malignancy in a range of tissues such as colorectal carcinoma in Chron's disease, bladder cancer with the use of indwelling catheters and gastric adenocarcinoma with H. Pylori infection(5). It is therefore possible that similar processes over time may also lead to malignant transformation of glial cells in proximity of the cavernomas.

The fact that all cases described had a long history of prior cavernoma is consistent with such a hypothesis of chronic irritation deriving the process of tumor formation. Additionally, in three out of these five cases evidence of previous hemorrhages is reported in the form of hemosiderin deposits that were identified either intraoperatively(28) or following histopathological examination of the specimens(1, 22).

Not surprisingly, in all cases there was significant change in the size of the malformation at the time of the diagnosis of high grade gliomas, as well as new or worsening of pre-existing seizure activity with the exception of the posterior fossa case, but little is still known about the change in size of cavernomas over time. First to describe dynamic changes of these malformations was Pozzati in 1989, presenting three cases in which the cavernomas grew substantially over time(19). Similarly, rapid growth with aggressive behavior despite multiple surgical excisions in a tumor with histologic confirmation of cavernoma has been described by Stacey in 2000(12). In contradiction, Kim in 1997 showed decrease in the size over time and more specifically from an average diameter of 14.2mm to 9.1mm with repeat imaging(15). The biggest study demonstrating dynamic changes in the size of cavernomas by Clatterbuck published in 2000, did not favor either growth or shrinking over time. In this study, 68 patients with 114 cavernomas underwent serial imaging over a period of 3.7 years. 22% of the lesions were stable in size over time, 43% increased in size and 35% decreased. Interestingly, many of the above reported cavernomas had both periods of increase and decrease in size(4).

CONCLUSION

It is unusual for cavernomas to grow rapidly. We report a case with rapid expansion of a known cavernoma with histology confirming glioblastoma embedded within the malformation, radically altering the management strategy. The biological mechanism is still speculative but may be related to common genetic pathways for both lesions or tumorigenic cytokines and growth factors released by vascular malformations. We propose adding the possibility of chronic inflammation in the surrounding brain caused by micro-bleeds and hemosiderin deposition from the cavernoma to this list. From a practical point, in rapidly growing cavernomas, a low threshold to obtain histological confirmation, either in the form of biopsy or resection, should be employed to rule out malignancy.

Disclosure

There is no financial or other conflict of interests to be declared by the authors.

Patient Consent

Patient has consented to the submission of this case report to the journal.

References

1. Acciarri N, Padovani R, Giulioni M, Roncaroli F: Cerebral astrocytoma and cavernous angioma: A case report. *Br J Neurosurg* 8(5):607-610, 1994.
2. Cavalcanti DD, Kalani MYS, Martirosyan NL, Eales J, Spetzler RF, Preul MC: Cerebral cavernous malformations: From genes to proteins to disease: Clinical article. *J Neurosurg* 116(1):122-132, 2012.
3. Chee CP, Johnston R, Doyle D, Macpherson P: Oligodendroglioma and cerebral cavernous angioma: Case report. *J Neurosurg* 62(1):145-147, 1985.
4. Clatterbuck RE, Moriarity JL, Elmaci I, Lee RR, Breiter SN, Rigamonti D: Dynamic nature of cavernous malformations: A prospective magnetic resonance imaging study with volumetric analysis. *J Neurosurg* 93(6):981-986, 2000.
5. Coussens LM, Werb Z: Inflammation and cancer. *Nature* 420(6917):860-867, 2002.
6. Craig HD, Gunel M, Cepeda O, Johnson EW, Ptacek L, Steinberg GK, Ogilvy CS, Berg MJ, Crawford SC, Scott RM, Steichen-Gersdorf E, Sabroe R, Kennedy CT, Mettler G, Beis MJ, Fryer A, Awad IA, Lifton RP: Multilocus linkage identifies two new loci for a mendelian form of stroke, cerebral cavernous malformation, at 7p15-13 and 3q25.2-27. *Hum Mol Genet* 7(12):1851-1858, 1998.
7. Dai C, Celestino JC, Okada Y, Louis DN, Fuller GN, Holland EC: PDGF autocrine stimulation dedifferentiates cultured astrocytes and induces oligodendrogliomas and oligoastrocytomas from neural progenitors and astrocytes in vivo. *Genes Dev* 15(15):1913-1925, 2001.
8. Davenport WJ, Siegel AM, Dichgans J, Drigo P, Mammi I, Pereda P, Wood NW, Rouleau GA: CCM1 gene mutations in families segregating cerebral cavernous malformations. *Neurology* 56(4):540-543, 2001.
9. Eddy BE: Tumors produced in hamsters by SV40. *21(930-935):152*, 1962.

10. Ehtesham M, Kabos P, Yong WH, Schievink WI, Black KL, John SY: Development of an intracranial ependymoma at the site of a pre-existing cavernous malformation. *Surg Neurol* 60(1):80-82, 2003.
11. Fischer EG, Sotrel A, Welch K: Cerebral hemangioma with glial neoplasia (angioglioma?) report of two cases. *J Neurosurg* 56(3):430-434, 1982.
12. J. Stacey, K. Ashkan, JM Rice Edwards, R: Rapid growth in a cavernoma. *Br J Neurosurg* 14(6):585-588, 2000.
13. Kamide T, Nakada M, Hayashi Y, Suzuki T, Hayashi Y, Uchiyama N, Kijima T, Hamada J: Radiation-induced cerebellar high-grade glioma accompanied by meningioma and cavernoma 29 years after the treatment of medulloblastoma: A case report. *J Neurooncol* 100(2):299-303, 2010.
14. Kiliç T, Pamir MN, Küllü S, Eren F, Ozek MM, Black PM: Expression of structural proteins and angiogenic factors in cerebrovascular anomalies. *Neurosurgery* 46(5):1179-1192, 2000.
15. Kim D, Park Y, Choi J, Chung S, Lee K: An analysis of the natural history of cavernous malformations. *Surg Neurol* 48(1):9-17, 1997.
16. Kirschstein RL, Gerber P: Ependymomas produced after intracerebral inoculation of SV40 into new-born hamsters. *Nature* 195(4838):299-300, 1962.
17. Labauge P, Brunereau L, Levy C, Laberge S, Houtteville J: The natural history of familial cerebral cavernomas: A retrospective MRI study of 40 patients. *Neuroradiology* 42(5):327-332, 2000.
18. Mian MK, Nahed BV, Walcott BP, Ogilvy CS, Curry WT: Glioblastoma multiforme and cerebral cavernous malformations: Intersection of pathophysiologic pathways. *Journal of Clinical Neuroscience* 19(6):884-886, 2012.

19. Pozzati E, Giuliani G, Nuzzo G, Poppi M: The growth of cerebral cavernous angiomas. *Neurosurgery* 25(1):92-97, 1989.
20. Robinson JR, Awad IA, Little JR: Natural history of the cavernous angioma. *J Neurosurg* 75(5):709-714, 1991.
21. Rossi DC, Fiaschi P, Melloni I, Zona G: Cavernous angioma within the context of anaplastic oligodendroglioma: Case report and review of the literature. *Neurological Sciences* 35(12):2009-2011, 2014.
22. Schreuder T, Te Linteloo M, Kubat B, Koehler P: Anaplastic oligo-astrocytoma occurring after resection of a cerebral cavernous malformation; malignant transformation? case report and review on etiology. *J Neurol* 257(3):349-353, 2010.
23. Stockhammer G, Obwegeser A, Kostron H, Schumacher P, Muigg A, Felber S, Maier H, Slavc I, Günsilius E, Gastl G: Vascular endothelial growth factor (VEGF) is elevated in brain tumor cysts and correlates with tumor progression. *Acta Neuropathol* 100(1):101-105, 2000.
24. Takekawa Y, Sawada T: Vascular endothelial growth factor and neovascularization in astrocytic tumors. *Pathol Int* 48(2):109-114, 1998.
25. Vandeputte M: Antilymphocytic serum and polyoma oncogenesis in rats. *Transplant Proc* 1(1):100-105, 1969.
26. Verlaan DJ, Laurent SB, Sure U, Bertalanffy H, Andermann E, Andermann F, Rouleau GA, Siegel AM: CCM1 mutation screen of sporadic cases with cerebral cavernous malformations. *Neurology* 62(7):1213-1215, 2004.
27. WHITE RJ, KERNOHAN JW, WOOD MW: A study of fifty intracranial vascular tumors found incidentally at necropsy. *J Neuropathol Exp Neurol* 17(2):392-398, 1958.

28. Wilson D, Cohen B, Keshari K, Vogel H, Steinberg G, Dillon W: Case report: Glioblastoma multiforme complicating familial cavernous malformations. *Clinical neuroradiology* 24(3):293-296, 2014.

ACCEPTED MANUSCRIPT

Cavernoma: New insights from an unusual case

G Sokratous¹, I Ughratdar², R Selway¹, Safa Al-Sarraj³, K Ashkan¹

¹Department of Neurosurgery. King's College Hospital Denmark Hill London, SE5 9RS United Kingdom

²Department of Neurosurgery. Birmingham University Hospitals NHS Foundation Trust, B15 2TH

³Department of Neuropathology, King's College Hospital Denmark Hill London, SE5 9RS

	Gender	Age	Background	Presentation	Site	Diagnosis	Histopathology
Case 1 ²²	F	71	Fit and well	Seizures	RF	Cavernoma	Anaplastic astrocytoma
Case 2 ¹⁸	F	69	Fit and well Family history of mCCM	Dysphasia, seizures	LT	Multiple cavernomas	GBM
Case 3 ²⁸	F	60	Known mCCM	Left sided hemiparesis, 1xseizure	RF	Multiple cavernomas	GBM
Case 4 ¹	F	25	Fit and well	Partial seizures, hemiparesis	LP	Cavernoma	Anaplastic astrocytoma
Case 5 ²¹	F	54	unknown	Headache, nausea, vomiting	V	Cavernoma	Anaplastic oligodendroglioma

Table 1 Literature review identified five cases with malignant gliomas developing at the same site with known cavernoma. GBM: glioblastoma, CCM: cerebral cavernous malformation. RF: right frontal, LT: left temporal, LP: left parietal, V: vermis

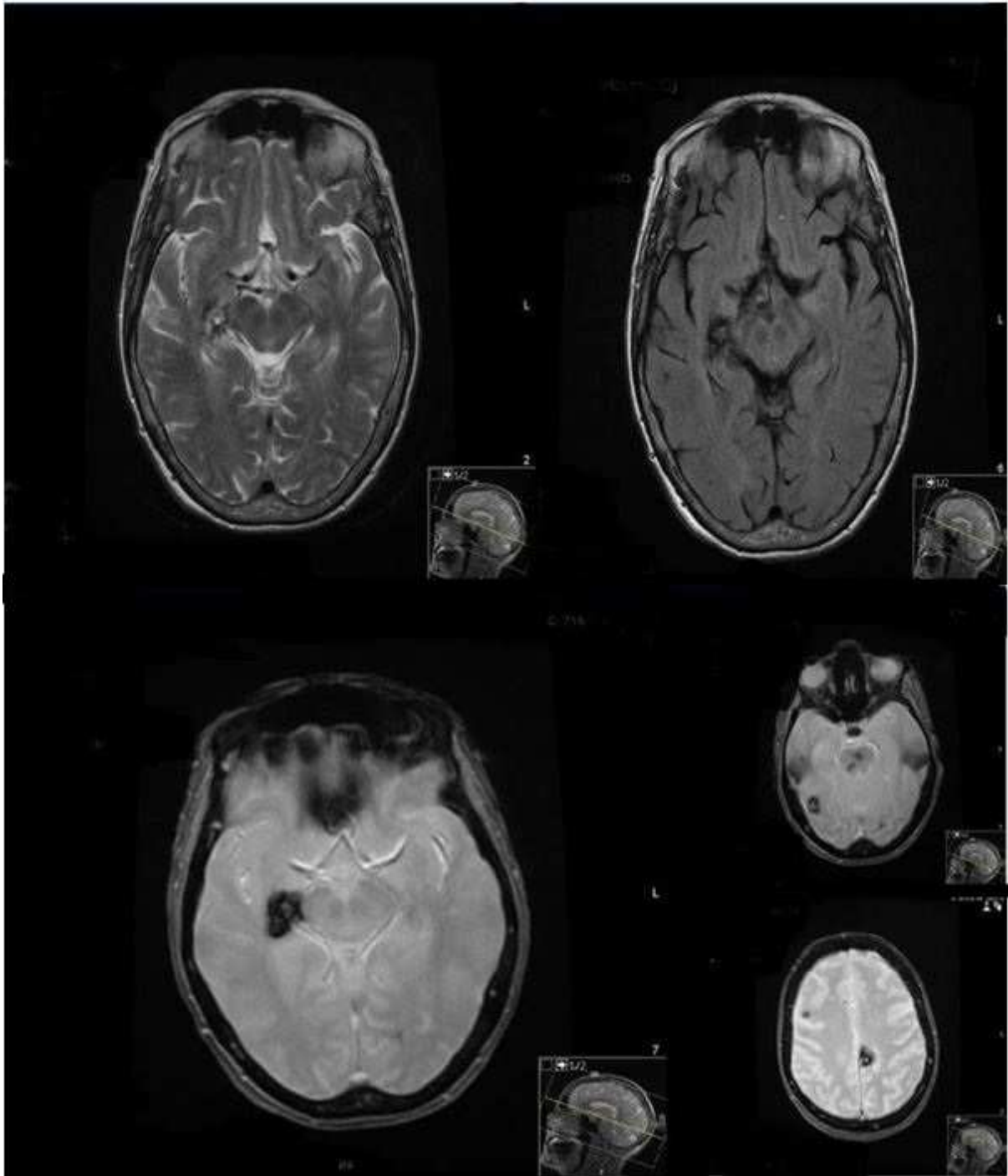


Figure 1. Initial MRI in January 2013 showing multiple intracranial lesions with T1 shortening consistent with multiple cavernomas with evidence of previous hemorrhage

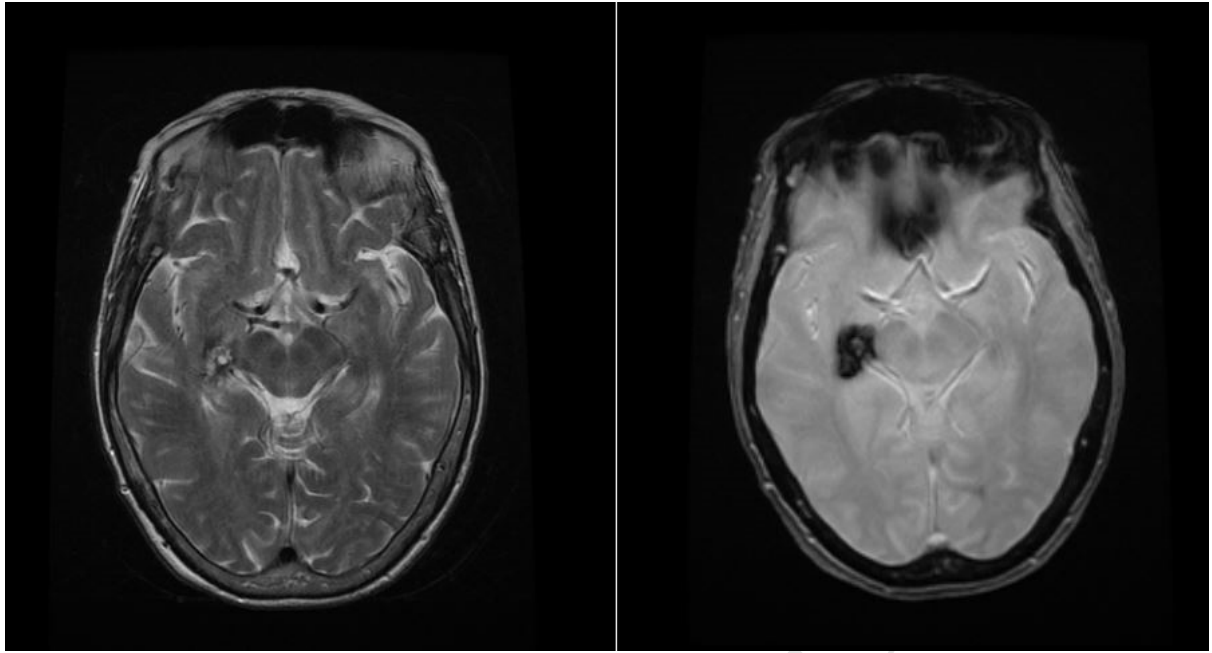


Figure 2. Interval MRI in June 2013 showing no significant changes in appearances compared to the initial MRI.

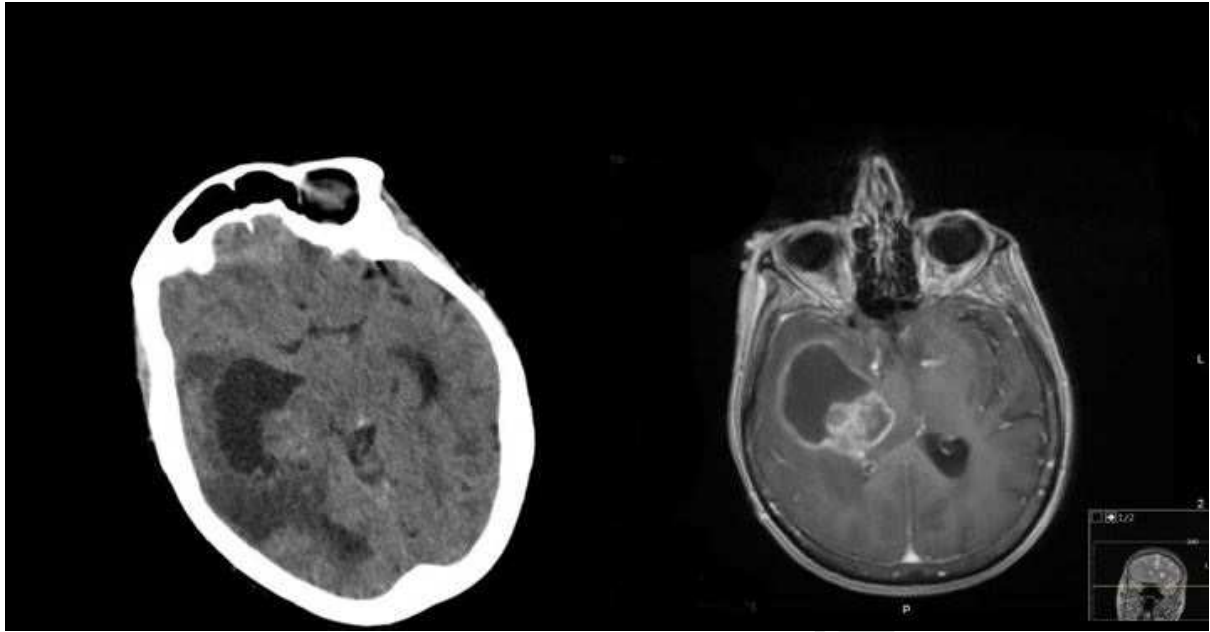


Figure 3. Imaging in April 2015 when patient presented with increasing seizure activity and hemiparesis showing significant increase in the size of the lesion with heterogeneous enhancement

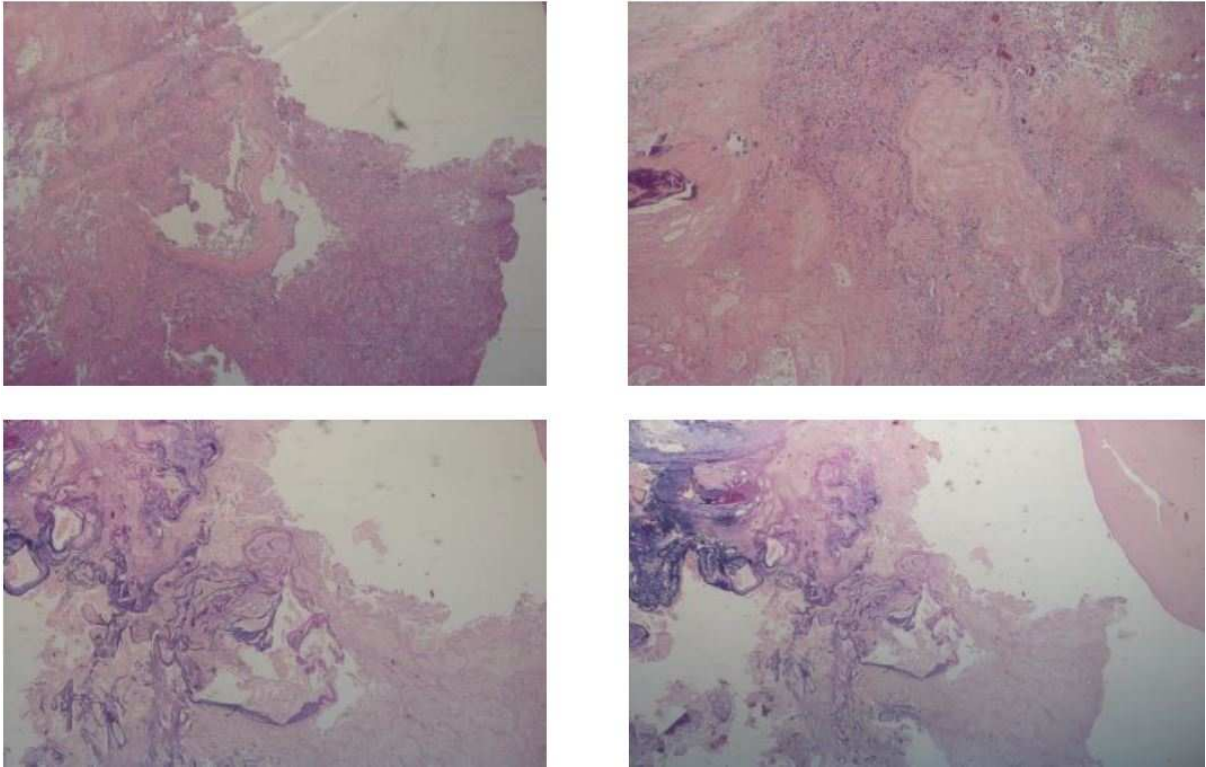


Figure 4 showing a largely necrotic pleomorphic tumor diffusely infiltrating the grey and white matter, small pieces of hippocampus and many abnormally formed blood vessels. The tumor is composed of large cells with pleomorphic oval-shaped nuclei and prominent nucleoli arranged in solid bundles within a fibrillary background. Large areas of pseudopalisading necrosis, endothelial cell proliferation with glomeruloid structure formation and brisk mitotic activity is noted. There are areas with collection of hyalinised and dilated blood vessels with different caliber and wall thickness; some with thrombosis and calcification. EVG confirms the vascular malformation consistent with cavernoma

Cavernoma: New insights from an unusual case

Highlights

- Five reported cases with co-existence / development of high grade gliomas in patients with long history of cavernomas
- Rapid growth in a cavernoma should raise suspicion of malignancy
- Theories proposed cannot explain co-existence of two lesions
- We propose adding chronic inflammation due to micro-bleeds as causative mechanism

Cavernoma as a benign vascular malformation: is it time to rethink?

G Sokratous¹, I Ughratdar², R Selway¹, Safa Al-Sarraj³, K Ashkan¹

¹Department of Neurosurgery. King's College Hospital Denmark Hill London, SE5 9RS United Kingdom

²Department of Neurosurgery. Birmingham University Hospitals NHS Foundation Trust, B15 2TH

³Department of Neuropathology, King's College Hospital Denmark Hill London, SE5 9RS

Abbreviations

CCM: cerebral cavernous malformation

MDT: multi-disciplinary team

WHO: World Health Organisation

MRC: Medical research council

MRI: magnetic resonance imaging

IDH: isocitrate dehydrogenase

MGMT: O⁶-methylguanine-DNA-methyltransferase

PDGF: platelet-derived growth factor

PDGFR: platelet-derived platelet factor receptor