



## King's Research Portal

DOI:

[10.1080/02656736.2016.1212278](https://doi.org/10.1080/02656736.2016.1212278)

*Document Version*

Peer reviewed version

[Link to publication record in King's Research Portal](#)

*Citation for published version (APA):*

Peek, M. C. L., Ahmed, M., Scudder, J., Baker, R., Pinder, S. E., & Douek, M. (2016). High intensity focused ultrasound in the treatment of breast fibroadenomata: Results of the HIFU-F feasibility trial. *International Journal of Hyperthermia*, 1-8. <https://doi.org/10.1080/02656736.2016.1212278>

### **Citing this paper**

Please note that where the full-text provided on King's Research Portal is the Author Accepted Manuscript or Post-Print version this may differ from the final Published version. If citing, it is advised that you check and use the publisher's definitive version for pagination, volume/issue, and date of publication details. And where the final published version is provided on the Research Portal, if citing you are again advised to check the publisher's website for any subsequent corrections.

### **General rights**

Copyright and moral rights for the publications made accessible in the Research Portal are retained by the authors and/or other copyright owners and it is a condition of accessing publications that users recognize and abide by the legal requirements associated with these rights.

- Users may download and print one copy of any publication from the Research Portal for the purpose of private study or research.
- You may not further distribute the material or use it for any profit-making activity or commercial gain
- You may freely distribute the URL identifying the publication in the Research Portal

### **Take down policy**

If you believe that this document breaches copyright please contact [librarypure@kcl.ac.uk](mailto:librarypure@kcl.ac.uk) providing details, and we will remove access to the work immediately and investigate your claim.



## High intensity focused ultrasound in the treatment of breast fibroadenomata: Results of the HIFU-F feasibility trial

MCL Peek, M Ahmed, J Scudder, R Baker, SE Pinder, M Douek & on behalf of the HIFU-F Trialists' Collaborative

To cite this article: MCL Peek, M Ahmed, J Scudder, R Baker, SE Pinder, M Douek & on behalf of the HIFU-F Trialists' Collaborative (2016): High intensity focused ultrasound in the treatment of breast fibroadenomata: Results of the HIFU-F feasibility trial, International Journal of Hyperthermia, DOI: [10.1080/02656736.2016.1212278](https://doi.org/10.1080/02656736.2016.1212278)

To link to this article: <http://dx.doi.org/10.1080/02656736.2016.1212278>



Accepted author version posted online: 02 Aug 2016.  
Published online: 02 Aug 2016.



Submit your article to this journal [↗](#)



Article views: 1



View related articles [↗](#)



View Crossmark data [↗](#)

**High intensity focused ultrasound in the treatment of breast fibroadenomata:  
Results of the HIFU-F feasibility trial**

MCL Peek\*,<sup>1,2</sup> M Ahmed,<sup>1</sup> J Scudder,<sup>2</sup> R Baker,<sup>3</sup> SE Pinder,<sup>1,2</sup> M Douek,<sup>1,2</sup> on behalf of the HIFU-F Trialists' Collaborative

<sup>1</sup> *Division of Cancer Studies, King's College London, Guy's Hospital Campus, Great Maze Pond, London SE1 9RT, Great Britain; mirjam.1.peek@kcl.ac.uk, +44 (0)20 7188 0721; muneer.ahmed@kcl.ac.uk, +44 (0)20 7188 0721; sarah.pinder@kcl.ac.uk, +44 (0)20 7188 6380; michael.douek@kcl.ac.uk, +44 (0)20 7188 6380;*

<sup>2</sup> *Guy's and St. Thomas' NHS Foundation Trust, Great Maze Pond, London, Great Britain; julie.scudder@gstt.nhs.uk, +44 (0)20 7188 5572;*

<sup>3</sup> *School of Business, 612, Maxwell Building, University of Salford, Salford, M5 4WT, Great Britain; rose.baker@cantab.net, +44 (0)16 1295 3861;*

Corresponding author for manuscript queries:

Ms. Mirjam Peek, mirjam.1.peek@kcl.ac.uk, +44 (0)20 7188 0721

Corresponding author for post-publishing queries and reprints:

Prof. Michael Douek, michael.douek@kcl.ac.uk, +44 (0)20 7188 6380

## **High intensity focused ultrasound in the treatment of breast fibroadenomata: Results of the HIFU-F feasibility trial**

**Objectives:** Breast fibroadenomata (FAD) are the most common breast lumps in women. High intensity focused ultrasound (HIFU) is a non-invasive ablative technique that can be used to treat FAD but is associated with prolonged treatment times. In the HIFU-F trial, we evaluated the change in volume over time with circumferential HIFU treatment of FAD and compare this to no treatment.

**Methods:** Patients  $\geq 18$  years, diagnosed with symptomatic, palpable FAD, visible on ultrasound (US) were recruited. Twenty patients were treated using the US-guided-HIFU under local anaesthesia. Another 20 participants underwent an US six months after diagnosis. Outcome measures included: reduction in treatment time compared to whole lesion ablation; feasibility to achieve a 50% reduction in volume after six months; decrease in volume compared to a control group and reduction in symptoms.

**Results:** Circumferential ablation reduced the mean treatment time by 37.5% (SD 20.1%) compared to whole lesion ablation. US demonstrated a significant mean reduction in FAD volume of 43.5% (SD 38.8%;  $p=0.016$ , paired t-test) in the HIFU group compared to 4.6% (SD 46.0%;  $p=0.530$ ) in the control group after six months. This mean reduction in FAD volume between the two groups was significant in favour of the HIFU group ( $p=0.002$ , grouped t-test). Pre-treatment pain completely resolved in six out of eight patients six months post-treatment.

**Conclusion:** Circumferential HIFU ablation of FAD is feasible, with a significant reduction in pain and volume compared to control participants. It provides a simple, non-invasive, outpatient – based alternative to surgical excision for FAD.

ISRCTN registration: 76622747

**Keywords:** High intensity focused ultrasound, breast, fibroadenomata, ablative technique, ultrasound.

## Introduction

Breast fibroadenomata (FAD) are the most common breast lumps in women and one in ten will develop a FAD during their lifetime. [1, 2] Patients with FAD present with a palpable lump, detected during self-examination or incidentally during screening mammography or other imaging of the chest area. [2, 3] Ultrasound (US) is the main diagnostic method used, but confirmation can only be obtained by core needle biopsy (CNB). [1-3] The management of FAD is generally limited to patient reassurance. Excision, either surgically or radiologically (e.g. by vacuum-assisted mammotomy (VAM)) is typically reserved for those women with symptomatic or rapidly growing lesions and results in scarring which may compromise cosmesis. [1-3] Furthermore, surgical excision is most commonly performed under general anaesthesia with its potential complications, in addition to any possible surgical complications. VAM is licensed for diagnostic purposes (not therapeutic) but is nevertheless increasingly used as an alternative to surgery. VAM is performed under local anaesthesia, is invasive, is not suitable for all FAD and may not always be successful in removing the whole FAD due to a decrease in visibility during treatment.

High intensity focused ultrasound (HIFU) is a novel non-invasive ablative technique which has been used for the treatment of liver, kidney, prostate, brain, bone and breast tumours. [4-6] During HIFU treatment, an US beam generated by a piezoelectric US transducer propagates through tissue as a high-frequency pressure wave. [5, 7] The beam is focused onto the target tissue and the energy from the beam elevates the temperature of the focus area to 60-95°C within seconds without causing damage to the directly adjacent tissues, leading to localised protein denaturation and coagulative necrosis. [5, 7, 8] Depending on the type of application and penetration depth, US beams with a frequency in the range between 0.5-4.0 MHz are used. [4, 5]

HIFU is capable of providing a completely non-invasive therapy, avoiding the potential complications associated with general anaesthesia and surgery. [9]

A systematic review by Peek *et al.* [10] on HIFU in the treatment of breast tumours showed that the most significant drawback with the current HIFU technique is the prolonged treatment time, which ranged from 78 and 171 minutes. The aim of the HIFU-F trial was to perform circumferential HIFU treatment to isolate the FAD from its blood supply, resulting in necrosis and a reduced treatment time. [11] Furthermore, this is the first case-control study comparing the change in FAD volume after six months with and without HIFU treatment.

## **Materials and Methods**

A prospective proof-of-principle trial was set up to initially recruit and treat 20 consecutive patients with circumferential HIFU. A further 20 unselected patients were invited to have a control US scan, six months after their initial US scan to determine the natural change in size of their FAD when treated conservatively. Written informed consent was obtained from all patients. This study received approval from the national Research Ethics Committee (13/LO/1221).

### ***Patient selection***

Patients were included if they were 18 years of age or older and had visited the one-stop Breast Clinic at Guy's Hospital with a symptomatic FAD – either a palpable lesion or pain developing from this lesion – which was visible on US. Patients more than 25 years of age required histological confirmation of the FAD diagnosis on needle core biopsy. Patients were excluded if they had an FAD of 1 cm or less, were pregnant or lactating, had received laser or radiation

therapy to the ipsilateral breast, had breast implants, if epithelial atypia was seen or if there was any suspicion of phyllodes tumour. No other exclusions were applied.

Any retro-areolar FAD will be treated in a lateral position. In the case of a FAD located close to the skin or pectoralis major muscle (< 5mm), local anaesthesia will be injected between the FAD and the skin and / or muscle. The optimal target volume will be selected in order to avoid thermal damage to skin and pectoral muscle and to cover the most central part of the FAD. All eligible patients were identified in three ways: (1) at the multi-disciplinary meeting, where all patients were discussed in which CNB or fine needle aspiration cytology was performed, (2) patients scheduled for surgical excision of a FAD and (3) patients referred to the breast clinic with a symptomatic breast lump requesting treatment. All patients were approached in the breast clinic or by telephone and received a patient information sheet (PIS) if interested in participating in the HIFU-F trial.

Primary outcome measures were the change in treatment time compared to whole lesion ablation (based on the treatment plan), feasibility of achieving a 50% reduction in volume on US after six months, and the decrease in volume on US compared to an observation only group (control). Secondary outcomes were the complication rate and patient recorded outcome measures (palpable FAD, pain symptoms before and after treatment measured with visual analog scale (VAS) prior and after treatment).

### ***HIFU treatment***

Patients were treated using the US-guided-Echopulse device (Theraclion Ltd, Malakoff, France) which is dedicated for the treatment of breast FAD and thyroid nodules. The device contained a cooling and coupling disposable unit to cool the skin and prevent burning. Breast lesions were

ablated under real-time US guidance using a 7.5-12 MHz diagnostic US transducer. Therapeutic US energy was produced by a 56 mm diameter 3.0 MHz treatment transducer with a central hole measuring 11 mm for the coaxial imaging transducer. The transducer ablates an oval tissue volume of approximately 9 mm in length and 2 mm in width.

All patients were treated as a day-case and under subcutaneous local anaesthesia (1.0% Lidocaine with adrenaline and 0.25 - 0.5% Bupivacaine, ratio 1:1, mean 23.1 ml, SD 8.1 ml). In the case of FAD located close to the muscle, anaesthesia was injected deep, between the muscle and the FAD, in order to avoid pain resulting from heating of the pectoralis major muscle. Depending on the position of the FAD and the size of the breast, the patient was placed in either a supine or lateral position and an immobilisation system was used to fix the breast. After an US scan with a handheld probe to locate the FAD, the device head was positioned on top of the FAD to outline the lesion and the skin in the radial and anti-radial view (Fig. 1). For every radial slice, treatment pulses were visualised and the skin and FAD outlines were adjusted when required. The procedure started with a single pulse in the centre of the FAD to determine the right energy level, identified by a hyper-echoic mark visible right after or during administration of the pulse. During subsequent treatment pulses no hyper-echoic mark was required and pulses were not repeated when no mark was seen. The HIFU device calculates the energy and power level of each pulse during treatment. In the HIFU-F study, only the circumference was ablated; two circumferential rings around the FAD were treated and the centre of the FAD was deselected (Fig. 2). The Echopulse device treats only one central, top or bottom disc shaped target volume (curved or horizontal) of the FAD during a treatment session. Most FAD require only one target volume as this is sufficient to cover the whole lesion. After the final pulse, the patient's skin was observed for any treatment changes. Patients were then discharged following hospital protocol.

Patients were asked to provide a pain score after the procedure for intra- and post-treatment pain on a VAS of 0-10.

Treatment time from the beginning of the first to the end of the last pulse administered was recorded, along with the number of pulses delivered. The average time to deliver a treatment pulse was calculated (including any delays between pulses due to treatment pauses) and used to estimate total treatment time required for delivering the pulses required to cover the whole lesion.

### ***Follow-up***

Patients were followed up at two weeks, three and six months with physical examination and US scan. The ultra-sonographers performing the US scans were not blinded but the consultant was blinded from the US results during physical examination. The decrease in FAD volume was determined using standard formulae in which V is the FAD volume and A, B and C are the longest diameters of the FAD measured on US. [12]

$$V = \frac{4}{3} * \pi * \left(\frac{1}{2}A\right) * \left(\frac{1}{2}B\right) * \left(\frac{1}{2}C\right)$$

### ***Control group***

A further 20 patients were consecutively recruited, without matching with the HIFU group, to determine the natural course in volume change of their FAD, as assessed by US, six months after initial presentation. Patients were recruited using the same inclusion and exclusion criteria as the HIFU treatment group. The change in volume of these patients was compared to the change in volume in the HIFU treatment group.

## *Statistical analysis*

Statistical analysis was performed using IBM SPSS statistics version 23. A paired t-test and Wilcoxon signed rank test were used to determine the significance of the reductions in FAD volumes over time. A Kolmogorov-Smirnov test was used to determine if there were any differences in distribution between the HIFU and the control group in terms of age and initial FAD volume. A grouped t-test, Levene's test and Mann Whitney U-test were used to determine if there was a significant difference in volume reductions between the HIFU and the control group.

## **Results**

### *Patients screened*

A total of 262 patients with FAD were screened prospectively at the MDM between January, 2014 and October, 2014. Of these 262 patients, 122 patients (45.3%) met all inclusion criteria, 82 patients were contacted and 20 patients (7.6%) agreed to participate in the HIFU-F trial.

### *Patient characteristics*

These 20 patients (HIFU group) with symptomatic palpable FAD (eight patients with pain related to FAD) successfully underwent circumferential HIFU treatment. Patients had a mean age of 30.3 years (SD 7.5 years, range 18-45 years) and mean volume of 7.3 cm<sup>3</sup> (SD 10.1 cm<sup>3</sup>, range 0.4-44.0 cm<sup>3</sup>). A further 20 patients (control group) with biopsy confirmed FAD successfully underwent a follow-up US six months after initial diagnosis. Patients had a mean age of 31.3 years (SD 6.5 years, range 21-46 years), not significantly different to the HIFU group

( $P=0.819$ , Kolmogorov-Smirnov test, *Fig. 3*). The mean volume was  $3.0 \text{ cm}^3$  (SD  $4.1 \text{ cm}^3$ , range  $0.4\text{-}18.7 \text{ cm}^3$ ), again not significantly different to the HIFU group before treatment ( $P=0.082$ , Kolmogorov-Smirnov test, *Fig. 3*).

### ***HIFU treatment***

Two circumferential rings were successfully treated in ten patients; one circumferential ring was successfully treated in nine patients (five of these almost completed treatment of two rings apart from one or two pulses) due to patient movement or pain during treatment. One patient was unable to tolerate a complete circumferential ring of pulses due to pain in her arm (repetitive strain injury). Two patients underwent surgery post-HIFU due to absence of decrease in FAD size three and 12 months after HIFU treatment, respectively. Histology demonstrated residual FAD but with prominent areas of fibrosis (*Fig. 4*). Mean energy per HIFU treatment was 134.6 Joule (SD 19.3 Joule) and mean power per treatment was 33.3 Watt (SD 4.8 Watt).

### ***Treatment times***

The mean recorded treatment time from first sonication to last sonication was 34.6 minutes (SD 10.5 minutes). Circumferential ablation reduced the treatment time by an average of 37.5% (SD 20.1%) compared to the treatment time calculated for whole lesion ablation. Total treatment recorded time of patients being in the theatre is 68.7 minutes (SD 16.2 minutes).

### ***Pain symptoms***

Eighteen of 20 patients experienced some discomfort or a burning sensation during the procedure. The mean maximum pain VAS score during treatment was 6.4 (SD 3.2). By moving to another part of the FAD, the treatment was continued with agreement of the patient in 17/18 patients. Mean maximum pain VAS score immediately after treatment was 1.6 (SD 1.9).

At six months follow-up, six out of eight patients who experienced pre-treatment pain had complete resolution of their symptoms. Two patients developed post-treatment pain, which resolved within three months.

### ***Complications***

Short-term complications (*Fig. 5*) at two weeks were: ecchymosis (n=9), erythema (n=6), hypopigmentation of the skin (n=1), dimpling of the skin (n=1), numbness of the skin (n=1) and a superficial first-degree skin burn (n=1). All short-term complications completely resolved within the first month post-treatment without the need for intervention. Hyper-pigmentation was found at three months in six patients and persisted at six months in four patients.

### ***Volume measurements by US***

US scans at two weeks post-treatment showed hyper-echogenicity and oedema at the circumference of the lesion in some patients. The FAD had a mean volume of 6.1 cm<sup>3</sup> (SD 8.4 cm<sup>3</sup>); a mean decrease in volume of 16.8% (SD 19.3%) ( $p=0.021$ , paired t-test;  $Z=-2.688$ ,  $p=0.007$ , Wilcoxon signed rank test). At three months the volume was 5.0 cm<sup>3</sup> (SD 6.5 cm<sup>3</sup>); a mean decrease in volume of 30.9% (SD 52.7%) ( $p=0.022$ ;  $Z=-2.535$ ,  $p=0.11$ ). At six months the mean volume was 4.6 cm<sup>3</sup> (SD 6.4 cm<sup>3</sup>), a decrease in volume of 43.5% (SD 38.8%) ( $p=0.016$ ;  $Z=-2.741$ ,  $p=0.006$ ) (*Fig. 6*, table 1a). At six months, a total of four patients had no palpable lesion.

### ***Control group***

At the six month US scan the mean volume was 2.6 cm<sup>3</sup> (SD 2.3 cm<sup>3</sup>), a non-significant change in size of 4.6% (SD 46.0 %) ( $p=0.530$ , paired t-test;  $Z=-0.073$ ,  $p=0.709$ , Wilcoxon signed rank test; table 1b). Compared to the control group the HIFU group showed a significant change in

volume over a period of six months ( $p=0.002$ , grouped t-test;  $U=58$ ,  $p=0.001$ , Mann Whitney U-test).

## Discussion

The current treatment of symptomatic or rapidly growing FAD is surgical excision, however scarring can compromise the cosmetic outcome [1-3] and VAM is licensed for diagnostic purposes (not therapeutic) but is nevertheless increasingly used as an alternative to surgery. An alternative non-invasive technique is therefore required, which allows the patient to undergo treatment without scarring, surgery and general anaesthesia and which allows for intra-operative visibility of the lesion and a low side-effect profile.

HIFU has demonstrated effectiveness in the treatment of benign breast disease using total lesion ablation. [13-15] Hynynen *et al.* [13], treated eleven FAD and found a decrease in volume of 32% (1.9 to 1.3 cm<sup>3</sup>) measured on T2-weighted magnetic resonance imaging after six months. Patients were treated with local anaesthesia and mild sedation. Slight pain was reported in four patients, mild pain in two and severe pain in one patient. No complications other than pain and swelling were reported. More recently, Kovatcheva *et al.* [14] found a FAD volume decrease of  $59.2\pm 18.2\%$  ( $n=42$ ) after six months on US and reported complete resolution of pain in 18 patients who had pre-treatment pain. These patients were treated under conscious sedation and the mean pain score during treatment was 29.7 (SD 27.5) using a 0-100 mm VAS scale. Three superficial skin burns with blister like aspects, and single cases of subcutaneous induration and hyperpigmentation were reported. Cavallo Marincola *et al.* [15] found a decrease of 50% at three months ( $n=10$ ). Local anaesthesia and conscious sedation were administered during treatment.

The number of patients with pre-treatment pain was not reported, but none of the patients had pain at six months. No complications were observed at three months apart from swelling and hardness of the treated area.

A systematic review by Peek *et al.* [10] showed that the most significant drawback with HIFU was the prolonged treatment time associated, which ranged between 78 and 171 minutes. The HIFU-F trial demonstrated that a high mean volume reduction of 43.5% (SD 38.8) can be achieved at six months with a circumferential ablation, whilst reducing mean treatment times to 37.4 minutes (SD 11.9). This reduction in treatment time made it possible to perform the procedure under local anaesthetic only, without the need for sedation – unlike previous studies. The treatment time for whole lesion ablation was calculated using the average time to deliver a single pulse, recorded during circumferential HIFU ablation. Although this included some variability caused by patient movement and repositioning, the calculated time might still be an under-estimation as patients with larger tumours and therefore a longer HIFU treatment time, may move more and require more time for repositioning.

It is likely that the circumferential ablation is successful through targeting the ‘feeding vasculature’ to the FAD. This could warrant the use of Doppler US imaging to target feeding vessels in real-time in future studies. In four patients an increase in FAD volume was seen on US post-treatment and in one patient the FAD did not change in size. A hypothesis about the increase in FAD size is that treatment could not be completed due to pain during treatment (n=2), furthermore HIFU only treats a disk and not the top and bottom of the FAD, due to distance restrictions to the skin (>5mm) and pectoralis major (>5mm). Two patients with increased FAD underwent surgical excision, one was happy to leave the FAD alone and the last patient was lost to follow-up.

After HIFU treatment, the FAD initially increases in size due to inflammation and oedema. This resolves within the first two weeks post-treatment. As seen in other trials [14], the largest decrease in size is observed between the third and sixth month, followed by a slower decrease between six and 12 months. It is important for patients to be aware of this gradual decrease in size, as opposed to the instant removal of the lump with surgical excision, as patients might be anxious about the persistence of a lump. Patient selection is therefore a very important factor. It is important for patients to be aware of the gradual decrease in size of the FAD after treatment and achieving impalpability of the lump might not always be achievable.

Six out of eight patients showed a resolution of pain symptoms post-treatment, this is most likely due to the treatment damaging the local sensory pain receptors thereby blocking the pain feedback pathway. Clearly FADs can cause pain and HIFU can be used if the pain is located in the FAD. Kovatcheva *et al.* [14] as well reported a resolution in FAD pain after HIFU treatment. For the control group the only measured outcome was change in volume and we did not assess pain scores. Volume was evaluated using an US to determine the FAD size after six months. Patients of both the control and the HIFU groups were recruited using the same inclusion and exclusion criteria without selection. However, since this study was not randomised, the control group might have been less symptomatic compared to the HIFU group, since they did not request treatment.

After six months the FAD became impalpable in four patients in the other 16 patients, the lump was still palpable but was more diffuse and therefore harder to feel. During follow-up, however, patients were not concerned about the residual lump. On US the FAD was seen to be fragmented in some cases and more integrated with the surrounding tissue. Patients were very

conscious of their treated FAD due to their participation in the trial, sometimes resulting in an over-estimation of the size of the lesion, compared to the size measured on US.

All complications recorded at two weeks completely disappeared within a month post-treatment without the need of any additional treatment. One patient developed a superficial first-degree skin burn during HIFU treatment; caused by either the micro-foam used for immobilisation of the breast or air in-between the probe and the skin. The patient required no treatment and the burn completely resolved within one month post-treatment. This patient attended the HIFU clinic one month later for HIFU treatment of a contralateral FAD. When placing the treatment probe on the skin, care is needed to make sure the probe is not placed on the site of local anaesthesia injection. Small air bubbles might be left at this site and when located in the US beam this might cause cavitation and in the worst case cause a blister or skin burn. Altered skin pigmentation was seen in six patients at three months and in three patients at six months. Skin pigmentation was more common in patients with a darker pigment colour, however skin pigmentation also occurred in a patient with pale skin.

Altered skin pigmentation can be caused by a high treatment power or a shorter distance between the FAD and the skin resulting in overheating of the skin, however the mean treatment power and distance between skin and FAD within the HIFU group were less than the average for the complete group (33.0 W/site vs 33.3 W/site and 3.7 mm vs 4.7 mm for respectively the patients altered with skin pigmentation and the HIFU-F trial group). Another possible explanation is that these patients did not feel much discomfort during treatment and therefore treatment could continue without interruptions, resulting in overheating of the skin. This theory could be correct for the first three patients but the latter three patients did feel more pain,

resulting in more treatment breaks. Further investigation is required to determine the cause of the altered pigmentation and it is important to inform future patients of this potential complication.

Compared to the control group, in the HIFU group there was a significant reduction in volume of the FAD over a period of six months. The significant difference in volume demonstrated that HIFU as a non-invasive technique can be used for the treatment of FAD.

There are however a few drawbacks of the technique, even with assistance of an immobilisation system, it was difficult to position and immobilise patients with smaller breasts. A more advanced immobilisation system is required to be able to perform more accurate treatment and faster positioning of the patient. Furthermore, even with local anaesthesia, patients were found to have discomfort during the treatment. This might be a result of pulses being administered on local sensory pain receptors. This would also explain why, when returning to this location, this area would not be as uncomfortable as before. Treatment pulses given at the border of the FAD and the surrounding tissue could be more painful as well. More anaesthesia in the form of pre-treatment oral painkillers, topical crème or pectoral blocks should be evaluated in future studies.

The ideal patient for HIFU treatment would therefore be one who has a symptomatic palpable FAD located at least 5 mm from both the skin and the pectoralis major and with a size of about 10-30 mm. These inclusion criteria are similar to those used for VAM. Furthermore, patients should accept an approximated 50% decrease in volume over a period of six months as an alternative to surgical scarring.

## Conclusion

Circumferential HIFU ablation of FAD is feasible with a significant reduction in treatment time (mean 37.5%, SD 20.1) and a significant reduction in volume of the lesion at six months (mean 43.5%, SD 38.8%). Furthermore, a resolution of pain symptoms (6/8 patients) and minor short-term complications were found at six months follow-up. HIFU has a role in the treatment of FAD, which requires further economic and clinical evaluation.

## Acknowledgements

*HIFU-F Trialists' Collaborative:*

Prof. Michael Douek (King's College London, Guy's and St. Thomas' NHS Foundation Trust), michael.douek@kcl.ac.uk; Miss Mirjam Peek (King's College London, Guy's and St. Thomas' NHS Foundation Trust), mirjam.1.peek@kcl.ac.uk; Mr. Muneer Ahmed (King's College London), muneer.ahmed@kcl.ac.uk; Miss Julie Scudder (Guy's and St. Thomas' NHS Foundation Trust), julie.scudder@gstt.nhs.uk; Prof. Rose Baker (University of Salford), rose.baker@cantab.co.uk; Prof. Sarah Pinder (King's College London, Guy's and St. Thomas' NHS Foundation Trust), sarah.pinder@kcl.ac.uk; Mr. Ashutosh Kothari (Guy's and St. Thomas' NHS Foundation Trust), ashutosh.kothari@gstt.nhs.uk; Mr Hisham Hamed (Guy's and St. Thomas' NHS Foundation Trust), hisham.hamed@gstt.nhs.uk; Mr Tibor Kovacs (Guy's and St. Thomas' NHS Foundation Trust), tibor.kovacs@gstt.nhs.uk; Mrs Sarah MacWilliams (St. Bartholomew's Hospital); Mr. Bauke Anninga (King's College London, Guy's and St. Thomas' NHS Foundation Trust), bauke.anninga@kcl.ac.uk; Mr. Petros Charalampoudis (Guy's and St. Thomas' NHS Foundation Trust), petros.charalampoudis@gstt.nhs.uk.

We would like to thank Theraclion Ltd (Malakoff, France) for an unrestricted educational grant.

## Disclosure statement

The authors report no conflicts of interest.

## References

1. Cerrato F, Labow BI. Diagnosis and management of fibroadenomas in the adolescent breast. *Seminars in plastic surgery* 27(1), 23-25 (2013).
2. Sperber F, Blank A, Metser U, Flusser G, Klausner JM, Lev-Chelouche D. Diagnosis and treatment of breast fibroadenomas by ultrasound-guided vacuum-assisted biopsy. *Archives of surgery (Chicago, Ill. : 1960)* 138(7), 796-800 (2003).
3. Greenberg R, Skornick Y, Kaplan O. Management of breast fibroadenomas. *Journal of general internal medicine* 13(9), 640-645 (1998).
4. Wu F, Wang ZB, Cao YD *et al.* A randomised clinical trial of high-intensity focused ultrasound ablation for the treatment of patients with localised breast cancer. *British journal of cancer* 89(12), 2227-2233 (2003).
5. Schmitz AC, Gianfelice D, Daniel BL, Mali WP, Van Den Bosch MA. Image-guided focused ultrasound ablation of breast cancer: current status, challenges, and future directions. *European radiology* 18(7), 1431-1441 (2008).
6. Maloney E, Hwang JH. Emerging HIFU applications in cancer therapy. *International Journal of Hyperthermia* 31(3), 302-309 (2015).
7. Haar GT, Coussios C. High intensity focused ultrasound: physical principles and devices. *International journal of hyperthermia : the official journal of European Society for Hyperthermic Oncology, North American Hyperthermia Group* 23(2), 89-104 (2007).
8. Kim SH, Jung SE, Kim HL, Hahn ST, Park GS, Park WC. The potential role of dynamic MRI in assessing the effectiveness of high-intensity focused ultrasound ablation of breast cancer. *International journal of hyperthermia : the official journal of European Society for Hyperthermic Oncology, North American Hyperthermia Group* 26(6), 594-603 (2010).
9. Payne A, Todd N, Minalga E *et al.* In vivo evaluation of a breast-specific magnetic resonance guided focused ultrasound system in a goat udder model. *Medical physics* 40(7), 073302 (2013).
10. Peek MC, Ahmed M, Napoli A *et al.* Systematic review of high-intensity focused ultrasound ablation in the treatment of breast cancer. *The British journal of surgery* 102(8), 873-882; discussion 882 (2015).

11. Peek MC, Ahmed M, Douek M. High-intensity focused ultrasound for the treatment of fibroadenomata (HIFU-F) study. *Journal of therapeutic ultrasound* 3 6 (2015).
12. Krekel NM, Zonderhuis BM, Stockmann HB *et al.* A comparison of three methods for nonpalpable breast cancer excision. *European journal of surgical oncology : the journal of the European Society of Surgical Oncology and the British Association of Surgical Oncology* 37(2), 109-115 (2011).
13. Hynynen K, Pomeroy O, Smith DN *et al.* MR imaging-guided focused ultrasound surgery of fibroadenomas in the breast: a feasibility study. *Radiology* 219(1), 176-185 (2001).
14. Kovatcheva R, Guglielmina JN, Abehsera M, Boulanger L, Laurent N, Poncelet E. Ultrasound-guided high-intensity focused ultrasound treatment of breast fibroadenoma-a multicenter experience. *Journal of therapeutic ultrasound* 3(1), 1 (2015).
15. Cavallo Marincola B, Pediconi F, Anzidei M *et al.* High-intensity focused ultrasound in breast pathology: non-invasive treatment of benign and malignant lesions. *Expert review of medical devices* 12(2), 191-199 (2015).

JUST ACCEPTED

Table 1. Volume changes during six months follow-up in (a) HIFU treatment group and (b) control group.

Figure 1. HIFU treatment of breast FAD.

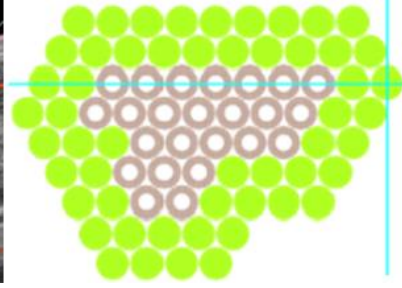
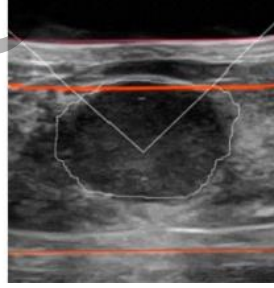
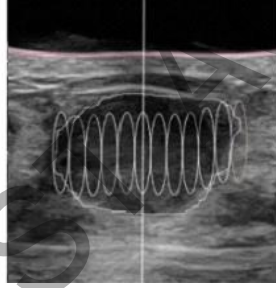
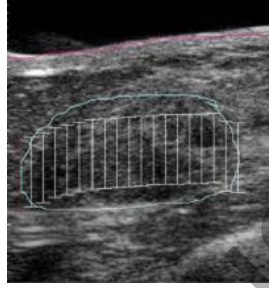
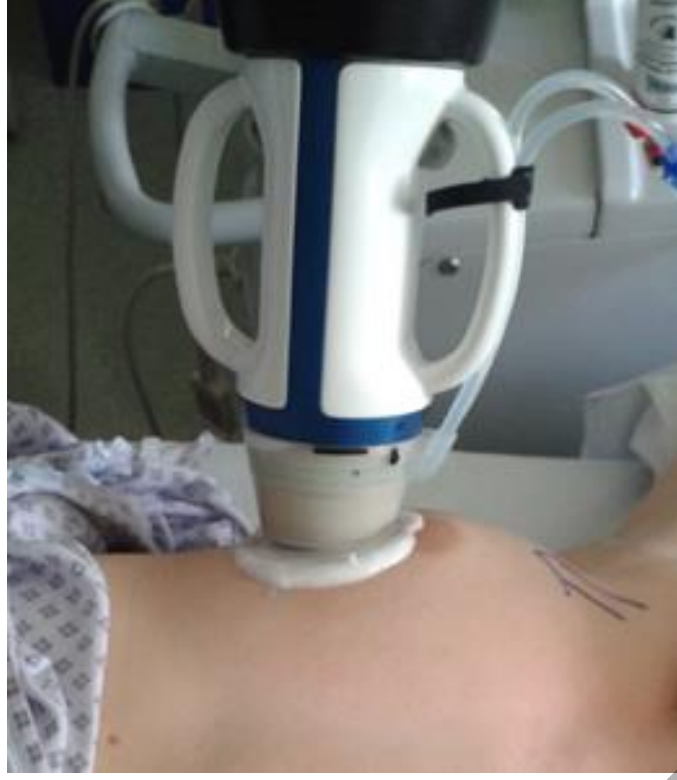Figure 2. Treatment planning and final treatment. From left to right: (1) Manual drawing of outline of FAD (blue) and skin (red) on touchscreen unit in radial and anti-radial position and number of treatment pulses (white) calculated by the Echopulse; (2) Radial view of target volume with treatment pulses (white cylinders) calculated by the Echopulse; (3) Application of treatment pulse in centre of FAD; (4) Final treatment of two circumferential rings, showing completed pulses (green) and deselected pulses (grey).

Figure 3. Box and Whisker plot for HIFU treatment and Control group (untreated) demonstrating pre-treatment volume (Blue) and age (Green) of the patients.

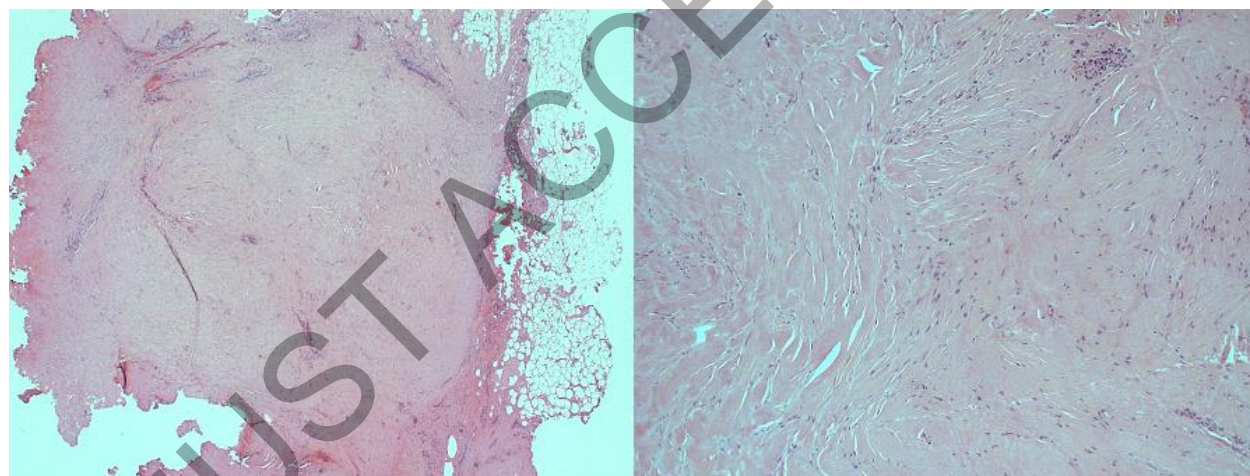
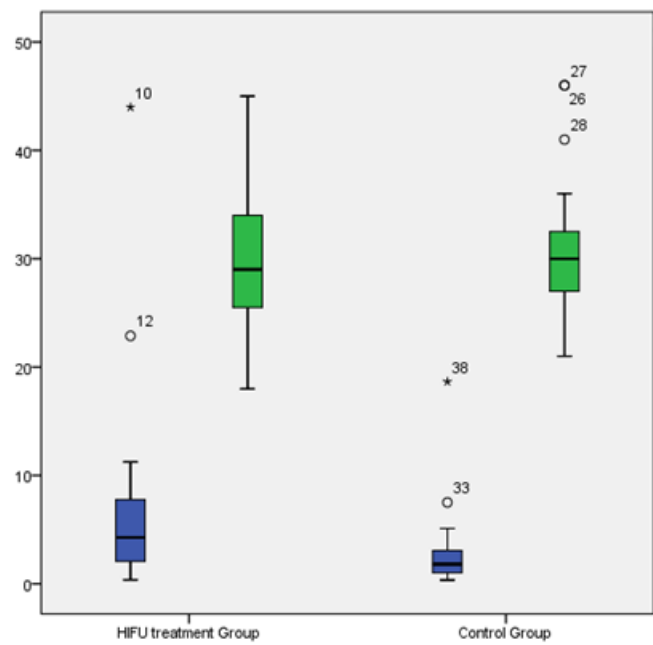
Figure 4. Histopathology of excised FAD treated with HIFU showing fibrous scarring on low (L) and high power (R).

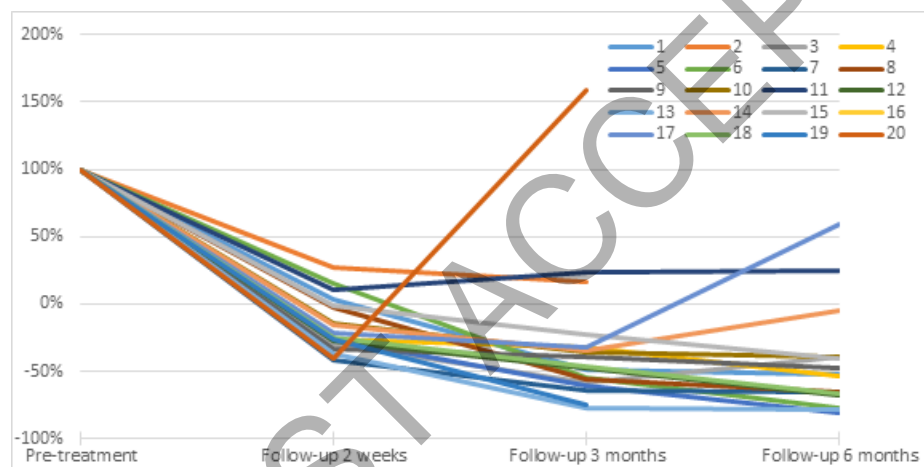
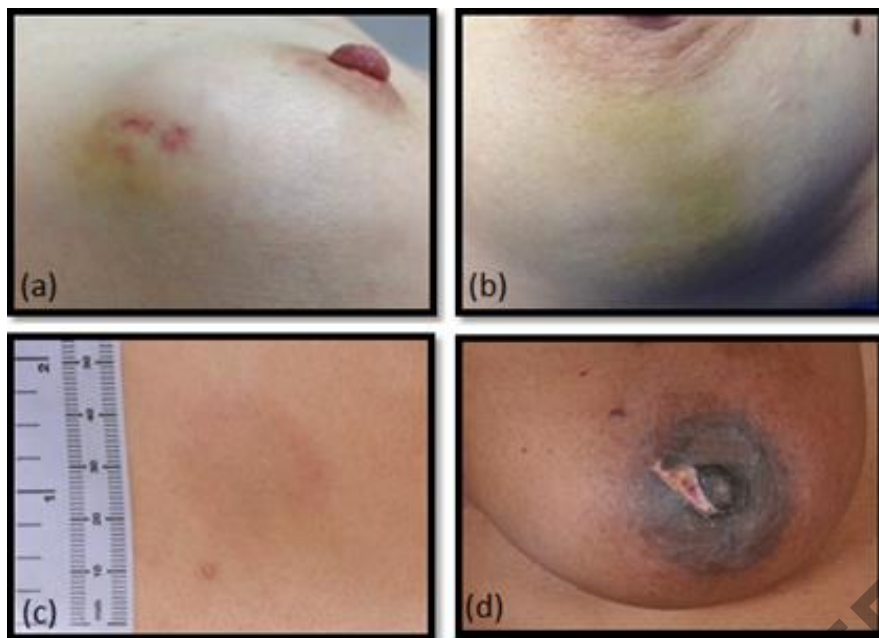Figure 5. Short term complications (a + b) two images of ecchymosis at two weeks, (c) hyperpigmentation at three months and (d) first-degree skin burn at two weeks post-treatment.

Figure 6. Change in volume per patient at two weeks, three and six months follow-up (in %).



ACCEPTED





**Table 1: Volume changes during six months follow-up in (a) HIFU treatment group and (b) control group.**

<b>(a)</b>	<b>Volume (mean±SD, range)</b>	<b>Change in volume (mean±SD, range)</b>	<b>Significance</b>
<b>Pre-treatment</b>	7.3±10.1cm <sup>3</sup> (0.4-44.0cm <sup>3</sup> )	-	-
<b>2 week follow-up</b>	6.1±8.4cm <sup>3</sup> (0.3-37.8cm <sup>3</sup> )	16.8±19.3% (↑27.1%-↓41.2%)	P=0.021*
<b>3 month follow-up</b>	5.0±6.5cm <sup>3</sup> (0.1-28.2cm <sup>3</sup> )	30.9±52.7% (↑158.6%-↓77.8%)	P=0.022*
<b>6 month follow-up</b>	4.6±6.4cm <sup>3</sup> (0.1-26.5cm <sup>3</sup> )	43.5±38.8% (↑58.9-↓80.5%)	P=0.016*

\* Significant difference in change of volume (p<0.05, paired t-test).

<b>(b)</b>	<b>Volume (mean±SD, range)</b>	<b>Change in volume (mean±SD, range)</b>	<b>Significance</b>
<b>Pre-treatment</b>	3.0±4.1 cm <sup>3</sup> (0.4-18.7 cm <sup>3</sup> )	-	-
<b>6 months follow-up</b>	2.6±2.3 cm <sup>3</sup> (0.2-9.7 cm <sup>3</sup> )	4.6±46.0% (↑66.3 -↓93.5%)*	P=0.434*

\* No significant difference in change of volume (p>0.05, paired t-test).

JUST ACCEPTED