



King's Research Portal

DOI:

[10.1111/bjd.14617](https://doi.org/10.1111/bjd.14617)

Document Version

Peer reviewed version

[Link to publication record in King's Research Portal](#)

Citation for published version (APA):

Boente, M. D. C., Nanda, A., Baselaga, P. A., Kelsell, DP., McGrath, J. A., & South, A. P. (Accepted/In press). Cardiomyopathy diagnosed in the eldest child harboring p.S24X mutation in JUP. *British Journal of Dermatology*. <https://doi.org/10.1111/bjd.14617>

Citing this paper

Please note that where the full-text provided on King's Research Portal is the Author Accepted Manuscript or Post-Print version this may differ from the final Published version. If citing, it is advised that you check and use the publisher's definitive version for pagination, volume/issue, and date of publication details. And where the final published version is provided on the Research Portal, if citing you are again advised to check the publisher's website for any subsequent corrections.

General rights

Copyright and moral rights for the publications made accessible in the Research Portal are retained by the authors and/or other copyright owners and it is a condition of accessing publications that users recognize and abide by the legal requirements associated with these rights.

- Users may download and print one copy of any publication from the Research Portal for the purpose of private study or research.
- You may not further distribute the material or use it for any profit-making activity or commercial gain
- You may freely distribute the URL identifying the publication in the Research Portal

Take down policy

If you believe that this document breaches copyright please contact librarypure@kcl.ac.uk providing details, and we will remove access to the work immediately and investigate your claim.

Received Date : 12-Nov-2015

Revised Date : 03-Feb-2016

Accepted Date : 08-Mar-2016

Article type : Letter to the Editor

Cardiomyopathy diagnosed in the eldest child harboring p.S24X mutation in *JUP*

M. del C. Boente¹, A. Nanda², P.A. Baselaga³, D.P. Kelsell⁴, J.A. McGrath⁵ and A.P. South^{6*}

¹Department of Dermatology, Hospital del Niño Jesús, Tucumán, Argentina; ²Asad Al-Hamad Dermatology Center, Kuwait; ³Department of Cardiology, Hospital del Niño Jesús, Tucumán, Tucumán, Argentina; ⁴Centre for Cell Biology and Cutaneous Research, Blizard Institute, Barts and The London School of Medicine and Dentistry, Queen Mary University of London, London, UK; ⁵St John's Institute of Dermatology, King's College London (Guy's Campus), London UK; and ⁶Dermatology and Cutaneous Biology, Thomas Jefferson University, Philadelphia.

Correspondence: Dr Andrew P South, Dermatology and Cutaneous Biology, Thomas Jefferson University, 406 Bluemle, 233 S 10th Street, Philadelphia, PA 19107. Tel: 215-439-4327

Andrew.south@Jefferson.edu

This article has been accepted for publication and undergone full peer review but has not been through the copyediting, typesetting, pagination and proofreading process, which may lead to differences between this version and the Version of Record. Please cite this article as doi: 10.1111/bjd.14617

This article is protected by copyright. All rights reserved.

CONFLICT OF INTEREST

The authors state no conflict of interest.

TO THE EDITOR,

In 2010 we reported two separate homozygous mutations in the 5' region of *JUP* which segregated with skin fragility and normal heart development in children from four separate families(1). At the time, only 3 mutations in this gene had been previously reported and each of the earlier identified mutations segregated with an inherited progressive disease of the heart, arrhythmogenic right ventricular dysplasia/cardiomyopathy (ARVD/C)(2-4). Five years on and as a result of close monitoring in each patient we report here that the eldest individual harboring homozygous mutations p.S24X has been diagnosed with left dilated cardiomyopathy (also considered ARVD/C) at age 17 years. All other patients examined report normal heart function.

The *JUP* gene encodes the protein plakoglobin (PG), also known as γ -catenin, which is abundant in cell cell junction complexes of adherens junctions and desmosomes. As well as this structural role PG can also influence cellular signaling where it's homology to and interaction with, β -catenin is crucial (for review see(5)). Mutations in *JUP* leading to Naxos disease(3), a so-called cardio-cutaneous syndrome affecting both skin and heart, identified PG as a protein important in these tissues, and confirmed earlier observations that mutation in genes encoding desmosomal components are a major cause of this type of cardiomyopathy(6). While originally termed ARVD/C, it has been shown that both right and left ventricles are often affected and as such, a

This article is protected by copyright. All rights reserved.

descriptive change to Arrhythmogenic Cardiomyopathy (AC) has been proposed to better reflect the pathology(7). Nearly half of all diagnosed AC patients harbor mutation in at least one of the genes encoding desmosomal proteins expressed in the heart: PG (*JUP*), plakophilin2 (*PKP2*), desmoplakin (*DSP*), desmocollin2 (*DSC2*), and desmoglein2 (*DSG2*). Thus, AC is classified as a disease of the desmosome. The majority of desmosomal gene mutations (48.1%) have been identified in *PKP2*(8) while *JUP* represents the least affected, contributing to 3.8% of all mutations(9) (see Table 1 and Fig. 1 for a summary of pathogenic *JUP* mutations).

Prompted by the observation that since our publication 10 further mutations have been reported in *JUP* and that all of these mutations, with the except of p.Q539X which resulted in early lethality due to severe skin involvement (10), are associated with AC(9), we re-visited the hospital records of patients harboring p.S24X and the splice site mutation, c.468G>A. Informed consent and ethical approval to study molecular and skin pathology in these children were obtained for the original study(1), while here we report clinical follow-up. These five patients are monitored regularly (every 2-3 years) and records showed that the eldest patient harboring p.S24X presented with slight dilation of the left ventricle with normal systolic function as determined by Doppler echocardiography at age 17 (Table 2). The cardiac involvement progressed to diagnosis of left dilated cardiomyopathy 20 months later, age 19, at which point the patient was prescribed angiotensin-converting enzyme inhibitors and β -blockers. Further monitoring will determine whether an implantable cardioverter-defibrillator (ICD) is necessary (11). Given the development of heart involvement we propose to reclassify patients harboring p.S24X mutation in *JUP* as a cardio-cutaneous syndrome.

Since our original report the two patients harboring c.468G>A mutation in *JUP* have two new siblings affected by the same disorder. All four individuals share phenotypic characteristics which include: diffuse hypotrichosis, diffuse palmoplantar keratoderma (observed to worsen with advancing age), recurrent paronychia followed by nail-dystrophy; skin fragility; eczematoid skin rashes affecting mainly the scalp, face & extremities; poor dentition; and recurrent skin infections. As previously reported the most notable difference with patients harboring p.S24X *JUP* mutation is the presence of hypotrichosis (1) (Figure 2). Given the structural and ultrastructural similarities we previously reported between patients harboring homozygous p.S24X and c.468G>A mutations(1), we predict that patients with c.468G>A will likely develop similar cardiac abnormalities. All patients will continue to be monitored on a regular basis.

REFERENCES

1. Cabral RM, Liu L, Hogan C, Dopping-Hepenstal PJ, Winik BC, Asial RA, et al. Homozygous mutations in the 5' region of the JUP gene result in cutaneous disease but normal heart development in children. *J Invest Dermatol.* 2010 Jun;130(6):1543-50.
2. Asimaki A, Syrris P, Wichter T, Matthias P, Saffitz JE, McKenna WJ. A novel dominant mutation in plakoglobin causes arrhythmogenic right ventricular cardiomyopathy. *Am J Hum Genet.* 2007 Nov;81(5):964-73.
3. McKoy G, Protonotarios N, Crosby A, Tsatsopoulou A, Anastasakis A, Coonar A, et al. Identification of a deletion in plakoglobin in arrhythmogenic right ventricular cardiomyopathy with palmoplantar keratoderma and woolly hair (Naxos disease). *Lancet.* 2000 Jun 17;355(9221):2119-24.
4. Ly S, Marcus FI, Xu T, Towbin JA. A woman with incidental findings of ventricular aneurysms and a desmosomal cardiomyopathy. *Heart Rhythm.* 2008 Oct;5(10):1455-7.

5. Swope D, Li J, Radice GL. Beyond cell adhesion: the role of armadillo proteins in the heart. *Cell Signal*. 2013 Jan;25(1):93-100.
6. Norgett EE, Hatsell SJ, Carvajal-Huerta L, Cabezas JC, Common J, Purkis PE, et al. Recessive mutation in desmoplakin disrupts desmoplakin-intermediate filament interactions and causes dilated cardiomyopathy, woolly hair and keratoderma. *Hum Mol Genet*. 2000 Nov 1;9(18):2761-6.
7. Basso C, Bauce B, Corrado D, Thiene G. Pathophysiology of arrhythmogenic cardiomyopathy. *Nat Rev Cardiol*. 2012 Apr;9(4):223-33.
8. Gerull B, Heuser A, Wichter T, Paul M, Basson CT, McDermott DA, et al. Mutations in the desmosomal protein plakophilin-2 are common in arrhythmogenic right ventricular cardiomyopathy. *Nat Genet*. 2004 Nov;36(11):1162-4.
9. Lazzarini E, Jongbloed JD, Pilichou K, Thiene G, Basso C, Bikker H, et al. The ARVD/C genetic variants database: 2014 update. *Hum Mutat*. 2015 Apr;36(4):403-10.
10. Pigors M, Kiritsi D, Krümpelmann S, Wagner N, He Y, Podda M, et al. Lack of plakoglobin leads to lethal congenital epidermolysis bullosa: a novel clinico-genetic entity. *Hum Mol Genet*. 2011 May 1;20(9):1811-9.
11. Tichnell C, James CA, Murray B, Tandri H, Sears SF, Calkins H. Cardiology patient page. Patient's guide to arrhythmogenic right ventricular dysplasia/cardiomyopathy: past to present. *Circulation*. 2014 Sep 2;130(10):e89-92.
12. den Haan AD, Tan BY, Zikusoka MN, Llado LI, Jain R, Daly A, et al. Comprehensive desmosome mutation analysis in north americans with arrhythmogenic right ventricular dysplasia/cardiomyopathy. *Circ Cardiovasc Genet*. 2009 Oct;2(5):428-35.
13. Xu T, Yang Z, Vatta M, Rampazzo A, Beffagna G, Pilichou K, et al. Compound and digenic heterozygosity contributes to arrhythmogenic right ventricular cardiomyopathy. *J Am Coll Cardiol*. 2010 Feb 9;55(6):587-97.

14. Christensen AH, Benn M, Bundgaard H, Tybjaerg-Hansen A, Haunso S, Svendsen JH. Wide spectrum of desmosomal mutations in Danish patients with arrhythmogenic right ventricular cardiomyopathy. *J Med Genet.* 2010 Nov;47(11):736-44.
15. Erken H, Yariz KO, Duman D, Kaya CT, Sayin T, Heper AO, et al. Cardiomyopathy with alopecia and palmoplantar keratoderma (CAPK) is caused by a JUP mutation. *Br J Dermatol.* 2011 Oct;165(4):917-21.
16. Bao J, Wang J, Yao Y, Wang Y, Fan X, Sun K, et al. Correlation of ventricular arrhythmias with genotype in arrhythmogenic right ventricular cardiomyopathy. *Circ Cardiovasc Genet.* 2013 Dec;6(6):552-6.
17. Exome Aggregation Consortium, Lek M, Karczewski K, Minikel E, Samocha K, Banks E, et al., Analysis of protein-coding genetic variation in 60,706 humans. bioRxiv doi: <http://dx.doi.org/10.1101/030338>

Table 1: Spectrum of *JUP* mutations, phenotype, mode of inheritance, and allele frequency identified in the Exome Aggregation Consortium (ExAC) database (accessed January 1st 2016). The ExAC database reports exome sequencing data from >60,000 unrelated individuals and indicates the prevalence of previously reported pathogenic *JUP* mutations. D = dominant, R = recessive. * - homozygous mutation, p.Q529X resulted in post-natal lethality due to massive transcutaneous fluid loss with apparent normal heart development (10). ** - p.V603L identified in one family with incomplete penetrance (14).

Mutation	Reference	Phenotype	Inheritance	Allele Count	Allele Frequency
p.T19I	12	Heart	D	13	0.0001139
p.S24X	1	Skin and Heart	R	-	-
p.S39_K40insS	2	Heart	D	-	-
p.I131del	13	Heart	D	-	-
c.468G>A	1	Skin (eldest 9 yrs)	R	-	-
p.V159L	4, 13	Heart	D	5	0.00004237
p.S225L	14	Heart	D	1	0.000008256
p.R265H	15	Skin and Heart	R	1	0.000008252
p.E301G	9	Skin and Heart	R	1	0.000008256
p.V407I	14	Heart	D	3	0.00002472
p.T427M	14, 16	Heart	D	6	0.0000494
p.Q529X	10	Skin (lethal)*	R	-	-
p.V603L	14	Heart	D**	76	0.0006604
p.G680fsX690	3	Skin and Heart	R	-	-
p.Y693C	16	Heart	D	3	0.00002563

Table 2: Cardiac investigations in patients with homozygous *JUP* mutations, p.S24X or c.468G>A.

Patient	Mutation	Age of cardiac investigation and result
1	p.S24X	16 years, normal
2	p.S24X	17 years, Left Dilated Cardiomyopathy
3	p.S24X	9 years, normal
4	c.468G>A	9 years, normal
5	c.468G>A	7 years, normal

FIGURE LEGEND

Fig. 1: 15 pathogenic variants have been identified in *JUP* encoding plakoglobin. Cartoon shows plakoglobin protein and the relative locations of pathogenic mutations identified to date. Blue text indicates mutations resulting in cardiomyopathy only while red text indicates skin involvement, with lighter red indicating no reported cardiomyopathy. Boxes represent Armadillo repeat domains.

Fig. 2: Patients harboring homozygous p.S24X *JUP* mutations do not exhibit hypotrichosis as observed in c.468G>A homozygous patients.

Fig. 1: 15 pathogenic variants have been identified in *JUP* encoding plakoglobin. Cartoon shows plakoglobin protein and the relative locations of pathogenic mutations identified to date. Blue text indicates mutations resulting in cardiomyopathy only while red text indicates skin involvement, with lighter red indicating no reported cardiomyopathy. Boxes represent Armadillo repeat domains.

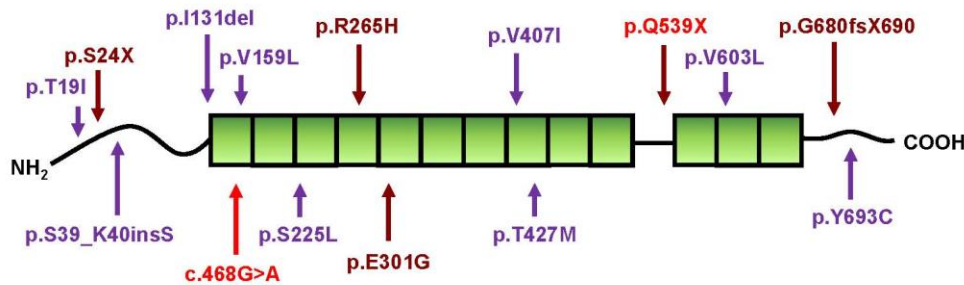


Fig. 2: Patients harboring homozygous p.S24X JUP mutations do not exhibit hypotrichosis as observed in c.468G>A homozygous patients.

