



<b>Title</b>	<b>Efficacy of fine needle aspiration cytology in the diagnosis of tuberculous cervical lymphadenopathy</b>
<b>Author(s)</b>	<b>Lau, SK; Wei, WU; Hsu, C; Engzell, UCG</b>
<b>Citation</b>	<b>Journal Of Laryngology And Otology, 1990, v. 104 n. 1, p. 24-27</b>
<b>Issued Date</b>	<b>1990</b>
<b>URL</b>	<b><a href="http://hdl.handle.net/10722/45182">http://hdl.handle.net/10722/45182</a></b>
<b>Rights</b>	<b>Creative Commons: Attribution 3.0 Hong Kong License</b>

## Efficacy of fine needle aspiration cytology in the diagnosis of tuberculous cervical lymphadenopathy

S. K. LAU,\* W. I. WEI,\* C. HSU,† U. C. G. ENGZELL\* (Hong Kong)

### Abstract

The results of a consecutive series of 1,349 fine needle aspiration (FNA) biopsies from the head and neck region of 1,193 patients has been reviewed in order to evaluate the efficacy of this method in the diagnosis of tuberculous lymphadenopathy (TBLN). Of the 108 patients whose fine needle aspiration cytology (FNAC) showed granulomatous changes, 68 had subsequent surgery and histological confirmation of the cytological appearance. Sixty-three had TBLN, thus the specificity of FNAC was 93 per cent in diagnosing tuberculous related granulomatous lymphadenopathy. One false positive FNAC was reported histologically to be metastatic mucoepidermal carcinoma.

Of the 1,193 patients, 90 patients had subsequently TBLN confirmed histologically. Of these 90 patients, FNA from 69 showed granulomatous changes or acid fast bacilli (AFB), thus the sensitivity of FNAC in detecting tuberculous lymphadenopathy was 77 per cent. Fifty-two cytological smears were stained for acid fast bacilli. Nineteen (37 per cent) contained AFB. It is evident from this review that FNAC is an efficient way to detect cervical tuberculous lymphadenopathy.

### Introduction

Tuberculous lymphadenopathy is the commonest form of extrapulmonary tuberculosis (Farer *et al.* 1979) in regions where mycobacterial infection is highly prevalent and presents commonly in lymph nodes draining the head and neck (Krishnaswami *et al.* 1972). In developed countries tuberculous lymphadenopathy (TBLN) is found mainly in the immigrant population (Campbell *et al.* 1977). The diagnosis of tuberculous cervical lymphadenopathy is usually made clinically and confirmed by histology. Fine needle aspiration cytology (FNAC) is increasingly used in the diagnosis of tuberculous lymphadenopathy and the cytological findings of fine needle aspiration from granulomatous lymphadenopathy such as sarcoidosis and tuberculosis have been described in detail (Lucas, 1955; Bloch, 1967; Patra *et al.*, 1983; Metre and Jayaram, 1987; Rajwanshi *et al.*, 1987; Frable and Frable, 1984). The sensitivity of this method ranged from 46 to 87 per cent (Patra *et al.*, 1983; Bailey *et al.*, 1985). The acid fast bacilli (AFB) detection rate ranged from 17 per cent to 50 per cent (Lucas 1955, Metre and Jayaram, 1987). However, the specificity of FNAC in diagnosing granulomatous lymphadenopathy and its usefulness in clinical situation to aid subsequent clinical management has not been evaluated. The aim of the present review was to study the sensitivity and specificity of FNAC in diagnosing tuberculous cervical lymphadenopathy.

### Materials and methods

In our study, 1,349 FNAC reports from head and neck masses, biopsied consecutively between January 1985 and January 1989 at Queen Mary Hospital, Hong Kong, were reviewed.

All FNA biopsies were performed by using a 23 gauge needle and a 10 ml disposable syringe mounted on a special grip handle (Cameco piston). The smears prepared from the aspirated material were fixed immediately in 95 per cent ethyl alcohol and stained with haematoxylin and eosin stain. In 52 cases where mycobacterial infection was suspected clinically or when the aspirate contained purulent material a separate smear was stained by Ziehl-Neelsen technique aiming to detect AFB. FNA specimens from these 52 patients were also submitted to culture for mycobacteria.

Granulomatous lymphadenopathy was diagnosed where the following cytological findings were present: (i) eosinophilic—stained caseous necrosis intermingled with inflammatory cells and necrotic cellular debris, (ii) sheets of epithelioid cells with elongated oval shaped nuclei, (iii) multinucleated giant cells associated with epithelioid cells (Fig. 1).

Only those patients who had subsequent surgery and histological confirmation of the head and neck masses were used in the calculation of specificity and sensitivity. A FNAC was true positive when both cytology and histology showed granulomatous changes. A FNAC was

\*Department of Surgery, University of Hong Kong, Queen Mary Hospital, Hong Kong.

†Department of Pathology, University of Hong Kong, Queen Mary Hospital, Hong Kong.

Accepted for publication: 5 October 1989.

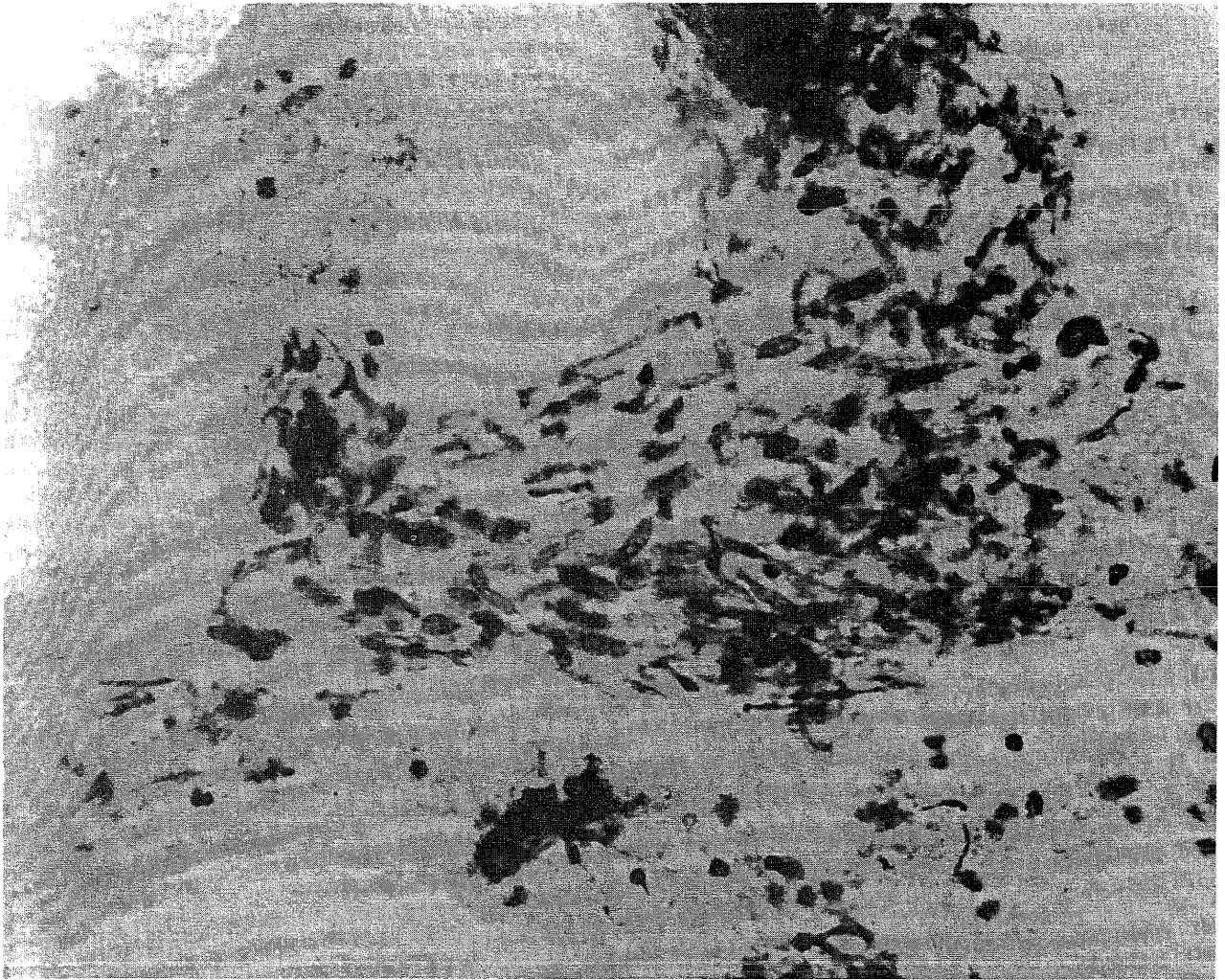


FIG. 1

Epithelioid cells in FNA from tuberculous lymphadenopathy (Haematoxylin-eosin stain  $\times 160$ ).

false positive when the histology did not show any granulomatous change. A FNAC was false negative when the cytology was negative and yet the histology showed granulomatous change. The specificity and sensitivity of FNAC in diagnosing granulomatous lymphadenopathy was derived from the following formulae:

$$\text{Specificity} = \frac{\text{Number of true positive}}{\text{Number of true positive} + \text{number of false positive.}}$$

$$\text{Sensitivity} = \frac{\text{Number of true positive}}{\text{Number of true positive} + \text{number of false negative.}}$$

## Results

The 1,349 FNAC were biopsied from 1,193 patients. Among them, 108 patients showed granulomatous changes in their FNAC. Only 68 of them had subsequent surgery with histological diagnosis. Tuberculous lymphadenopathy was confirmed in 63. In the remaining five patients histology showed three non-specific abscesses, one non-specific lymphadenitis and one metastatic mucoepidermoid carcinoma. Thus the specificity of FNAC in diagnosing granulomatous lymphadenopathy in our series was  $63/68 = (93 \text{ per cent})$ .

Among the 1,193 patients, histological findings of

tuberculous lymphadenitis was subsequently shown in 90 patients who had surgery after their FNA. Seventy-three patients had excision of their cervical lymph nodes and in one of them superficial parotidectomy was done because of clinical suspicion of a parotid gland tumour. Incision and drainage with biopsy of tuberculous abscess was performed in the other 17 cases. The male:female ratio of these 90 patients was 1:1.8 and their median age was 30 years ranging from 13 to 74. The clinical diagnoses made for the 90 patients before FNA are listed in Table I.

The details of the FNAC of the 90 cases of histologically confirmed tuberculous cervical lesions are listed in Table II. The FNA from 63 patients showed granulomatous changes (Table III). The FNA from 24 patients showed non-specific changes. The remaining three FNA were inadequate. Smears from 52 patients, stained by the Ziehl-Neelsen technique, showed AFB in 19 (37 per cent). Thirteen and six of the AFB positive smears were associated with granulomatous and non-specific inflammatory cytological findings respectively. Specimens of the FNAs from the same 52 patients were sent for mycobacterial culture and nine had *mycobacterium tuberculosis*. There was no atypical mycobacteria. The pre-operative cytological diagnosis based on FNAC are

TABLE I

CLINICAL DIAGNOSIS OF 90 CASES OF HISTOLOGICALLY CONFIRMED TUBERCULOUS CERVICAL LYMPHADENOPATHIES PRIOR TO FNAC

Clinical diagnosis	Number of patients
Tuberculous lymphadenopathy	42
Non-specific lymphadenopathy	33
Malignant lymphadenopathy	12
Benign parotid neoplasm	1
Branchial cyst	2
Total	90

listed in Table IV. Of the 90 patients who subsequently had a histologically confirmed tuberculous lesion, 63 showed granulomatous features in their FNAC (Table III) and thirteen of them showed AFB in their cytological smear. Thus in 50 patients, who had no evidence of AFB in the cytological smear, the best cytological diagnosis that can be made was granulomatous lymphadenopathy. In our part of the world this was very suggestive of tuberculous lymphadenopathy. In 19 patients, whose FNA revealed AFB, a firm cytological diagnosis of tuberculous lymphadenopathy could be made. Thus the overall sensitivity of FNAC in diagnosing tuberculous cervical lymphadenopathy was  $(50 + 19)/90 = 77$  per cent.

Eight out of 17 (45 per cent) tuberculous abscesses revealed AFB in the FNA whereas only 11 out of 73 patients (16 per cent) with tuberculous lymphadenopathy had AFB (Table III).

Culture of the specimen obtained by surgery showed mycobacterium tuberculosis in 72 (80 per cent) cases.

### Discussion

FNAC is a well-established diagnostic tool in the assessment of cervical masses and it is particularly sensitive and specific in the diagnosis of cervical metastatic lymph nodes (Engzell *et al.* 1971).

In our region where mycobacteria tuberculosis infection is common (Siu *et al.* 1983) and other granulomatous diseases are rare, the presence of granulomatous features in FNAC is highly suggestive of tuberculosis. The reports in the literature on the use of FNAC to diagnose tuberculous cervical lesions originate mainly from the developing countries where mycobacterial infections are prevalent (Patra *et al.*, 1983; Metre and Jayaram, 1987; Rajwanshi *et al.*, 1987). The sensitivity of FNAC in detecting tuberculous cervical lymphadenopathies and its detailed cytological findings have been described in detail previously (Lucas, 1955; Bailey *et al.*, 1985). The specificity of FNA cytological diagnosis of granulomatous lymphadenopathy however has not been reported.

TABLE II

FINDINGS OF FNA IN 90 CASES OF HISTOLOGICALLY CONFIRMED TUBERCULOUS CERVICAL LYMPHADENOPATHIES

	n	%
Epithelioid cells	61	68
Multinucleated giant cells	40	44
Caseous necrosis	28	31
Ziehl-Neelsen stain for AFB	19*	37
Necrotic cells	32	36

\* Only 52 FNA were stained for AFB.

TABLE III

COMPARISON BETWEEN CYTOLOGICAL AND HISTOLOGICAL DIAGNOSIS OF 90 CASES OF TUBERCULOUS CERVICAL LESIONS.

( ) = number of smears which were AFB positive stained by Ziehl-Neelsen techniques

Cytology	Histology	Tuberculous lymphadenopathy	Tuberculous abscess
Epithelioid or multinucleated giant cells		55 (8)	8 (5)
Non-specific inflammatory cells		15 (3)	9 (3)
Inadequate specimen		3	0
Total		73	17

In the present study, the specificity (true positive rate) is 93 per cent. One of the false positive results occurred in a patient with metastatic mucoepidermoid carcinoma in submandibular lymph nodes. It is generally acknowledged that a granulomatous-type smear may be obtained from malignant lymphoma, or metastatic carcinoma, especially those of squamous cell origin (Zajicek, 1974). If the clinical and cytological findings are uncertain or incompatible repeated aspiration biopsy or alternatively surgery are usually advisable.

It is generally agreed that anti-tuberculous chemotherapy is the definitive modality treatment of tuberculous lymph nodes. The conventional diagnostic measure of excisional biopsy is potentially hazardous as it may spread the disease and give rise to sinus formation. For early cases of tuberculous lymphadenopathy there is no evidence that excisional biopsy plus chemotherapy is superior to chemotherapy alone (Campbell *et al.* 1977). Since findings of epithelioid cells, necrotic cells, multinucleated giant cells and/or AFB is specific for tuberculous cervical lymphadenopathy, FNA biopsy reduces the necessity to perform excisional biopsy in many cases thus saving the patients a surgical operation which may cause complications and which is considerably more expensive and may delay the start of chemotherapy. For the above reasons, FNAC is increasingly used as the sole method to reach a pathological diagnosis of tuberculous lymphadenopathy (Campbell *et al.*, 1977; Alessi *et al.*, 1988; Metre *et al.*, 1987). In developing countries where mycobacterial infection is prevalent and resources for medical care are limited FNAC provides a simple, efficient and cost effective alternative to diagnose tuberculous lymphadenopathy.

Our results show that the FNAs from tuberculous abscesses gave a higher AFB detection rate (47 per cent) than those from tuberculous lymph nodes (15 per cent). This finding agrees with other studies. (Bailey *et al.*, 1985; Rajwanshi *et al.*, 1987; Metre *et al.*, 1987). When

TABLE IV

CYTOLOGICAL DIAGNOSIS IN 90 CASES OF HISTOLOGICALLY CONFIRMED TUBERCULOUS CERVICAL LYMPHADENOPATHIES (n = 90)

	n	%
Granulomatous lymphadenopathy	50	55
Tuberculous lymphadenopathy	19	22
Non-specific lymphadenopathy	18	20
Inadequate	3	3
Total	90	100

multiplication of bacilli in a lymph node is not under control the lymph node becomes necrotic and turns into an abscess. Therefore it is expected that the FNA from a tuberculous abscess contains more AFBs than early tuberculous lymph nodes. Six of the AFB-positive smears were found in cases where cytology showed non-specific inflammatory cells and the diagnosis of tuberculosis would have been missed if the smears had not been examined for AFB. Therefore, it should be stressed that when the FNA appears purulent or when tuberculosis is clinically suspected, the specimen should be stained for AFB and cultured for mycobacteria. This will improve the diagnostic capability of the FNA.

Although the AFB detection rate has been reported by various authors (Lucas *et al.*, 1955; Metre *et al.*, 1987), positive mycobacterial culture rate from FNA has only been mentioned by a few authors to be around 80 per cent (Bailey *et al.*, 1985; Alessi *et al.*, 1988). Our positive mycobacterial culture rate is 17 per cent (9/52). We attribute this low positive culture rate to the lymph nodes status. We have fewer tuberculous abscesses compared with other series. This low positive culture rate in our hands should not be considered to be the disadvantage of FNA in diagnosing TBLN as the findings of granulomatous changes or positive AFB smear allow diagnosis in 77 per cent.

### Conclusion

FNA is a sensitive and specific method of diagnosing tuberculous cervical lymphadenopathies. Granulomatous reaction seen in FNAC from malignant lymphadenopathies is a source of diagnostic error. When the FNA contains purulent material or when a tuberculous lesion is suspected, FNA should be tested for AFB and cultured for mycobacteria. FNAC is recommended as an essential part of the diagnostic investigation of cervical lymphadenopathies.

### References

- Alessi, D. P. and Dudley, J. P. (1988). Atypical mycobacteria—induced cervical adenitis. Treatment by needle aspiration. *Archives of Otolaryngology—Head and Neck Surgery*, **114**: 664–666.
- Bailey, T. M., Akhtar, M. and Ashraf, Ali, M. (1985). Fine needle aspiration biopsy in the diagnosis of tuberculosis. *Acta Cytologica*, **29**(5): 732–736.
- Bloch, M. (1967). Comparative study of lymph node cytology by puncture and histopathology. *Acta Cytologica*, **2**: 139–144.
- Campbell, I. A. and Dyson, A. J. (1977). Lymph node tuberculosis: A comparison of various methods of treatment. *Tubercle*, **58**: 171–179.
- Engzell, U., Jakobsson, P. A., Sigurdson, A. and Zajicek, J. (1971). Aspiration biopsy of metastatic carcinoma in lymph nodes of the neck. A review of 1,101 consecutive cases. *Acta Oto-Laryngologica*, **72**: 138–147.
- Farer, L. S., Lowell, A.M. and Meador, M. P. (1979). Extrapulmonary tuberculosis in the United States. *American Journal of Epidemiology*, **109**: 205–217.
- Frale, M. A. S. and Frable, W. J. (1984). Fine needle aspiration biopsy: Efficacy in the diagnosis of head and neck sarcoidosis. *Laryngoscope*, **94**: 1281–1283.
- Krishnaswami, H., Koshi, G., Kulkarni, G. and Job, C. K. (1972). Tuberculous lymphadenitis in South India—A histological and bacteriological study. *Tubercle*, **53**: 215–220.
- Lucas, P. F. (1955). Lymph node smears in the diagnosis of lymphadenopathy: A review. *Blood*, **10**: 1030–1054.
- Metre, M. S. and Jayaram, G. (1987). Acid fast bacilli in aspiration smear from tuberculous lymph nodes: An analysis of 255 cases. *Acta Cytologica*, **31**: 17–19.
- Patra, A. K., Nanda, B.K., Mohapatra, B. K. and Panda, A. K. (1983). Diagnosis of lymphadenopathy by fine needle aspiration cytology. *Indian Journal of Pathology and Microbiology*, **26**: 273–278.
- Rajwanshi, A., Bhambhani, S., Das, D. K. (1987). Fine needle aspiration cytology diagnosis of tuberculosis. *Diagnostic cytopathology*, **3**(1): 13–16.
- Siu, K. F., Ng, A. and Wong, J. (1983). Tuberculous lymphadenopathy: A review of results of surgical treatment. *Australian and New Zealand Journal of Surgery*, **53**: 253–257.
- Zajicek, J. (1974). In: Monograph in Clinical Cytology. Vol. 4. Aspiration biopsy cytology, Part I. Cytology of supradiaphragmatic organs. (George L. Wied, eds) Chapter 4, pp.90–125. S. Karger, A. G., Basel.

Address for correspondence:

Dr Sai-Kit Lau,  
Department of Surgery,  
University of Hong Kong,  
Queen Mary Hospital,  
Hong Kong.